V. I. BODYAZHINA

Textbook of OBSTETRICS

В. И. Бодяжина

АКУШЕРСТВО

Издательство «Медицина»
Москва

Textbook of OBSTETRICS

V. I. Bodyazhina

Translated from the Russian
by Alexander Rosinkin

KAMGAR PRAKASHAN
B-4838, STREET NO. 112, SANT NAGAR,
BURARI DELHI-110084 (INDIA)
Website : www.kamgarprakashan.com

Mir Publishers
Moscow

First published 1983

Revised from the 1980 Russian edition

TO THE READER

Mir Publishers would be grateful for your comments on the content, translation and design of this book. We would also be pleased to receive any other suggestions you may wish to make.

Our address is:
Mir Publishers
2 Pervy Rizhsky Pereulok
I-110, GSP, Moscow, 129820
USSR

На английском языке

© Издательство «Медицина», 1980

© English translation, Mir Publishers, 1983

Printed in the Union of Soviet Socialist Republics

Contents

Preface 7

Chapter 1. Anatomy and Physiology of the Female Genitalia 9

Chapter 2. Female Pelvis 37

Chapter 3. Fertilization. Intrauterine Development of Foetus and Foetal Membranes 54

Chapter 4. Physiological Changes of Pregnancy 75

Chapter 5. Diagnosis of Pregnancy. Examination of the Pregnant 84

Chapter 6. Nutrition and Hygiene of Pregnancy 109

Chapter 7. Asepsis and Antisepsis. Medicopreventive Obstetrics 115

Chapter 8. Labour and Delivery 122

Chapter 9. Conduct of Labour 141

Chapter 10. Pain Relief in Labour 166

Chapter 11. Normal Puerperium 173 Excerise

Chapter 12. Care of the Neonate 186

Chapter 13. Breech Presentation 206

Chapter 14. Multiple Pregnancy 219

Chapter 15. Toxaemia of Pregnancy 227

Chapter 16. Diseases and Abnormal Development of Intrauterine Foetus, Foetal Membranes and Placenta 239

Chapter 17. Pregnancy and Labour of Patients with Medical Diseases 253

Chapter 18. Abortion and Premature Labour 265

Chapter 19. Ectopic Pregnancy 275

Chapter 20. Placenta Praevia. Premature Separation of Normally Implanted Placenta 279

Chapter 21. Dystocia and Abnormalities in Soft Tissues of Birth Canal 288

Chapter 22. Transverse and Oblique Presentations. Prolapse of Extremities and Umbilical Cord 294

Chapter 23. Abnormal Labour 301

Chapter 24. Contracted Pelvis 313

Chapter 25. Bleeding During Placental Stage of Labour and in Early Hours of Puerperium 329

Chapter 26. Injuries in Labour and Delivery 339

Chapter 27. Diseases of the Puerperium 352

Chapter 28. Obstetric Operations 364

Subject Index 396

PREFACE

Obstetrics is the science that deals with physiological and pathological processes occurring in women during pregnancy, labour, and the puerperium. Embryology and the postnatal growth of the newborn are the subjects that are closely and entirely related to the subject matter of obstetrics.

The main principles underlying the Soviet obstetric aid are prophylaxis, accessibility and utilization of recent scientific and technical developments in practical obstetric aid, which is free of charge in this country.

There is one feature that makes obstetrics differ from all other branches of the medical science, viz., unlike a therapist or a surgeon, the obstetrician-gynaecologist (or a midwife) gives medical aid not only to diseased patients but also to women in whom physiological processes, such as pregnancy, labour and the puerperium, occur. When other physicians treat their patients, they take care of the health of a patient alone, while an obstetrician-gynaecologist is responsible for the health of two persons at a time: the mother and her future baby.

Obstetric aid is given to many millions of women. The necessity may arise suddenly, and urgent obstetric aid is given much more frequently than any other medical assistance. Prophylaxis of complications of pregnancy, labour and the puerperium is the basis of obstetric aid, and its realization is only possible with clever organization of work of physicians and obstetric workers.

Obstetrics is one of the most ancient branches of medicine and it still continues developing; methods of prophylaxis, diagnosis and treatment are being constantly improved to keep pace with scientific developments of our times.

Textbooks of obstetrics describe scientifically grounded and practically proved methods of giving medicoprophylactic aid in normal and complicated pregnancy, labour and the puerperium.

The twenty-eight chapters of this book give fundamentals of clinical anatomy and physiology of the female genitalia, the architecture of the female pelvis, fertilization of the ovum and growth of the foetus, anatomical and physiological changes of pregnancy, methods of examination of the pregnant and the parturient, hygiene and nutrition during pregnancy, and principles of asepsis and antisepsis. Causes of labour are discussed along with the description of the mechanism of labour and its management, rules for breast-feeding and care of the neonate. The book also describes the fun-

damentals of pathological and operative obstetrics, including gestoses of pregnancy, haemorrhage during pregnancy and labour, dystocia and abnormal labour, malpresentations, abnormalities of the foetus and its membranes, contracted pelvis, obstetric injuries, premature termination of pregnancy, puerperal diseases and other complications of pregnancy and labour.

This particular textbook is intended for future obstetricians and midwives who will work independently or under the guidance of a physician.

Chapter One

ANATOMY AND PHYSIOLOGY OF THE FEMALE GENITALIA

The knowledge of the structure and function of the female reproductive system is a prime requisite in the scientific approach to management of obstetric and gynaecological patients. It is therefore common to begin the course in obstetrics with the study of the anatomy and physiology of the female genitalia.

The reproductive organs of the woman are usually divided into the external and internal genitalia. The external female genitalia are mainly the organs of pleasurable sensations, while the internal organs perform the reproductive function.

External Genitalia

The female external genitalia are mons pubis, labia majora, labia minora, clitoris, vestibule of the vagina, and Bartholin's glands (Fig. 1). The hymen is a natural border separating the external and internal genitalia.

Mons pubis (mons veneris) is a fatty triangular cushion that rests anteriorly* upon the symphysis pubis.

The upper boundary of the mons pubis is the transverse fold of the skin; the inguinal folds limit it on the sides. Posteriorly the mons pubis is continuous with the labia majora. The pubic region is grown over with hair. The female escutcheon differs from the male one in that its upper boundary is horizontal while the pubisure of a man extends along the white line, sometimes up to the navel. Hair is absent from the pubic region in children; in aged persons the pubic hair becomes thin.

The growth of pubic hair depends on the function of the ovaries and the adrenal cortex. Some women have the male escutcheon, or their hair is scarce which would usually be associated with underdeveloped genitalia and ovarian hypofunction.

Labia majora (labia pudendae majora) are longitudinal folds of skin that form the lateral boundaries of the vulva. Fatty tissue underlying the skin of the labia majora is permeated by blood vessels, nerves, and fibrous tissue. Anteriorly the labia majora end in the skin of the mons pubis, while posteriorly they gradually become narrow and meet in the midline to form the posterior commissure. The skin of the labia majora is grown with hair; it also contains sweat and sebaceous glands. The inner surface of the labia majora is lined by thin pink skin resembling mucosa in appearance.

The cleft between the labia majora is known as rima pudendi (or pudendal cleft).

Bartholin's glands are located in the

* The terms 'posteriorly', 'anteriorly', etc. are applied to a woman as if she is in the upright position (whatever her position might actually be).

masses of tissues forming the labia majora. These are small (the size of a bean) round alveolar-tubular formations. The alveoli are lined by epithelium that secretes into 1.5-2 cm long ducts found in the posterior regions of the labia majora and opening into the cleft formed by the labia minora and the hymen (or its remnants). Bartholin's glands can be palpated at the base of the labia majora, close to the posterior commissure.

The secretion of Bartholin's glands is a whitish fluid reacting alkaline and having specific odour. It is released during sexual excitement and is intended to moisten the vestibule of the vagina and to thin the seminal fluid, which promotes the mobility of the spermatozoa.

The space between the anus and the posterior commissure is known as *perineum**. It consists of muscles and fascia covered with skin on the outside. A 3-4 cm long line, known as the raphe of perineum, is seen on the skin. It extends from the posterior commissure to the anus. The perineum narrows in the upward direction where the rectum and the vagina approach each other. Thus, the muscles and the fascia of the perineum form a wedge narrowing upwards.

Labia minora (labia pudendae minora). These are another pair of cutaneous folds found medially and along the labia majora. As a rule, the labia minora can only be seen when the labia majora are separated, but sometimes their size is considerable and they extend beyond the labia majora. Anteriorly each labium terminates in two folds: the lateral ones arch over the clitoris to form the female prepuce (praeputium clitoridis) while the other (medial) folds fuse to form the frenulum of the clitoris.

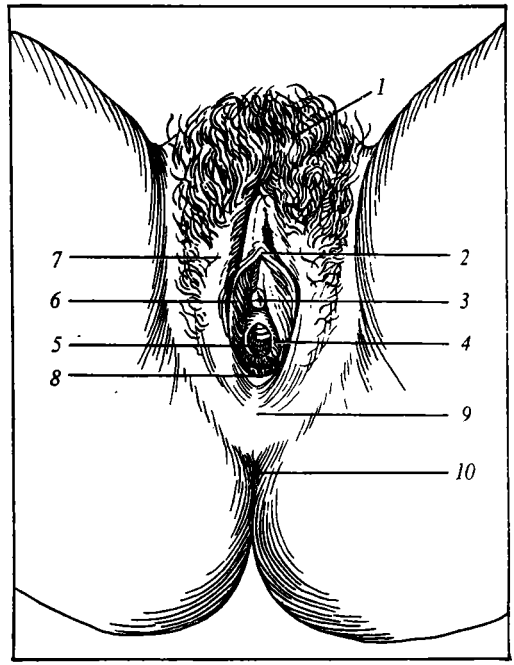

Fig. 1. External female genitalia:
1 — mons pubis, *2* — clitoris, *3* — meatus, *4* — hymen, *5* — vestibule, *6* — labia minora, *7* — labia majora, *8* — posterior fourchette, *9* — perineum, *10* — anus

Posteriorly the labia minora diminish and fuse with the tissues of the labia majora (at the level of the middle third). The labia minora are permeated by an abundant plexus of blood vessels and nerve endings to make them a sensitive sex organ.

Clitoris. This is a small cone-shaped structure (analogous to the penis in the male) consisting of two cavernous bodies in which the blood circulates. The clitoris is a small protuberance situated at the anterior angle of the rima pudendi between the fused

* To be more exact, this is the obstetric or anterior perineum, while the space between the anus and the coccyx is referred to as the posterior perineum.

folds of the labia minora. It comprises the glans, the cavernous body and the crura attached to the pubic and ischial bones. The clitoris is rich in blood vessels and nerve endings and is the locus of sexual feelings. When excited, it increases in size and becomes rigid (erect) due to the intensified inflow of the arterial blood and retarded outflow of the venous blood.

Vestibule. This is the space of the pudendal cleft bounded anteriorly by the clitoris, posteriorly by the posterior commissure, and laterally by the labia minora. The upper boundary of the vestibule is the hymen (or its remnants). Opening into the vestibule are the urethra and the ducts of Bartholin's glands. The vestibule has numerous small cluster-like glands and crypts (or lacunae) lined with stratified squamous epithelium.

Urethra. The urethral orifice is found 2-3 cm posteriorly to the clitoris. Its slit is oblong or, less frequently, crescentic. The length of the urethra in women is 3-4 cm, while its lumen varies and can easily be distended to 1 cm and over. The urethra is almost straight, only slightly bending upwards; it is adjacent to the anterior wall of the vagina along its entire length. This part of the vaginal wall slightly protrudes in the form of a ridge.

The inner surface of the urethra is lined with mucosa that forms longitudinal folds. The urethral mucosa is lined by columnar epithelium, except its lower part which is lined with stratified squamos epithelium. Glands and crypts open into the mucosa of the urethra. The muscular layer consists of longitudinal and circular smooth muscles.

The circular muscles at the inner end of the urethra (at the bladder) form a ring-like band (sphincter) which only relaxes to release urine. The outer end of the urethra is provided with another sphincter formed by striated muscles of the urogenital diaphragm (the muscle-fascia layer of the inguinal arch). On either side of the urethral opening are the orifices of a set of 1-2 cm long ramifying ducts (Skene's ducts). Their outer ends open into the urethral mucosa at the urethral orifice. The fluid secreted by the periurethral glands moistens the orifice of the urethra.

Hymen. This is a membranous structure closing the vaginal orifice. On both its sides the hymen is covered with stratified squamous epithelium, and its connective tissue has muscular elements, elastic fibres, blood vessels and nerves. In the virginal state the hymen has an aperture which varies in size and location. Accordingly the hymen can be annular (circular), lunar (crescentic), denticular (serrate), infundibuliform, septate, etc. Sometimes the hymen has two or many small

Fig. 2. Changes in the hymen caused by sexual life and childbirth:
1 — hymenal tags, *2* — carunculae myrtiformes

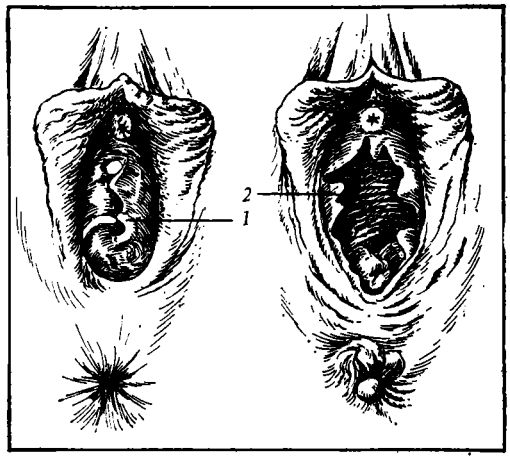

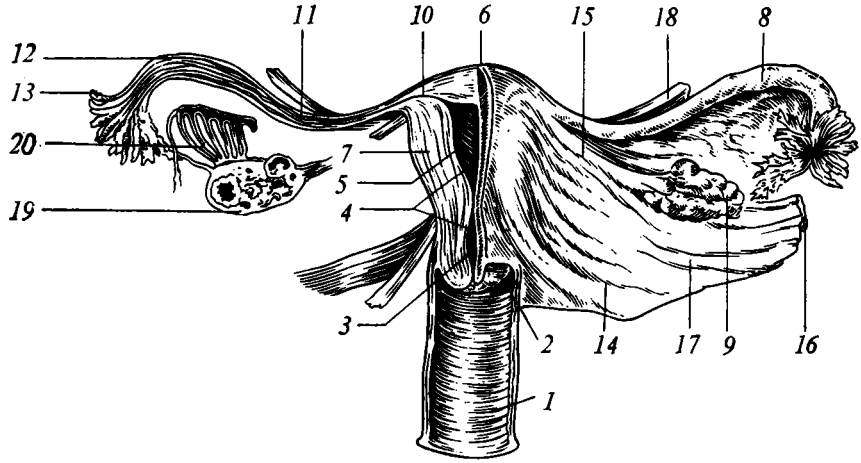

Fig. 3. Internal genitalia (frontal section):
1 — vagina, *2* — vaginal portion of the cervix, *3* — endocervical canal, *4* — isthmus, *5* —cavity of the uterus, *6* — fundus of the uterus, *7* — uterine wall, 8 — uterine (fallopian) tubes, *9* — ovary, *10* — interstitial portion of the tube, *11* — isthmic portion of the tube, *12* — ampulla, *13* — ovarian fimbriae, *14* — uterosacral ligament, *15* — proper ligament of the ovary, *16* — infundibulopelvic ligament, *17* — broad ligament, *18* — round ligament, *19* — an ovary with follicles and corpus luteum, *20* — parovarium

perforations (cribriform or fenestrated hymen) and in rare cases the hymen completely closes the vaginal orifice (imperforate hymen). The absence of opening in the hymen can be either congenital or secondary (due to vulvitis in childhood).

During the first sexual intercourse the hymen ruptures with bleeding. Its remnants form nodular tags (Fig.2). After childbirth only separate remnants of the hymen in the form of carunculae myrtiformes can be found.

The shape of the hymen and the changes that occur in it during the sex life and childbirth are very important for legal medical examination.

In rare cases the hymen is so elastic that it fails to rupture during the sexual intercourse. In exceptional cases the highly extensible hymen can be found intact even after childbirth.

Internal Genitalia

The internal genitalia are the vagina, the uterus, the fallopian tubes, and the ovaries (Figs. 3 and 4).

Vagina (vagina s. colpos). This is a musculomembranous canal situated in the middle of the small pelvis. It is directed backward and upward, extending from the hymen to the point of its attachment to the cervix uteri.

The length and width of the vagina vary widely. The average length of the anterior wall is 7-8 cm, while the posterior wall is 1.5-2 cm longer. The width of the vagina depends on its distensibility and is, on an average, 2-3 cm, the lower portion being narrower than the upper one. The anterior and posterior walls of the vagina collapse thus giving the vagina an H configuration. The upper part of the

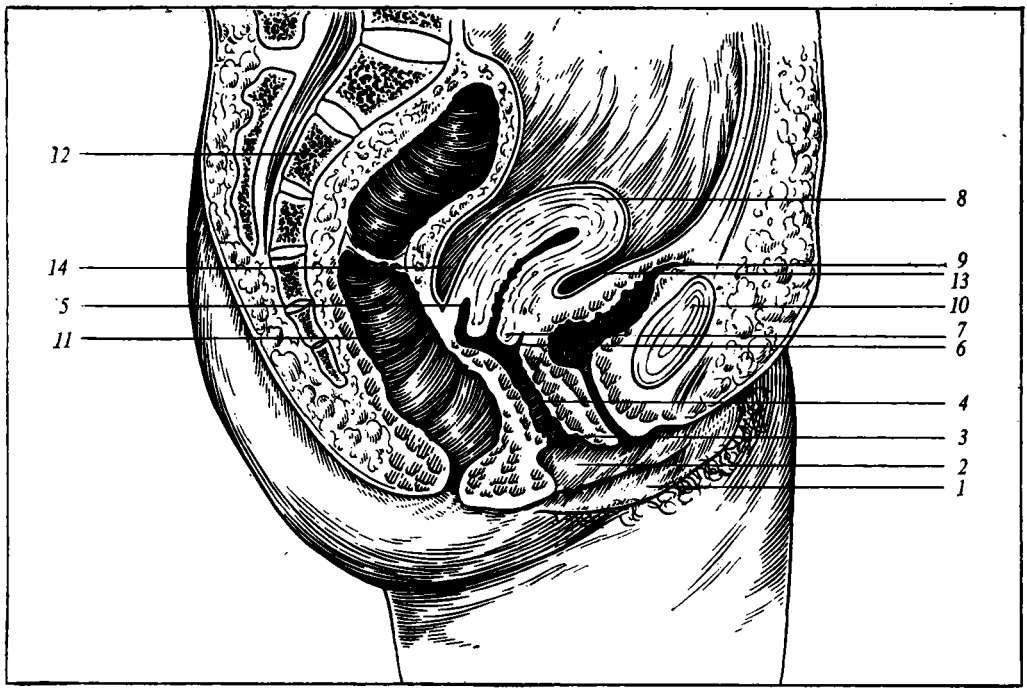

Fig. 4. Pelvic organs (sagittal section):
1 — labium majus, *2* — labium minus, *3* — vestibule of the vagina, *4* — vagina, *5* — posterior fornix, *6* — anterior fornix, *7* — cervix, *8* — uterus body, *9* — bladder, *10* — symphysis, *11* — rectum, 12 — sacrum, *13* —vesicouterine excavation, *14* — Douglas' cul-de-sac

vagina surrounding the cervix ends in a vault into which the vaginal portion of the cervix projects. The cervix divides this portion of the vagina into the anterior, posterior, and two lateral fornices. The posterior fornix is deeper than the anterior one. It serves to accumulate the semen deposited during coitus, from where the seminal fluid gets into the external os of the cervix and further into the uterus. The anterior wall of the vagina is related to the fundus of the bladder in its upper portion and to the urethra in the lower part. The upper portion of the vagina is related anteriorly to the ureters (at the point where they open into the bladder).

The posterior wall of the vagina and the rectum are in apposition to each other being separated in their lower portion by the perineal tissues. On its sides the vagina is separated from the pelvis by muscular bundles and the connective tissue. The vaginal wall is composed of three layers: the mucosa, the muscular coat, and the surrounding connective tissue. The connective tissue is permeated by a network of blood and lymph vessels and nerves.

The *muscular coat* underlying the connective tissue consists of two layers, the outer layer of longitudinal and the inner layer of circular muscles. The inner layer is stronger than the

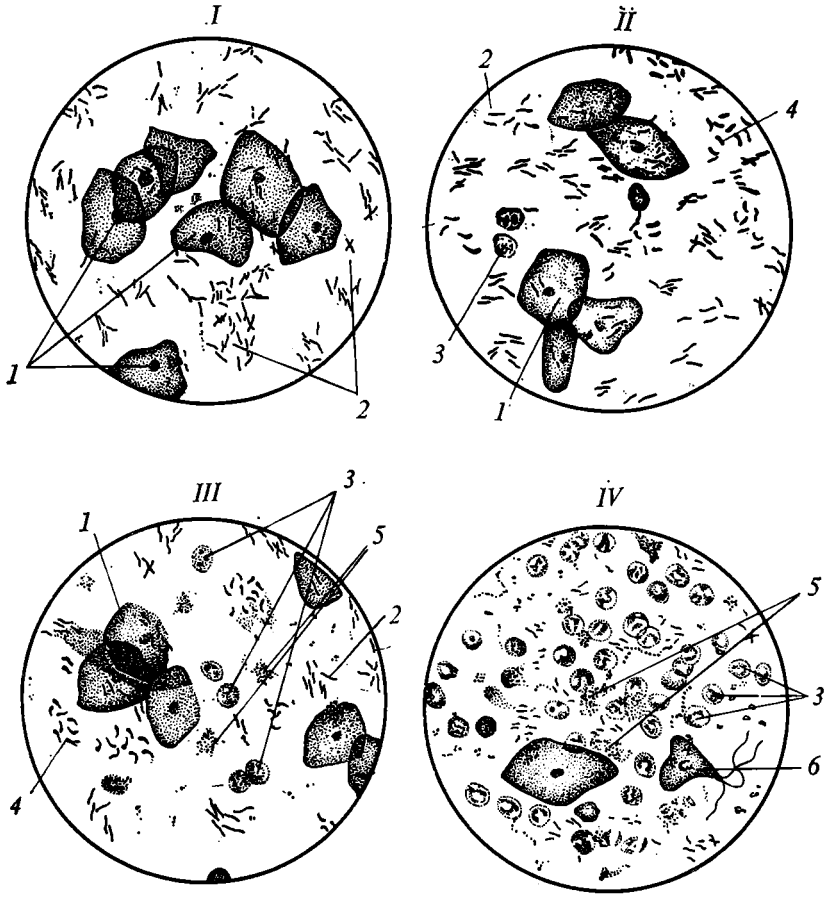

Fig. 5. Degrees of cleanliness of the vaginal secretion.
The first degree: epithelial cells (1) and vaginal bacilli (*2*) are found. The second degree: epithelial cells (*1*), vaginal bacilli (*2*), separate leucocytes (*3*) and comma variabile (*4*) can be seen. The third degree: vaginal bacilli (*2*) are scarce, leucocytes (3), comma variabile (*4*) and cocci (5) are in ample quantity. The fourth degree: vaginal bacilli are absent, leucocytes (*3*) and cocci (*5*) are in ample quantity. Trichomonas vaginalis (*6*) are found

outer one; it contains a large number of elastic fibres. Attached to the muscular layer is the *mucosa of the vagina*. Its colour is pale pink. Along the anterior and the posterior walls the mucosa forms two longitudinal ridges from which numerous transverse ridges (columnae rugarum) extend. The transverse ridges account for the high distensibility of the vagina during labour. After childbirth, in multiparous women in particular, the ridges are gradually levelled and the vaginal mucosa becomes smooth. The transverse ridges are especially pronounced in a virginal vagina. In aged women the

ridges are smoothed down even in nulliparous women due to the gradual atrophy of the reproductive organs. The vaginal mucosa is lined with stratified squamous epithelium. This is a depot of glycogen, which is produced by the follicular hormone excreted by the ovaries.

The vaginal mucosa has no glands. The liquid portion of the vaginal secretion is formed by sweating out of the blood and lymph. The liquid is mixed with the rejected cells of the vaginal epithelium, microorganisms, and leucocytes. Normal vaginal discharge is whitish, with a specific odour. Its quantity is scant (but sufficient to moisten the mucosa). It gives no discomfort to a healthy woman. The vaginal secretion of an adult woman is acidic because of lactic acid present in it. The latter is formed from glycogen of the epithelial cells by the metabolism of the vaginal (Döderlein's) bacilli which are commonly found in the vagina of a healthy woman.

Lactic acid is harmless to the vaginal bacilli or the mucosa but it kills pathogenic microorganisms that enter the vagina from the environment. The vagina of a healthy woman is thus 'self-cleansed'. The ovarian function is inhibited in aged women and in patients with gynaecological and grave diseases. As a result, the amount of glycogen in the mucosa decreases to reduce the quantity of lactic acid produced, and the vaginal discharge can thus react alkaline. This provides conditions for the development of pathological bacteria that may get into the vagina and displace normal microflora (bacilli).

The character of the microbial flora in the vagina can vary and accordingly four degrees of vaginal cleanliness are distinguished (Fig. 5):

1. The vaginal secretion contains vaginal bacilli and epithelial cells alone; the reaction is acid.
2. The number of the vaginal bacilli diminishes; single leucocytes and anaerobic bacteria (comma variabile), and also many epithelial cells are found in the vaginal discharge. The reaction is acid.

The first and the second degrees are characteristic of healthy women.

3. The vaginal bacilli are few in number while other bacteria (cocci in particular) prevail. The discharge is weak alkaline. The quantity of leucocytes is great.
4. Vaginal bacilli are absent. Pathogenic microbes (cocci, comma variabile, trichomonas, etc.) and leucocytes are in ample quantity. The reaction is alkaline.

The third and fourth degrees are associated with pathological processes.

Uterus. This is a smooth-muscle pear-shaped hollow organ, flattened slightly anteroposteriorly.

The uterus is divided into the following parts: (1) the body, (2) the isthmus, and (3) the cervix (Fig. 3).

The *body of the uterus* (corpus uteri) is its upper massive portion. The dome-shaped portion of the body superior to the insertion of the fallopian tubes is the fundus.

The *isthmus* is the uterus portion, measuring about 1 cm, situated between the uterine body and the cervix. The isthmus is passed through by a canal whose upper end opens into the uterine cavity and the lower one into the endocervical canal. The mucosa of the isthmus is similar to that of the uterine body and the wall structure is like that of the cervix. The isthmus and the lower part of the uterine body form the lower uterine segment during pregnancy and labour. The upper bound-

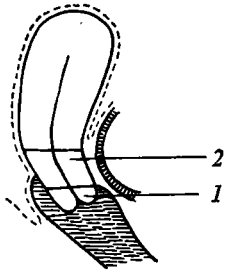

Fig. 6. The uterus cervix:
1 — vaginal portion, *2* — supravaginal portion

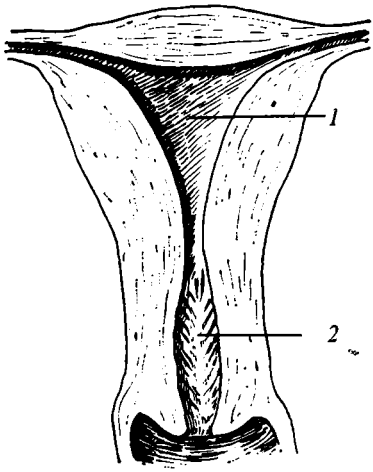

Fig. 7. The longitudinal view of the uterus:
1 — cavity of the uterus, *2* — endocervical canal

ary of this segment is the point of attachment of the peritoneum to the anterior wall of the uterus, while its lower border is the histological internal os of the cervix.

Cervix. This is a narrow lower end of the uterus projecting into the upper vagina. The cervix is composed of (a) the infravaginal portion (portio infravaginalis) projecting into the vaginal fornix, and (b) supravaginal portion (portio supravaginalis) situated

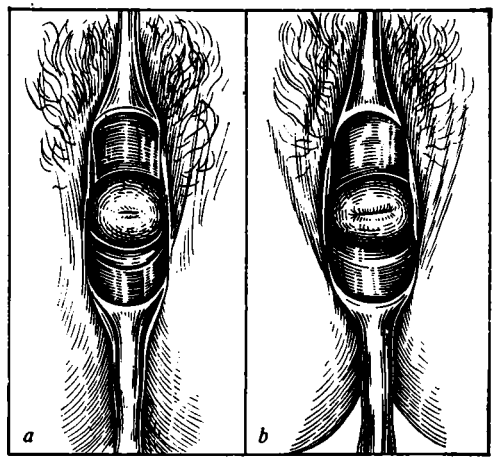

Fig. 8. External cervical os:
1 — nulliparous cervix, *2* — parous cervix

above the attachment of the vagina to the cervix (Fig. 6). The uterine cervix has a configuration of a straight cylinder or it may slightly narrow toward the external os. The cervix of a child or an adult woman with underdeveloped genitalia is cone-shaped.

The cavity of the cervix is a narrow canal (endocervical canal) lined by mucosa. The canal has a configuration of a spindle, narrowing on both ends (Fig. 7). The upper end of the cervical canal (internal cervical os) opens into the isthmus while the external os opens into the central part of the vaginal cervix. In the nulliparous woman the external os is a small oval or round opening (Fig. 8, *a*), whereas after childbirth it assumes the shape of a transverse slit (Fig. 8, *b*). The changes in the appearance of the external os are due to lateral tearing during labour.

The overall length of the uterus is 8 cm. Two thirds of its length is the corpus and one third the cervix. The width of the uterus at its bottom is 4-5.5 cm, and the walls are 1-2 cm thick.

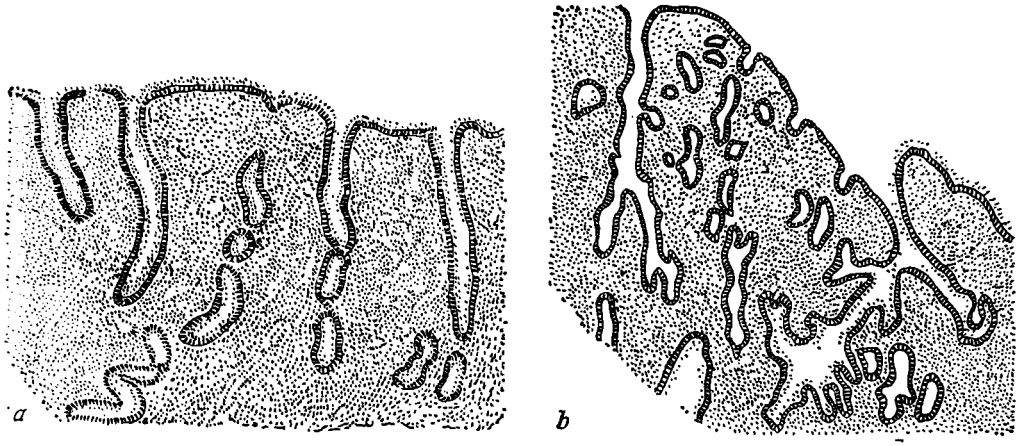

Fig. 9. Glands of mucosa of the uterus body and cervix:
a — glands in the mucosa of the uterus body, *b* — glands in the mucosa of the cervix

A uterus of a healthy (not pregnant) woman weighs from 50 to 100 g.

The cavity of the uterus appears as an inverted triangle with the cervix at the apex and the bottom at the base. The lower angle coincides with the internal os of the cervical canal, whereas the upper two angles correspond to the uterine ends of the fallopian tubes (Fig. 7). The uterus walls are composed of three layers: (a) mucosa, (b) muscle coat (myometrium), and (c) serous (peritoneal) coat (perimetrium).

The *uterine mucosa*, known as endometrium, is lined by a single layer of ciliated columnar epithelium whose cilia vibrate to direct fluids toward the external os of the cervical canal. Underlying the epithelium is the connective tissue containing vessels, nerves and many glands.

The glands of the uterine body (lined by columnar epithelium) produce watery secretion that moistens the mucosa. The glands are tubular, sometimes with bifurcated ends (Fig. 9, *a*).

The glands of the cervix are lined by columnar epithelium as well. They have a configuration of deer horns (Fig. 9, *b*) and secrete a thick clear mucus which fills the endocervical canal to close it as if with a stopper. The uterine mucosa is smooth, whereas the mucosa of the cervical canal forms ridges which resemble a leaf of a palm (plicae palmatae). The uterine mucosa (endometrium) is composed of the two layers separated from each other with-

Fig. 10. Musculature of the uterus:
1 — outer layer of tube muscles, *2* — inner layer of tube muscles, *3* — round ligament, *4* — proper ligament of the ovary, *5* and *6* — uterosacral ligaments

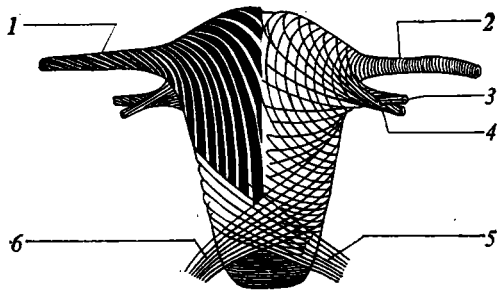

out distinct demarcation. The superficial layer of the uterus undergoes rhythmical changes associated with the menstrual function. Hence the name 'functional'. The underlying layer, adjacent to the muscular coat, does not undergo cyclic changes and is called basal.

The *muscular coat* of the uterus (myometrium) is the thickest. This is a bundle of interlaced smooth muscles with the connective tissue between them. The muscle coat is rich in blood vessels and is composed of three main layers: (1) the outer (infraperitoneal) layer with a longitudinal arrangement of the fibres; (2) the middle layer, consisting of circular and oblique fibres; and (3) the inner (submucous) layer of longitudinal fibres (Fig. 10). The circular muscles are better developed in the body of the uterus and the longitudinal in the cervix. The outer muscles of the uterus are continuous with the muscular elements of the tubes and ligaments. The muscle coat is thinner in the uterus cervix and the isthmus, while the connective tissue here is thicker than in the uterine body. The uterus cervix has many elastic fibres.

The outer *serous coat of the uterus* is perimetrium. The peritoneum extends from the anterior abdominal wall onto the bladder and the anterior surface of the uterus and the tubes. A vesico-uterine excavation, covered with the peritoneum, is formed between the bladder and the uterus (excavatio vesico-uterina). The anterior surface of the uterus is covered with the peritoneum only above the isthmus (loose connective tissue being found in lower regions, between the cervix and the bladder). The peritoneum descends from the uterine bottom along its posterior surface to cover the supravaginal part of the cervix and the posterior vault of the vagina; then it passes onto the anterior part of the rectum. A deep fold of peritoneum forms a pouch between the posterior part of the uterus and the rectum which is known as the cul-de-sac or Douglas' cul-de-sac (excavatio recto-uterina).

The uterus is located in the middle of the true pelvis, equidistant from the symphysis and the sacrum, and from either of the pelvic walls. Its body is situated in the wider part of the pelvis, while the vaginal portion of the cervix and the external os are found at the level of the ischial spine. The uterus is bent forward (anteversio uteri), its bottom is directed toward the symphysis, the cervix is directed backward, and the external os of the endocervical canal is related to the posterior fornix of the vagina. The uterus body and the cervix form an obtuse angle, open anteriorly (anteflexio uteri). The uterus can change its position physiologically. When the bladder is filled the uterus is moved posteriorly, and when the rectum is full, the uterus is displaced forward. A pregnant uterus extends upwards. As soon as the cause of such displacement is removed, the uterus restores its normal position in the centre of the true pelvis.

The uterus performs the child-bearing function. During the entire reproductive period of the female life, complicated repetitive changes occur in the endometrium which prepare the uterus for pregnancy. A pregnant uterus is the abode of the foetus: an impregnated ovum is implanted and the foetus is nourished here. As soon as the foetus grows to the state when it is able of extrauterine life, the uterus expels it (parturition).

Fallopian tubes (tubae uterinae, sal-

pinges). The uterine tubes are also known as oviducts.

The tubes originate from the upper angles of the uterus, course along the upper edge of the broad ligament in the direction of the lateral walls of the pelvis to terminate in the funnel-shaped lateral extremity of the tube, the infundibulum (Fig. 3). The tubes are 10-12 cm long. Their lumen varies: it is narrow at the uterus angle but widens to the free end. The tube opens into the cavity of the uterus. At this point its diameter is 0.5-1 mm, but at the infundibulum the lumen widens to 6-8 mm. The infundibulum opens into the peritoneal cavity (abdominal ostium). The free end of the infundibulum has a fimbriated appearance. The fimbriae are believed to aid in conducting the egg from the ruptured follicle into the lumen of the tube.

There are the following subdivisions of the tubes: (1) the uterine or interstitial portion (pars interstitialis) which passes inside the muscular wall of the uterus; (2) the isthmus (pars isthmica), the middle portion of the tube; and (3) the ampulla (pars ampullaris), the wider part of the tube which ends in the infundibulum (Fig. 3).

The tube walls are composed of three layers: the mucous coat, the muscle coat, and the serous (peritoneal) coat.

The mucosal coat forms longitudinal folds on the inner surface of the tube. The number of folds and their size increase toward the ampulla. The mucosal lining is composed of a single layer of columnar ciliated epithelium, whose cilia move in the direction of the uterus.

The muscle coat of the tube is composed of three layers of smooth muscles. The outer layer has longitudinal fibres, the middle layer circular, and the inner (submucous) longitudinal again.

The serous coat of the tube is the uppermost portion of the broad ligament. The peritoneum covers the upper part and the sides of the tube, while its lower portion adjoins the connective tissue permeated by vessels and nerves.

In early childhood the tubes are narrow and sinuous, but with advancing years they straighten out and become wider. Sometimes the tubes remain narrow and sinuous till maturity (infantile tubes) which interferes with the migration of a fertilized egg to the uterus and may become the cause of ectopic (tubal) pregnancy. The egg is usually fertilized (fused with the spermatozoid) in the ampulla and its further transport to the uterus is mainly effected by tubal peristalsis. When the longitudinal muscles are contracted the tube shortens, and when contract the circular muscles, the tube narrows. Successive contractions of the longitudinal and circular muscles are responsible for the peristaltic motility and hence for the transport of the egg toward the uterus. Fibrillation of the epithelial cilia is of secondary importance in the egg transport. Its transport is also facilitated by the presence of longitudinal folds in the mucous coat along which egg slips toward the uterus as if by rail.

The contractility of the tubes depends on the phase of the menstrual cycle (A. N. Osyakina-Rozhdestvenskaya). The tone of the tube increases during maturation of the follicle in the ovary. During the development of the corpus luteum the tone and excitability of the tubes decrease, peristalsis becomes rhythmic and this promotes the migration of the egg.

Ovaries. This is a paired female sex-

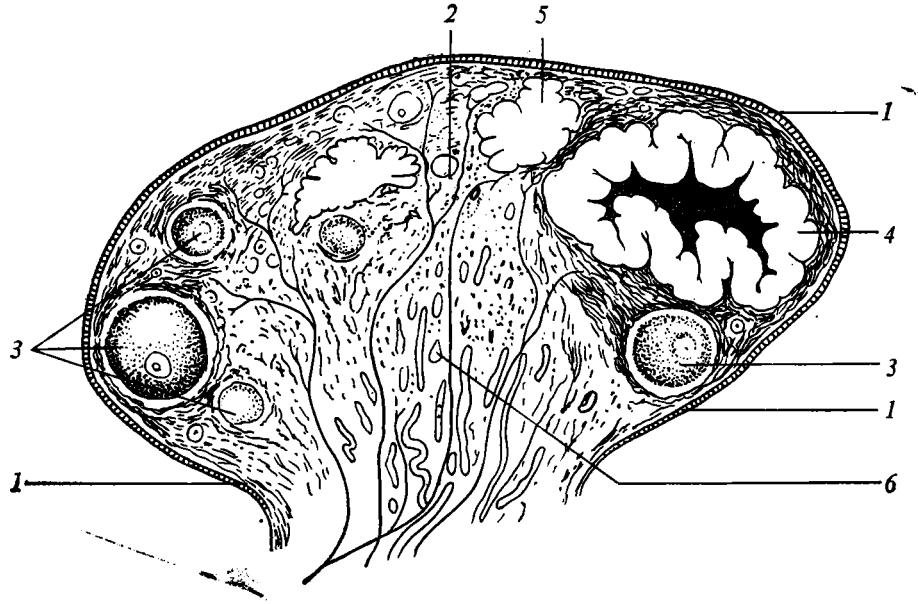

Fig. 11. Section through an ovary:
1 — columnar epithelium, *2* — cortex, 3 — ovarian follicles in various stages of development, *4* — corpus luteum, *5* — corpus luteum after regression, *6* — medulla

ual gland. An ovary is a 3.5-4 cm long, 2-2.5 cm wide and 1-1.5 cm thick, flat oval body weighing 6-8 g. In aged persons the ovaries become dense, diminish in size, and cicatricial tissue develops in them.

The ovary is inserted by its one end into the posterior leaf of the broad ligament while the rest of it remains uncovered by the peritoneum and is suspended in the pelvic cavity. It is supported by (1) the broad uterine ligament, (2) the proper ligament of the ovary, and (3) the infundibulopelvic ligament. The vessels and nerves enter the ovary at the point where it is inserted into the posterior leaf of the broad ligament (hilus of the ovaries).

The ovary is composed of an outer zone lined by epithelium (1), the proteinous layer, the cortex (2), and the inner portion, called the medulla (6) (Fig. 11).

During the intrauterine development and in early childhood the ovarian epithelium is involved in the formation of primordial follicles, but with age it tends to become inactive.

The proteinous layer underlies the epithelium. It consists of connective tissue, whose fibres are parallel to the surface of the ovary.

The cortex of the ovary is adjacent to the proteinous layer. The connective tissue of the cortex contains numerous primordial follicles and also follicles in various stages of their development, corpora lutea, and their remnants.

The medulla consists of connective-tissue stroma through which the blood vessels and nerves pass.

The ovaries perform very important functions. During the entire reproduc-

tive life of the woman, at regular intervals, they provide conditions for maturation of the eggs. The ovaries also produce sex hormones stimulating the reproductive system and the entire body of the woman. The ovarian hormones are responsible for the development of features specific to the female body. These include the specific profile of the female body, metabolism, development of the breasts, hair, etc. During sexual maturation the ovarian hormones stimulate the development of the female genitalia (tubes, uterus, vagina, external genitalia). During the reproductive years, these hormones are involved in the cyclic processes that prepare the female body for pregnancy.

Fig. 12. Ligaments:
a — top view, *b* — caudal view; *1* — uterus, *2* — fallopian tube, *3* — ovary, *4* — proper ligament of the ovary, *5* — infundibulopelvic ligament, *6* — round ligament, *7* — uterosacral ligament, *8* — broad ligament, *9* — rectum

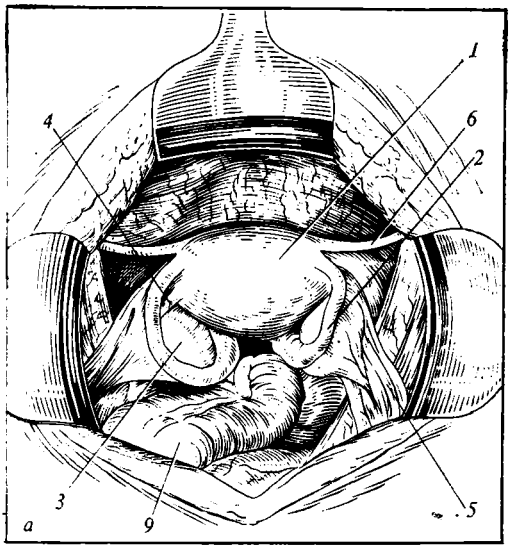

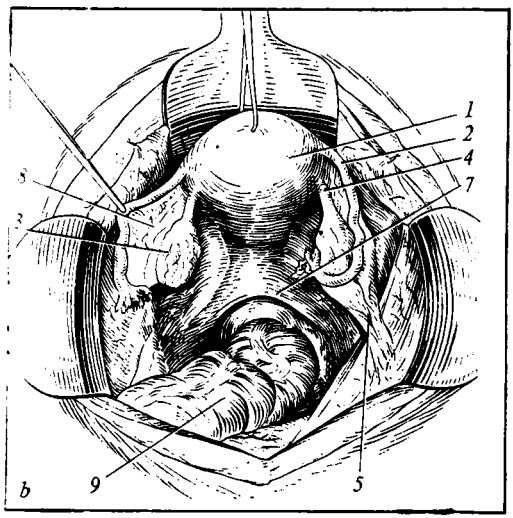

Ligaments

The normal position of the uterus, the tubes, and the ovaries in the pelvic cavity mainly depends on the ligaments and the muscles of the pelvic floor. These form the suspensory, immobilizing, and supporting structures.

The *suspending structure* of the internal genitalia comprises the following:

1. *Round ligaments* (lig. rotundum). These are composed of smooth muscles and the connective tissue, forming 10-12 cm long cords. Round ligaments extend from the angles of the uterus (somewhat anteriorly and below the insertion of the fallopian tubes). Each runs in the anterior leaf of the broad ligament to the inguinal canal, through which it passes to terminate in the connective tissue of the mons pubis and the labia majora. The round ligaments pull the uterus bottom anteriorly (anteroflexion). During pregnancy the round ligaments thicken and elongate (Fig. 12, *a*).

2. *Broad ligaments* (lig. latum). These are twin-leaves of the peritoneum running from the uterus sides to the lateral walls of the pelvis. The superior portion of the broad ligament contains the fallopian tubes, while the posterior leaves suspend the ovary. The vessels and nerves pass in the connective tissue between the leaves (Fig. 12. *b*).

3. *Uterosacral ligaments* (lig. sacrouterinum). These ligaments originate from the posterior surface of the uterus at the point where the isthmus transforms into the cervix, and pass backward to embrace the rectum on both sides and are attached to the anterior surface of the sacrum (Fig. 12, *b*). These ligaments tend to keep the cervix posteriorly. During labour the round and uterosacral ligaments oppose the displacement of the uterus.

4. *Proper ligaments of the ovaries* (lig. ovarii proprium). These originate at the uterus bottom, posteriorly and below the insertion of the fallopian tubes, and extend to the ovaries (Fig. 12, *a* and *b*).

The *immobilizing system* of the uterus is composed of connective-tissue bands incorporating smooth muscles; they extend from the inferior portion of the uterus (a) anteriorly to the bladder and further to the symphysis, (b) to the lateral walls of the pelvis (cardinal ligaments), and (c) posteriorly to form a connective-tissue framework of the uterosacral ligaments.

The *supporting system* comprises the muscles and the fasciae of the pelvic floor (see page 45).

The floor of the pelvis is very important in maintaining the internal genitalia in the normal position. When the intra-abdominal pressure increases, as in weight lifting, coughing, etc., the uterus cervix is given a stationary support by the pelvic floor to prevent the lowering of the internal organs.

Connective Tissue of True Pelvis

Underlying the peritoneum is the connective tissue of the pelvis which contacts the internal genitalia at their various parts. The connective tissue fills the space between the pelvic organs where they are not covered with the peritoneum, above the fascia of the pelvis. The connective tissue of the pelvis is, in general, loose, but there are parts composed of firm fibrous tissue; they, in particular, immobilize the internal genitalia.

Pelvic connective tissues are subdivided as follows.

Parametrium is loose connective tissue occupying the space between the leaves of the broad ligaments, extending from the lateral walls of the uterus to the pelvic walls.

Paravesicular tissue fills in the space around the bladder; it mainly lies anteriorly and posteriorly to the bladder.

Paravaginal tissue surrounds the vagina, predominantly between the lateral walls of the vagina and the pelvic walls.

Pararectal connective tissue is situated around the rectum.

There is no explicit demarcation between the various connective tissues and they are interconnected with one another through numerous elements.

The connective tissue of the pelvis is very important for the normal body function. Loose connective tissue allows physiological movements and adequate functioning of the internal genitalia, the bladder, and the rectum so

that they can change their volume (filling and emptying of the bladder and the rectum, variations of the size of the uterus associated with pregnancy, delivery, etc.). Firm connective tissue immobilizes and suspends the internal organs and keeps the uterus and the other genital organs in normal position. The connective tissue of the pelvis also supports the ureters, blood and lymph vessels, lymph nodes, nerve trunks and plexus.

Blood Vessels

The blood supply to the external genitalia is mainly derived through the pudendal artery.

The *pudendal artery* (a. pudenda) originates from the internal iliac artery, then courses downward, leaves the pelvis, and gives off its major branches to the external genitalia, the perineum, the vagina and the rectum.

The external spermatic artery passes from the inguinal canal together with the round ligament and supplies blood to the labia majora and the mons pubis.

The internal genitalia are mainly supplied with blood by the uterine and the ovarian arteries (Fig. 13).

The *uterine artery* (a. uterina) is a paired vessel branching from the hypogastric artery; it passes to the uterus in the periuterine connective tissue in the basement of the broad ligaments, passes above the ureter, and enters the lateral wall of the uterus at the level of the internal os. At this point the uterine artery ramifies to give off a rather large artery supplying blood to the cervix and the upper vagina (ramus cervico-vaginalis).

The main trunk of the uterine artery (ramus ascendens) passes up the lateral wall of the uterus giving off many branches supplying blood to the uterine wall; it reaches the fundus of the uterus, where it gives a branch leading to the tube. The terminal branches of the uterine artery then form an anastomosis with the branches of the ovarian artery in the upper portion of the broad ligament.

The *arterial branches* leading from the main ascending trunk of the uterine artery form a dense network of fine blood vessels abundantly supplying blood to the muscular and mucous coats of the uterus and the overlying peritoneum.

The *ovarian artery* (a. ovarica) is a paired vessel originating from the abdominal aorta (slightly below the renal artery); it descends together with the ureter, courses in the infundibulopelvic ligament to the superior portion of the broad ligament, and divides into branches leading to the ovary

Fig. 13. Blood supply of the reproductive organs:
1 — uterus, *2* — fallopian tube, *3* — ovary, *4* — ovarian artery, *5* — hypogastric artery, *6* — uterine artery

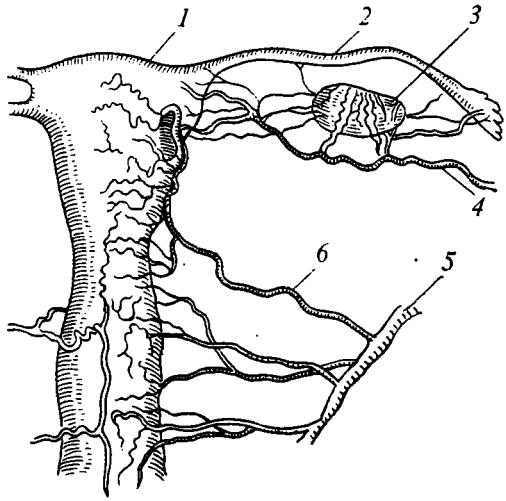

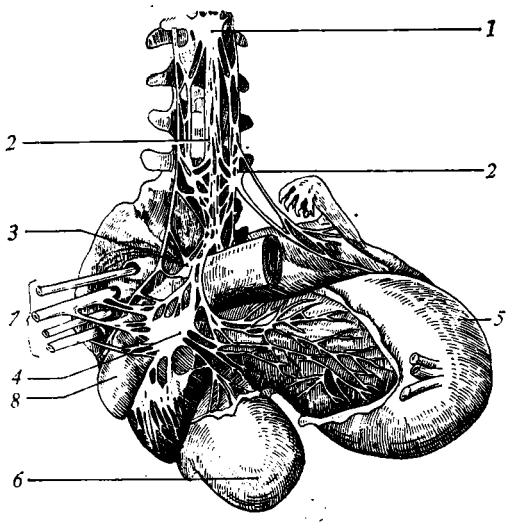

Fig. 14. Innervation of internal genitalia: *1* — aortal plexus, *2* — superior hypogastric plexus, *3* — inferior hypogastric plexus, *4* — uterovaginal plexus, 5 — uterus, *6* — bladder, *7* — sacral nerves (I-IV), *8* — rectum

and the tube; the trunk of the ovarian artery forms an anastomosis with the end of the uterine artery. In addition to the uterine and pudendal arteries, the blood supply of the vagina is derived through the branches of the vesical and haemorrhoidal arteries.

Blood is drained from the genitalia through the veins which are synonymous to the arteries (usually two veins for one artery). The veins of the reproductive organs form plexus (utero-ovarian, vesical, etc.).

Nerves

The reproductive system is innervated by the sympathetic and parasympathetic nervous system, as well as by the spinal nerves (Fig. 14).

The fibres of the sympathetic nervous system innervating the organs of reproduction originate from the aortal and solar plexus, course downward, and form the superior hypogastric plexus at the level of the 5th lumbar vertebra. Nerve fibres descend from the hypogastric plexus and ramify to form the right and left hypogastric plexus.

Nerve fibres pass from these plexus to a powerful uterovaginal plexus (pelvic plexus) situated in the parametrium laterally and posteriorly to the uterus, at the level of the internal os of the endocervical canal. Branches of the pelvic nerve (n. pelvicus), which are part of the parasympathetic nervous system, pass to this plexus. Sympathetic and parasympathetic fibres originating from the uterovaginal plexus innervate the vagina, the uterus, distal portions of the fallopian tubes, and the bladder. The body of the uterus is mainly innervated by sympathetic nerve fibres, while the cervix and the vagina mainly by the parasympathetic nerves.

The ovary is innervated with both sympathetic and parasympathetic nerves from the ovarian plexus (p. ovaricus). Nerve fibres from the aortal and renal plexus enter the ovarian plexus. The external genitalia and the pelvic floor are mainly innervated by the pudendal nerve (n. pudendus). Thus the nerves of the internal genitalia are connected with the other internal organs through the aortal, solar, renal, and other plexus. The walls of the uterus, tubes, and also ovarian medulla have dense networks of nerves forming plexus. The finest nerve branches lead from these plexus to the muscular fibres, the epithelium, and all other cell elements. Inside the uterine mucosa the nerve endings lead to the glands, and in the ovaries to the follicles and corpora lutea. The finest nerve endings terminate in buttons, bulbs, etc., which accept chemical,

mechanical, thermal, and other stimuli. Nerve endings of the internal genitalia are interoceptors which transmit impulses from the internal organs.* The stimuli accepted by the sensory nerve terminals are transmitted through the nerve fibres to higher portions of the nervous system to the regulatory centres, from which the impulses are conducted through the secretory and motor fibres to the reproductive organs to control their function (contractions of the muscles, secretion of the glands, production of hormones, etc.) Nerve centres regulating the function of the reproductive system are situated at different level of the central nervous system: in the spinal cord, the subcortical regions of the brain, and the cerebral cortex.

I. P. Lazarevich, N. F. Tolochinov and I. M. Sechenov were among the first to maintain that the function of the female reproductive organs depends on the psychic condition of the woman.

Clinical observations show that a strong emotional stress can suspend the menses, provoke an abortion or premature labour, and interfere with normal parturition. And conversely, a favourable stimulation of psychics of the parturient facilitates adequate labour, and relieves or completely removes pain, which has recently become a common practice in psychotherapy of the woman in labour.

Lymphatics

The lymphatic system of the reproductive organs comprises a dense network of sinuous lymphatic vessels and many nodes, which predominantly pass along the blood vessels (Fig. 15). The lymphatic drainage of the external genitalia and the lower third of the vagina occurs through the inguinal lymph nodes, and of the remaining vagina and the cervix through the lymph nodes situated along the hypogastric and iliac blood vessels.

The uterine body, the tubes and the ovaries drain through the vessels lying along the ovarian artery into the lymph nodes situated on the aorta and the inferior vena cava. These systems of lymph nodes and vessels are communicated through lymphatic anastomoses.

Fig. 15. Lymphatic system of the reproductive tract:
1 — inguinal nodes, *2* — hypogastric nodes, *3*— iliac nodes

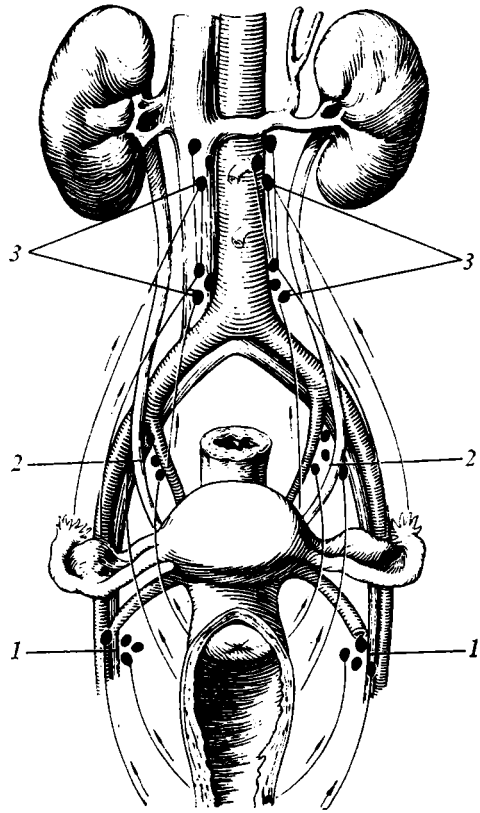

* Nerve endings stimulated by the external environment are called exteroceptors. These are sensory nerve terminals of the skin (the eye, the ear, the mucous membrane of the nose).

Mammary Glands

The mammary glands (mammae) are cluster-like structures (Fig. 16,*a*). The parenchyma of the gland consists of numerous vesicles (alveoli) located around a small duct (ductus lactiferi) and opening into it. These glandular formations are grouped together to form larger lobules. The epithelium of the glands has a secretory function.

Fig. 16. Mammary gland:
a — structure of the mammary gland; *1* — lobules, *2* — fat, *3* — duct, *4* — nipple; *b* — areola and nipple

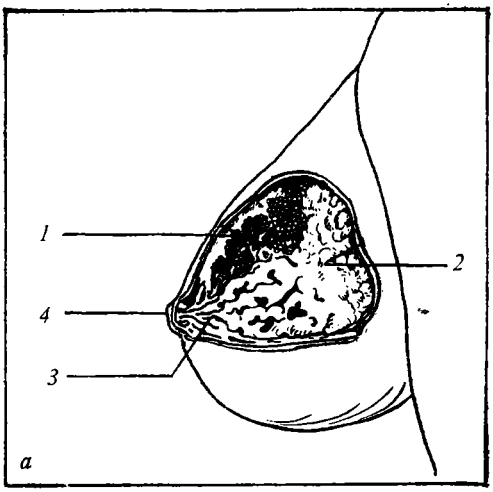

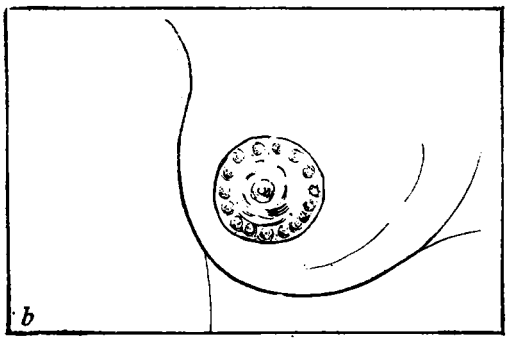

The space between the lobules is filled by fibrous connective tissue interlaced with elastic fibres and fat.

A mammary gland has from 15 to 20 lobules, each having its own lactiferous sinus into which all smaller ducts connected with the alveoli secrete. The duct of each lobule opens independently on the nipple, so that the latter has from 15 to 20 openings (depending on the number of the lobules). Before opening on the nipple surface, each duct forms a sinus under the areola. The nipple (papilla) is a pigmented projection of soft wrinkled skin on the anterior surface of the breast (Fig. 16, *b*). The nipple is a cylinder- or cone-shaped structure of variable size. Sometimes the nipple may be flat or even inverted, which makes it difficult for an infant to obtain milk. The pigmented skin around the nipple (areola) contains Montgomery's glands which are rudimentary mammary glands. The nipple and the areola contain smooth muscles closely underlying the skin and many nerve receptors.

The parenchyma of the mammary gland develops intensely at puberty, the growth being stimulated by the follicular hormone secreted in the ovaries, while the development of the alveoli depends on the hormone of the corpus luteum. The complete development of the breasts coincides with the time of sexual maturation. The parenchyma of the breasts becomes gradually atrophied with age.

The blood supply of the mammary glands is derived through the corresponding arteries (a. mammaria) and the branches leading from the axillary artery. The lymphatic vessels pass to the axillary lymph nodes.

The *function of the mammary glands.* The mammary glands secrete milk for

nourishment of the infant. The secretory function of the mammary glands begins with pregnancy and attains its maximum after childbirth.

Milk secretion is stimulated by the lactogenic hormone produced by the anterior pituitary, whose activity is controlled by the central nervous system. When a baby is nursed, the nerve elements of the mammary glands are stimulated and the corresponding impulses are sent to the central nervous system. The shifts occurring here intensify the production of the lactogenic pituitary hormone which in turn stimulates the secretory function of the mammary glands.

M. Mironov shows that cutting of the nerves, leading to the mammary glands, decreases the secretion of milk and alters its composition.

L. Voskresensky has established that milk secretion can be intensified by various conditioned-reflex stimuli such as the sight of the baby, sounds which can incidentally be associated with nursing, etc. Strong emotional stress may also affect the secretion of milk, which is another evidence of the direct connection between the secretory function of the breasts and the cerebral cortex.

The secretion of milk can be described as follows. The protoplasm of glandular epithelium in a lactating breast forms milk globules which enter the alveoli. The liquid portion of the secretion is also the product of the glandular epithelium (not the filtrate of the liquid portion of the blood).

Lactation is stimulated by the receptors of the nipple and the areola during breast feeding (suckling). The stimulation of the nerve endings causes contraction of the muscular elements in the nipple and the areola. As a result, the nipple becomes rigid (erect) which helps its capture by the baby and promotes secretion of milk. (The composition of milk and breast-feeding recommendations are given in more detail in chapters 11 and 12.)

Periods of Female Life

The life span of the female can be divided into the following periods characterized by anatomical and physiological variations associated with age: (1) childhood, (2) puberty, (3) adulthood or the reproductive period, (4) menopause, and (5) senility.

Childhood. The specific function of the ovaries is absent in childhood. The external and internal genitalia remain underdeveloped. The external genitalia have no hair, the vagina is narrow and short, the uterus body is small, the cervix is long and cone-shaped, and the uterine tubes are sinuous.

Puberty. At the age of 12-16 the female body undergoes sexual maturation. This period is marked by the development of the hypothalamic centres regulating the reproductive function, the development of the gonadotropic function of the pituitary, and the increased secretion of the oestrogenic (follicular) hormone in the ovaries. Under stimulation of this hormone, secondary sex characters (mammary glands, pubic hair, etc.) appear and the genitals assume their adult form (the vagina and the uterus increase in size, the tubes develop, etc.). The period is marked by the onset of the menses (menarche) which, in the absence of pregnancy or pathological conditions, becomes a rhythmically recurrent phenomenon for the entire reproductive life of the woman. The onset of the menarche is known to be influenced by many factors such as climate,

nutrition, etc. The usual age of menarche is about thirteen, while the pubertal period is completed at the age of 17-18. In cases of malnutrition, or after grave diseases, sexual maturation can be retarded and the appearance of the first menses delayed.

Adulthood. This period follows the years of puberty and continues for thirty or thirty-five years. It is characterized by the active function of the reproductive system. The important processes of the female life such as pregnancy and childbirth occur during this period.

Menopause. This period usually begins between the age of 45 and 47 and lasts for two or three years. The period is marked by a gradual decline in reproductive capacity coincidental with irregularity of the menses, which usually become profuse, lengthy or delayed followed by a complete cessation. The initial stage of the menopause is marked also by vascular disorders: rushes of blood, sudden flushes, rise in the arterial pressure, vertigo. Women often complain of fatigue, irritability, insomnia, etc. These phenomena are however absent in balanced healthy women.

Senility. The period is characterized by a gradual decline in all vital functions of the body. The genitals become gradually atrophied, the vagina narrows, its transverse folds are smoothed down, the fornices become levelled, the uterus sharply decreases in size, the ovaries shrink and become dense.

The Menstrual Cycle

The body of an adult woman undergoes rhythmically recurring complex changes which prepare her for pregnancy. These normally repetitive important changes are known as the *menstrual cycle.*

The length of the menstrual cycle varies but in most women it continues for four weeks (28 days). In some women it can be shorter (three weeks) and in rare cases it can last for 30-35 days.

It should be remembered that the menses culminate the sequence of physiological changes which occur in the woman for three to four weeks, i.e. they complete the menstrual cycle but not initiate it. The menses indicate that the preceding processes, which were aimed to prepare the body for pregnancy, have ended and that the unfertilized egg has perished. On the other hand the menstrual bleeding is the most marked sign in the cyclic processes, and for this reason the first day of bleeding will be most convenient to begin counting the length of the menstrual cycle.

The cyclic changes are most marked in the reproductive organs, viz., in the ovaries and the uterine mucosa. But these are only part of the general rhythmic changes occurring in the entire female body. Thus the following changes can be distinguished: (a) in the entire body, (b) in the ovaries (the ovarian cycle), and (c) in the uterus (the uterine cycle). Cyclic changes also occur in the other parts of the reproductive tract but they are less pronounced.

Cyclic changes in the entire body. The cyclic changes in the ovaries and the uterus have their effect on the central nervous system, which is mediated not only by the reflexive (nervous) pathways but also by the ovarian hormones whose production varies through the phases of the menstrual cycle.

In connection with the periodic variations in the activity of the nervous

system many women, before the onset of the menses, become easily irritable, fatigable, and sleepy, and conversely, after cessation of the menstrual bleeding they feel agile and brisk. Hidrosis, increased tendon reflexes and other phenomena which often precede the menses also subside.

It has been established that during the menses, the excitation and inhibition processes alternate rapidly with prevalence of inhibition at the end. Normally these changes in the nervous system would not pass beyond the physiological norm or adversely affect the work capacity of the woman. She may proceed with her routine duties which may involve intense activity of the cerebral cortex.

During the menstrual cycle, blood circulation, thermoregulation of the body and the metabolism also undergo wave-like shifts, which are associated with the variations in the function of the nervous system. This was first established by the Russian authors D. O. Ott, S. S. Zhikharev, and others. The period preceding the menses is marked by accelerated heart rate, increased blood pressure and slightly elevated body temperature. During the menses, the pulse is slowed down, the blood pressure and body temperature slightly drop. These phenomena are only transient and disappear after the cessation of the menses. There is evidence that the counts of erythrocytes and thrombocytes in the albuminous fraction of the blood also vary during the menstrual cycle.

The mammary glands change as well. The breasts become firm, engorged, and more sensitive before the menses due to the development of new foci of glandulous tissue. These phenomena subside after the cessation of the menses.

The anterior lobe of the pituitary plays an important role in the menstrual cycle. Stimulated by neurosecretion of the hypothalamic centres regulating the function of the reproductive system, it produces pituitary hormones including those stimulating the ovarian function (gonadotropic hormones).

The neurosecretion stimulating the production of the gonadotropic hormones by the pituitary is called the releasing factor. The hypothalamus functions in close association with the other cerebral structures including parts of the higher central nervous system.

The anterior pituitary produces three hormones acting on the ovaries:

(1) follicle-stimulating hormone which stimulates the growth and maturation of follicles in the ovaries and also the formation of the follicular (oestrogenic) hormone;

(2) luteinizing hormone which causes the growth and maturation of the corpus luteum;

(3) a luteotropic hormone which stimulates the formation of progesterone, the hormone of the corpus luteum. It is supposed that the secretion of progesterone by the corpus luteum is stimulated by the luteinizing hormone. The follicle-stimulating hormone is predominantly produced during the first half of the menstrual cycle and the luteinizing and luteotropic hormones in the second half.

The **ovarian cycle.** The gonadotropic hormones produced by the pituitary gland evoke rhythmic changes in the ovaries, which can be subdivided into the following three phases: (a) follicle ripening (the follicular phase); (b) the rupture of the mature follicle (the ovulatory phase), and (c) the formation of the corpus luteum.

(a) *Follicle ripening.* A primordial

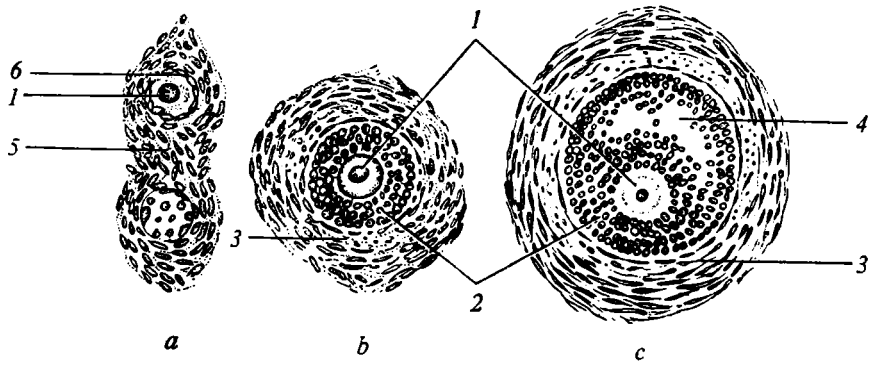

Fig. 17. Initial stages of the development of follicle:
a — primordial follicles, *b* — initial maturation of the follicle, *c* — formation of the antrum in the ripening follicle; *1* — oocyte, *2* — granulosa layer, *3* — connective tissue, *4* — antrum, *5* — stroma, *6* — epithelium of a primordial follicle

follicle consists of an immature oocyte lined by a layer of epithelial cells (the future granulosa layer). On the outside the follicle is surrounded by the connective tissue. The primordial follicles are formed during the intrauterine period of foetal growth and in early childhood. Infantile follicles are estimated to be as many as 400 000-500 000, but as a child reaches puberty, only 35 000-40 000 will continue their development while the remaining follicles will undergo regression. Of the remaining 35 000-40 000 primordial follicles only 450-500 will attempt to become mature while the rest will undergo physiological atresia. As defined by K. F. Slavyansky, atresia is the death of the ovarian follicle before it reaches maturity; the oocyte and the granulosa layer disintegrate and the follicle is replaced by the connective tissue.

A follicle matures in the first half of the menstrual cycle. i.e. during fourteen days of a 28-day cycle (or during 10-11 days with a 21-day cycle). At this period, all its component parts, such as the oocyte, the granulosa layer and the connective-tissue coat undergo substantial changes (Fig. 17).

The oocyte increases in size 5-6 times, a transparent coat (zona pellucida) is formed on its surface, and complicated changes occur in the protoplasm. The final maturation of the follicle is preceded by a two-step division. The first division (ripening) gives two unequal cells. The smaller one is rejected while the larger undergoes another division during which half the total number of chromosomes are rejected. After the second division (reduction) the ovum becomes mature and prepared for fertilization.

The follicular epithelium (granulosa layer) proliferates during maturation, the number of its layers increases, and it turns into the granular coat (membrana granulosa folliculi). First the granulosa cells fill the space between the oocyte and the connective-tissue coat, but later on cavities filled with fluid are formed in the centre of the cell accumulation. The cavities are then united into an antrum inside the follicle filled with a transparent follicular fluid or liquor.

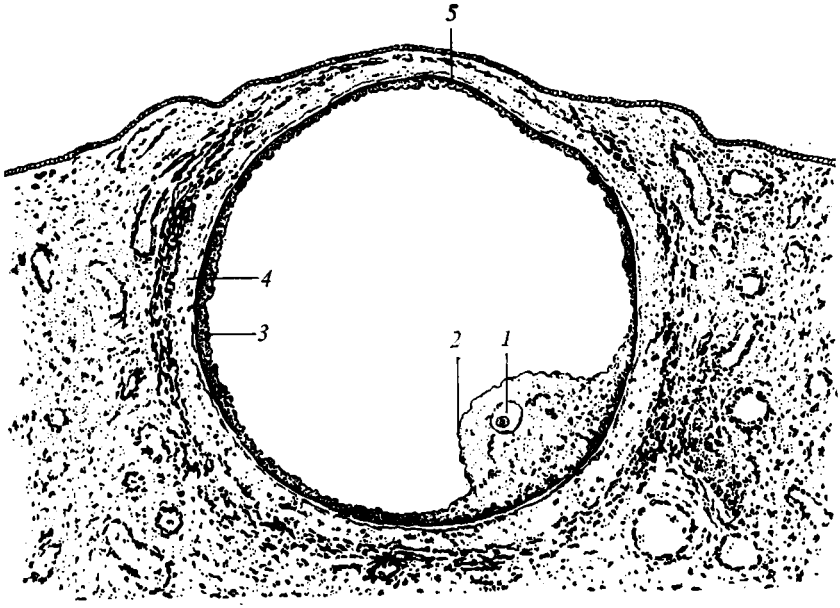

Fig. 18. Mature follicle:
1 — oocyte, 2 — cumulus oophorous, 3 — granulosa cells, 4 — connective tissue, 5 — thinned ovary tissue at the point of prospective rupture of the follicle

As the fluid is accumulated in the antrum. the granulosa cells move toward the ovum and the wall of the follicle. The granulosa cells that surround the ovum are called the corona radiata. The oocyte surrounded by the radiating crown is located eccentrically upon a parietal mound of granulosa cells known as the cumulus oophorous (cumulus ovigerus) (Fig. 18). As the follicle ripens, a mature ovum is detached from the mound into the follicular fluid.

The follicle produces a hormone known as the follicular or oestrogenic hormone, which has a very complicated action on the female body.

1. At puberty the oestrogenic hormone stimulates the growth and development of the uterus, vagina, external genitalia and also secondary sex characters.

2. In adulthood the oestrogens, produced periodically by the ripening follicles, stimulate proliferation (multiplication) of the endometrium cells.

3. The oestrogens increase the muscular tone of the uterus and its excitability and sensitivity to substances stimulating its contractions.

4. The oestrogens also promote the growth and the function of the mammary glands and intensify the sexual feelings.

As the follicle matures, its connective-tissue membrane changes to form two coats, viz., theca interna (rich in cell elements and capillaries) and the outer fibrous theca externa (containing larger vessels). Before immediate ovulation the follicle increases in size and its pole becomes projected over the surface of the ovary, where the ovarian tissue thins.

(b) *Ovulation.* This is the rupture of the graafian follicle with a discharge of a mature unimpregnated ovum (Fig. 19). Surrounded by a radiating crown, the ovum, together with the follicular fluid, is discharged into the peritoneal cavity from where it enters the fallopian tube.

The ovulation occurs on the 14-15th day of a 28-day cycle counting from the first day of the menses (or earlier with a 21-day menstrual cycle). This is the best time for conception.

(c) *Formation of corpus luteum* (the lutein phase). A new and very important internal secretion gland, the corpus luteum, is formed from the ruptured mature follicle. It produces progesterone.* The progressive development of the corpus luteum lasts for 14 days with a 28-day cycle (for shorter periods with a 21-day cycle) and consumes the span of the second half of the menstrual cycle, i.e. from the ovulation to the onset of the menses.

The corpus luteum develops from a ruptured follicle as follows. After the intrafollicular fluid and the mature ovum are discharged from the follicle, its walls become folded and the site of the rupture is healed, while a small clot of blood is formed in the antrum. The granulosa cells lining the antrum of the follicle intensely proliferate, increase in size, and lutein (the lipoid substance) is accumulated in their protoplasm to give the yellow colour to the formed gland. Hence the name corpus luteum (from Latin *luteum* yellow). The granulosa cells turn into the lutein cells of the corpus luteum. Along with the development of the granulosa layer, intense vascularization occurs through the invasion of blood vessels from the connective tissue. The capillaries form a dense network in the lutein layer which surrounds each cell. The vascularization promotes the resolution of the blood clot in the follicular antrum.

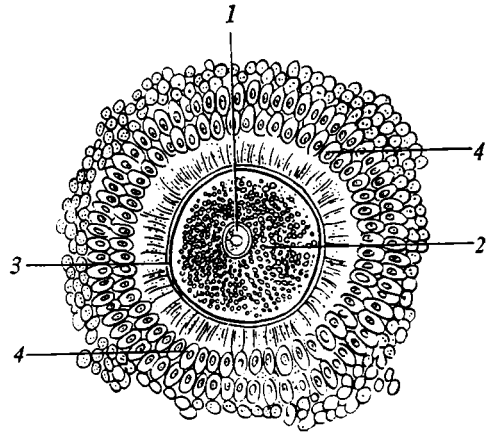

Fig. 19. An oocyte surrounded with radiating crown:
1 — nucleus, *2* — protoplasm, *3* — zona pellucida, *4* — radiating crown

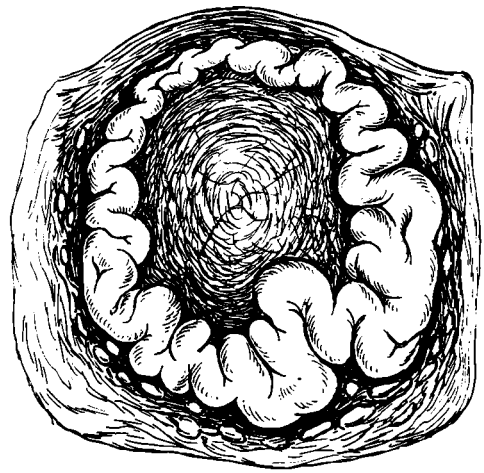

Fig. 20. Mature corpus luteum

* Latin *gestatio*, from *gestare* to bear. Progesterone is the hormone which prepares the body for carrying the foetus in the uterus (pregnancy).

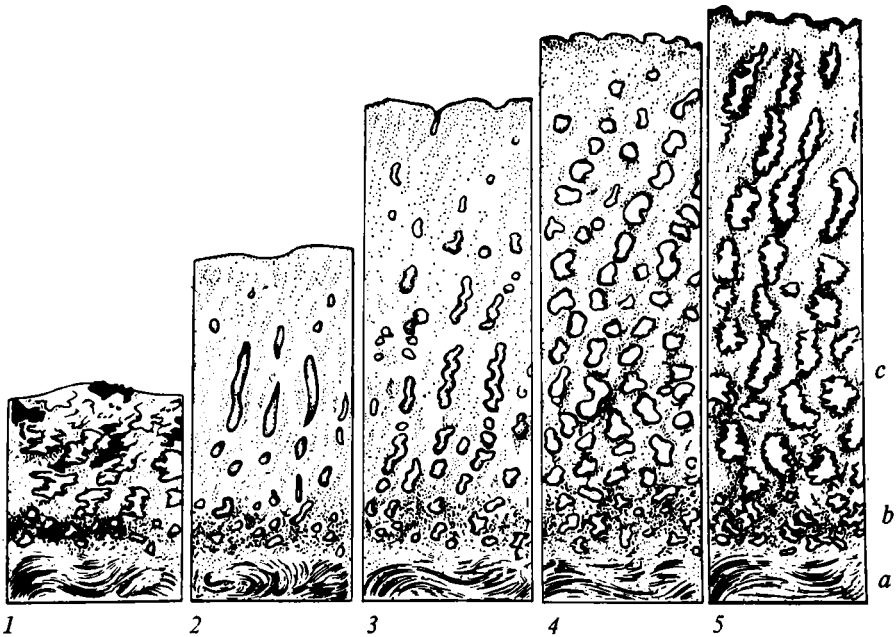

Fig. 21. Endometrium in various phases of the menstrual cycle:
1 — desquamation phase, *2* and *3* — proliferative phase, *4* and *5* — secretory phase; *a* — muscular layer; *b* — basal layer of the mucosa; *c* — functional layer of the uterine mucosa

At the stage of maturity (Fig. 20) the corpus luteum grows to the size of a nut and one of its poles projects over the surface of the ovary. If the ovum released from the follicle becomes fertilized, the corpus luteum continues developing and functions during the first months of pregnancy. This is the corpus luteum of pregnancy (corpus luteum graviditatis). Should the ovum remain unimpregnated, the corpus luteum begins its back development from the 28th day of a 28-day cycle (or from the 21st day with a 21-day cycle). The lutein cells degrade, the vessels stop functioning, and the connective tissue proliferates. The corpus luteum is converted into a cicatrix which will later resolve as well.

The corpus luteum is formed during each menstrual cycle. If impregnation has not taken place, it is called a false corpus luteum or corpus luteum of menstruation (c. luteum menstruationis). The hormone secreted by the yellow body (progesterone) produces the following action on the female body:

(1) induces complicated changes in the mucosa of the uterus to prepare it for pregnancy (secretory phase);

(2) decreases excitability and contractility of the uterus which also promotes the development of pregnancy;

(3) together with the follicular hormone, progesterone stimulates the changes in the mammary glands to prepare them for secreting milk.

The production of progesterone discontinues when the corpus luteum begins its regression. A new follicle starts ripening, which is followed by its maturation, ovulation, and the formation of a new corpus luteum.

The **uterine cycle.** The ovarian hormones produced in the follicle and the corpus luteum induce cyclic changes in the tone, excitability and blood supply of the uterus. But the most significant changes occur in the functional layer of the endometrium. These are rhythmically recurring proliferation, followed by qualitative changes, desquamation, and regeneration of the functional layer. Like the ovarian cycle, the uterine cycle continues 28 days (less frequently 21 or 30-35 days) and is divided into the following stages: (a) desquamation, (b) regeneration, (c) proliferation, and (d) secretion (Fig. 21).

(a) The *desquamation phase* is characterized by the menstrual bleeding which normally continues for 3 to 5 days. These are the menses proper. The functional layer of the endometrium degenerates, is detached from the uterus wall and discharged from the uterus together with fluids secreted by the uterine glands and the blood of the disintegrated vessels. The desquamation phase is coincidental with the degradation of the corpus luteum in the ovary.

(b) The *regeneration phase* (renewal of the growth) of the endometrium begins during the desquamation period and is completed by the fifth or sixth day of the menstrual cycle. The functional layer of the uterine mucosa is renewed through proliferation of epithelium of the glandular remnants and other elements of the basal layer (stroma, vessels, nerves).

(c) The *proliferative phase* is coincidental with maturation of the follicle in the ovary; it continues till the 14th day of a 28-day cycle (till the 10-11th day of a 21-day cycle). The oestrogenic (follicular) hormone stimulates proliferation of the stroma and the glands of the uterine mucosa. The glands become elongated and coil into spirals. They contain no secretion at this time of the cycle. The uterine mucosa thickens 4-5 times.

(d) The *secretory phase* coincides with complete maturation of the corpus luteum in the ovary and continues from the 14-15th day to the 28th day, that is till the end of the menstrual cycle.

The hormone secreted by the corpus luteum induces very important qualitative changes in the endometrium. It stimulates the function of the glands, their cavities dilate, and bay-shaped formations appear in their walls. The stromal cells increase in size, become slightly rounded and resemble decidual cells that are formed during pregnancy. Glycogen, phosphorus, calcium and other substances are deposited in the uterine mucosa. All these changes provide favourable conditions for the growth of a fertilized ovum. If impregnation does not occur the corpus luteum undergoes regression, the functional layer of the endometrium which has developed to the secretory phase is desquamated, and the menstrual bleeding begins.

This is followed by a new series of the cyclic events in the ovary, the uterus and the entire body (Fig. 22): another follicle matures, then follows ovulation, the corpus luteum develops in the ovary, and the endometrium changes accordingly. Repetitive changes also occur in the uterine cervix, the vagina, and other organs of the reproductive system but these are less

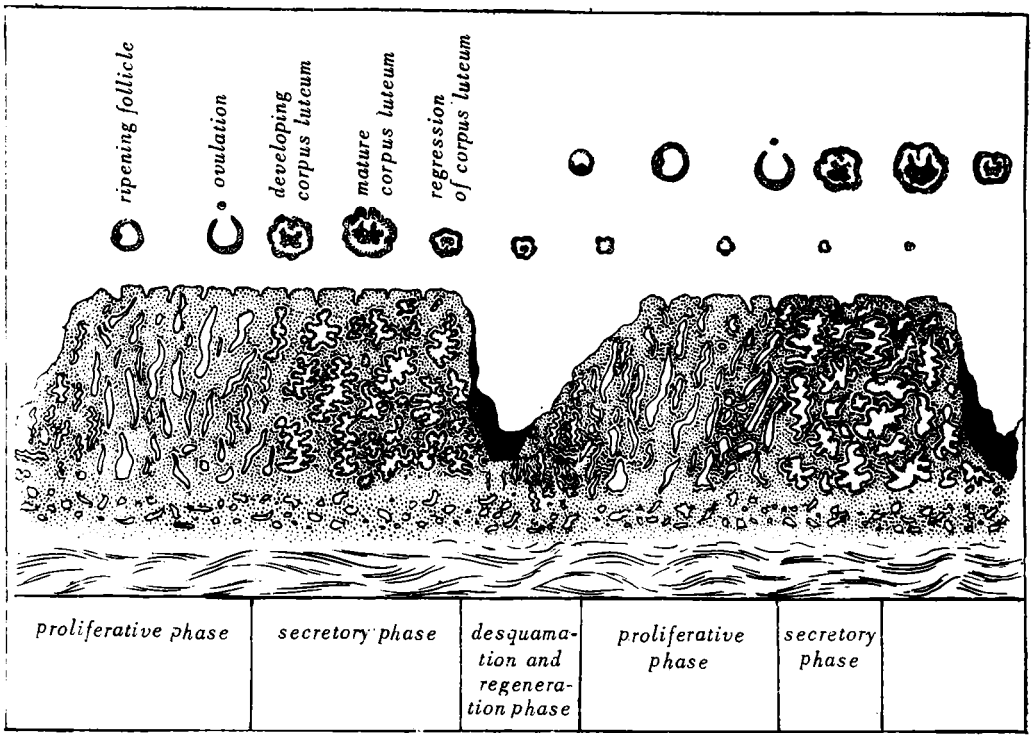

Fig. 22. Cyclic changes in the ovaries and endometrium

marked than in the ovaries and the endometrium.

The changes mentioned above recur at regular intervals during the entire span of the reproductive life of the woman. They are suspended during certain physiological processes such as pregnancy and breast-feeding. The disturbances in the menstrual cycle may also be caused by pathological conditions (grave diseases, psychic disorders, malnutrition, etc).

Hygiene of the Menses

The menstrual bleeding normally lasts from three to five days (not over seven days). Between 50 to 100 ml of blood is shed during the normal menstrual period.

The menstrual discharge contains considerable amounts of uterine secretion and disintegrating particles of the functional layer of the endometrium.

The menstrual blood usually does not clot which is due to the presence of enzymes in it. It is darker than the blood circulating in the vessels.

Although the menses are a normal physiological process the changes occurring in the body during this period require observation of certain hygienic rules. The woman shall perform her usual duties but avoid exhausting activity, colds, or overheating.

The diet of a woman during men-

struation should be free from spicy seasonings or alcoholic drinks which intensify the blood flow to the internal and pelvic organs. Intense blood circulation in the reproductive organs can provoke profuse bleeding.

The menstrual desquamation of the functional layer of the endometrium forms a 'wound' surface. The ingress of pathogenic microorganisms and infection of this 'wound' may cause inflammatory processes in the uterus, the tubes, the ovaries and the pelvic peritoneum. Cleanliness of the body and external genitalia should therefore be the point of special care during menses.

The menstrual blood should be given an unobstructed way out. The woman should use perineal pads or tampons to accept the blood. The external genitalia should be given two or three daily washes with lukewarm boiled water. Sexual intercourse and syringing should be avoided since the 'wounded' uterus may be infected. Showers are best substituted for tub baths to prevent the possibility of intrauterine infection through the vagina.

Special rooms should be provided at industrial enterprises and institutions where the woman could take care of herself especially during the menses.

Chapter Two

FEMALE PELVIS

The bony pelvis is a rigid structure holding the internal reproductive organs of the woman, the rectum, the bladder, and the surrounding tissues. In addition, the female pelvis forms the birth canal through which the foetus moves during parturition. The pelvic architecture is therefore of great obstetrical importance.

Bony Pelvis

The bony pelvis is composed of the following four bones: two innominate bones. the sacrum, and the coccyx. The innominate bones form the anterior and lateral boundaries of the bony pelvis while the sacrum and the coccyx form its posterior wall.

In early life (till the age of 16-18) the hip or the innominate bone (os coxae) consists of three separate bones connected by cartilage: the ilium, the ischium, and the pubis. After ossification of the cartilages, the three bones fuse into one innominate bone (Fig. 23). The point of their junction is the acetabulum. The ilium lies superiorly to the acetabulum, the pubis anteriorly, and the ischium inferiorly.

The *ilium* (os ilium) is composed of two parts: the body and the wing. The body is a short thick portion of the ilium forming a part of the acetabulum. The wing is a wide fan-shaped bone, concave on the inner and convex on the outer surface. It is thin at the centre, thickening toward the periphery. The thickest upper ridge of the wing forms the iliac crest (crista ilei) bearing three parallel rough lines to which the abdominal muscles are attached. The blunt bony projection of the anterior end of the iliac crest is the anterior superior spine (spina

Fig. 23. Innominate bone:
A — ilium, *B* — pubis, *C* — ischium; *1* — iliac crest, *2* — anterior superior spine, *3* — anterior inferior spine, *4* — acetabulum, *5* — obturator foramen, *6* — ischial tuberosity, *7* — lesser sciatic notch, *8* — ischial spine, *9* — greater sciatic notch, *10* — posterior inferior spine, *11* — posterior superior spine

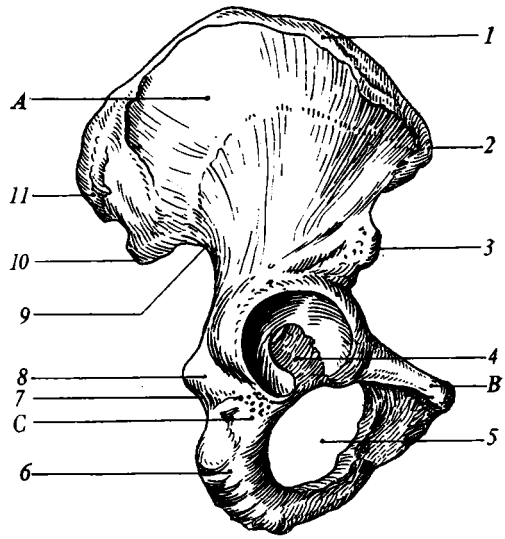

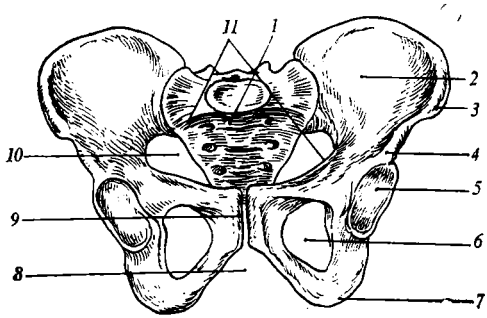

Fig. 24. Female pelvis:
1 — sacrum, *2* — iliac wing, *3* — anterior superior spine, *4* — anterior inferior spine, *5* — acetabulum, *6* — obturator foramen, *7* — ischial tuberosity, *8* — pelvic arch, *9* — symphysis pubis, *10* — pelvic inlet, *11* — innominate line

iliaca anterior superior) and another projection, found somewhat inferiorly, is the anterior inferior spine (spina iliaca anterior inferior). There is a third projection, the iliopectineal eminence (iliopubic tuber), found inferiorly to the anterior inferior spine at the junction with the pubic bone. A depression between the anterior superior and inferior spines is called the lesser sciatic notch (incisura ischiadica minor), and another indention found between the anterior inferior spine and the iliopectineal eminence is called the greater sciatic notch (incisura ischiadica major).

The posterior end of the iliac crest is the posterior superior spine (spina iliaca posterior superior). Below lies another bony projection, the posterior inferior spine (spina iliaca posterior inferior). The greater sciatic notch lies below the posterior inferior spine.

The inner surface of the ilium bears a ridge-like projection where the wing passes into the body of the bone. This is the innominate line (Fig. 24). It passes from the sacrum across the entire ilium and further to the superior margin of the pubis. The inner posterior portion of the ilium has the so-called auricular surface which forms the sacroiliac joint.

The *ischium* (os ischii) has a body (which is a contributor to the acetabulum) and two branches, the superior and inferior rami. The superior ramus arises from the body of the bone and terminates in the ischial tuber (tuber ischii). The posterior surface of the inferior ramus mounts a projection known as the ischial spine. The inferior ramus passes anteriorly and upwards to join with the inferior ramus of the pubis.

The *pubis* (os pubis) is situated anteriorly and inferiorly to the iliac bone to form the anterior boundary of the pelvis. The pubis is composed of the body and two rami: the upper horizontal (superior ramus) and the lower descending (inferior) ramus.

The short body of the pubis constitutes a portion of the acetabulum while the inferior ramus joins with the corresponding ramus of the ischial bone.

The upper margin of the superior ramus of the pubis bears a sharp ridge which ends in the pubic tubercle (tuberculum pubicum).

The superior and inferior rami of the two pubic bones meet in the midline to form a partly movable joint known as the symphysis pubis. The inferior rami of the pubis form the pubic arch below the symphysis (Fig. 24).

The joining rami of the pubic and ischial bones form a large aperture known as the obturator foramen.

The **sacrum** (os sacrum) consists of five fused vertebral segments (Fig. 24). The size of the vertebrae decreases inferiorly and the sacrum has therefore the shape of a truncated cone. Its wider part, the base, is directed upwards,

while the narrower part, downwards. The dorsal surface of the sacrum is convex, while the ventral surface, forming the sacral cavity is concave. Four rough transverse lines can be found on the anterior surface of the sacrum. These are ossified cartilaginous joints of the sacral vertebral segments. The lines have openings at their ends through which nerve fibres from the spinal cord pass to the pelvic cavity to innervate the reproductive organs.

The convex posterior surface of the sacrum is rough and has three longitudinal crests. The middle crest is composed of fused spinous processes of the vertebrae. The lateral crests are less pronounced; they are formed by fused articular processes of the sacral vertebrae. Four pairs of posterior sacral openings (hiatus) lie on both sides of the middle sacral crest. A sacral canal passes downward through the sacrum; it is continuous with the vertebral canal. The lower end of the sacral canal opens on the posterior surface of the inferior portion of the sacrum.

The base of the sacrum (the surface of the first sacral vertebra) is linked with the 5th lumbar vertebra. A sacral promontory (promontorium) is located on the anterior surface of the sacrum base. A dimple can be palpated between the spinous process of the fifth lumbar vertebra and the beginning of the middle sacral crest. This dimple is used as a landmark in pelvic mensuration. Rough articular surfaces are situated on the superior lateral sides of the sacrum upon which it joins with the ilium. The lower tip of the sacrum joins with the coccyx.

The **coccyx** (os coccygis) consists of 4 or 5 fused rudimentary vertebrae forming a small caudal extremity of the vertebral column.

Pelvic Joints

The pelvic bones are joined through the symphysis, the sacroiliac and sacrococcygeal joints. All have cartilages between the bones and are held together by fast ligaments.

The *symphysis pubis* is a partly movable joint (actually a semijoint). The two pubic bones meet in the midline to join with each other through a cartilage inside which a small cleft filled with fluid is often found. The cleft widens during pregnancy.

The superior margin of the symphysis is lined by the superior pubic ligament, while its lower margin is provided with the arch-like band of fibres known as the arcuate ligament of the pubis. The anterior and posterior ligaments are found on the inner and the outer surfaces of the symphysis.

The *sacroiliac joints* have a narrow cavity. These are almost immovable joints. Almost complete absence of articulation in them is due to the rough articular surfaces and very fast ligaments.

Two pairs of ligaments are very important: the sacrospinal ligaments (lig. sacrospinosum) connecting the inferior portion of the sacrum and the ischial spines, and the sacrotuberal ligaments (lig. sacrotuberosum) leading from the inferior sacrum and the coccyx to the ischial tuberosities. These ligaments cover the two sciatic notches to form larger and smaller ischial apertures through which the muscles, vessels, and nerves enter.

The *sacrococcygeal* joint is rather movable. During labour, as the foetus passes through the pelvis, the coccyx is moved posteriorly to increase the distance from the inferior margin of the symphysis to the tip of the coccyx by 1.5-2 cm.

False Pelvis

The female pelvis is subdivided into the large or false pelvis (pelvis major) and small or true pelvis (pelvis minor). The border between the false and the true pelvis is marked anteriorly by the superior margins of the symphysis and the pubis, laterally by the innominate line, and posteriorly by the promontory of the sacrum. The plane between the large and small pelvis is the pelvic or obstetrical inlet (also called the superior strait of the pelvis) which is of great obstetrical importance.

The *false pelvis* is much wider than the true pelvis. It is bounded laterally by the large fan-shaped iliac bones, posteriorly by the last lumbar vertebrae and anteriorly by the lower portion of the abdominal wall.

The volume of the false pelvis varies depending on the contraction or relaxation of the abdominal muscles.

The false pelvis is accessible for mensuration and its diameters can easily be determined to reasonable accuracy.

Fig. 25. Diameters of the pelvic inlet: *1* — anteroposterior diameter (true conjugate), 11 cm, *2* — transverse diameter, 13 cm, *3* — left oblique diameter, 12 cm, *4* — right oblique diameter, 12 cm

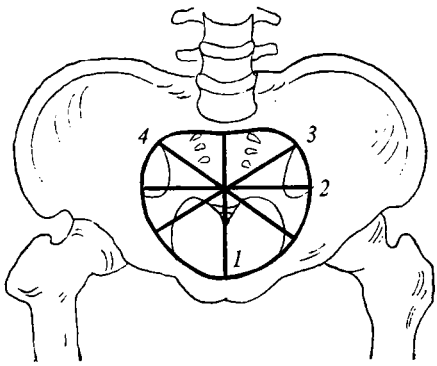

Its diameters are indicative of the size of the small pelvis, which cannot be measured directly. Meanwhile it is very important to know the diameters of the true pelvis through which the foetus passes during partition. (For the diameters of the false pelvis see page 49.)

True Pelvis

Planes and diameters of small pelvis. The true pelvis is the bony part of the birth canal. It is bounded posteriorly by the sacrum and the coccyx, laterally by the ischial bones, and anteriorly by the pubis and the symphysis. The posterior wall of the true pelvis is three times longer than the anterior one. The upper portion of the small pelvis is a continuous rigid ring. The lower part of the pelvis is not continuous; it is provided with obturator foramen and sciatic notches limited by two pairs of ligaments (sacrospinal and sacrotuberal ligaments).

The following parts of the small pelvis are distinguished: pelvic inlet, pelvic cavity, and pelvic outlet. The pelvic cavity has wider and narrower portions. Accordingly four planes are distinguished: (1) pelvic plane of inlet; (2) wide pelvic plane; (3) narrow pelvic plane, and (4) pelvic outlet plane.

The *pelvic plane of inlet* (superior pelvic plane) is the area bounded anteriorly by the superior margin of the symphysis and the pubis, laterally by the innominate line, and posteriorly by the sacral promontory. The inlet plane has the shape of a kidney or a transverse oval with a depression corresponding to the sacral promontory. The inlet has the anteroposterior, transverse, and two oblique diameters (Fig. 25).

1. The anteroposterior diameter is the distance from the sacral promontory to the most prominent point of the inferior surface of the symphysis. This is the obstetric or true conjugate (conjugata vera).

The anatomical conjugate is also known, which is the distance from the sacral promontory to the middle of the superior margin of the symphysis. The anatomical conjugate is 0.3-0.5 cm longer than the obstetric conjugate.

The true conjugate normally measures 11 cm.

2. The transverse diameter is the distance between the most lateral aspects of the innominate line (13 cm).

3. Oblique diameters. There are two oblique diameters, designated 'right' and 'left', each measuring 12 cm.

The right oblique diameter is the distance from the right sacroiliac joint to the left iliopectineal eminence of the pubis and the left oblique diameter is the distance from the left sacroiliac joint to the right iliopectineal eminence. To help the obstetrician orient in the direction of the oblique diameters, M. S. Malinovsky and M. G. Kushnir offer the following method (Fig. 26). The hands are held together at a right angle (with the palms facing each other) and the fingers are moved in the direction of the pelvic outlet of the woman in the supine position. The plane of the left hand will then coincide with the left oblique diameter and of the right hand with the right oblique diameter.

The *wide pelvic plane* is bounded anteriorly by the inner aspect of the symphysis, laterally by the middle of the acetabulum, and posteriorly by the junction of the second and third sacral vertebrae.

The wide pelvic plane has the anteroposterior and transverse diameters.

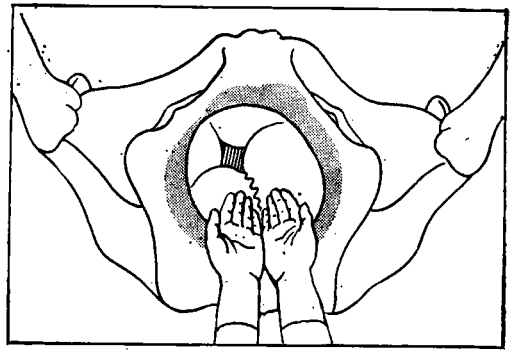

Fig. 26. Determining oblique diameters of the pelvis.
The plane of the left hand coincidental with the sagittal suture is the plane of the left oblique diameter.

1. The anteroposterior diameter extends from the inner aspect of the symphysis to the point of junction of the second and third sacral vertebrae, and measures 12.5 cm.

2. The transverse diameter is the distance between the upper ends of the acetabulum. This measures 12.5 cm.

The pelvic bones do not form a continuous bony ring in this region of the pelvis and oblique diameters are therefore actually absent; by convention they are assumed to be 13 cm.

The *narrow plane of the pelvis* is bounded anteriorly by the lower margin of the symphysis, laterally by the ischial spines, and posteriorly by the sacrococcygeal joint. It has the anteroposterior and transverse diameters.

1. The anteroposterior diameter connects the sacrococcygeal joint and the lower margin of the symphysis (the top of the pubic arch); it measures 11 cm.

2. The transverse diameter is the distance between the ischial spines; this measures 10.5 cm.

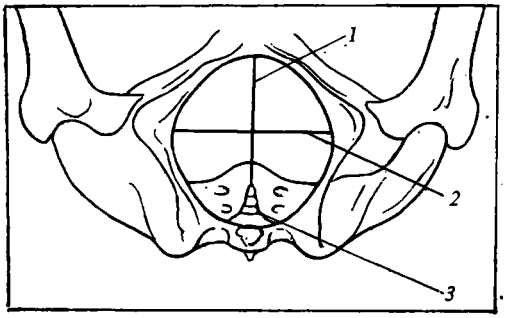

Fig. 27. Pelvic outlet diameters: *1* — anteroposterior diameter, 9.5-11.5 cm, *2* — transverse diameter, 11 cm, *3* — coccyx

The *pelvic plane of outlet* is bounded anteriorly by the lower margin of the symphysis, laterally by the ischial tuberosities, and posteriorly by the coccyx. The plane of the pelvic outlet is made up of two triangular components with a common base represented by a line connecting the two ischial tuberosities. This plane has the anteroposterior and transverse diameters (Fig. 27).

1. The anteroposterior diameter of the pelvic outlet extends from the end of the coccyx to the lower margin of the symphysis (9.5 cm). When the foetus passes through the small pelvis, the coccyx is moved posteriorly through 1.5-2 cm to increase the anteroposterior diameter to 11.5 cm.

Table 1

Pelvic plane	Diameter, cm		
	antero-posterior	transverse	oblique
Pelvic inlet	11	13	12
Wide pelvic plane	12.5	12.5	13 (conventional
Narrow pelvic plane	11	10.5	—
Pelvic outlet	9.5-11.5	11	—

2. The transverse diameter of the pelvic outlet plane connects the inner surfaces of the ischial tuberosities and measures 11 cm (Table 1).

Thus the greatest diameter of the pelvic inlet is the transverse diameter. The anteroposterior and transverse diameters are equal in the wide part of the pelvis, while the oblique diameters are assumed by convention to be the greatest. The anteroposterior diameters are greater than the transverse ones in the narrow part of the pelvis and in the pelvic outlet plane.

The pelvic axis. All planes of the small pelvis are bounded anteriorly by the symphysis at its various points, and posteriorly by various points of the sacrum and the coccyx. The symphysis is much shorter than the sacrum with the coccyx and the pelvic

Fig. 28. Pelvic axis:
1 — true conjugate (pelvic inlet), *2* — anteroposterior diameter of wide pelvic plane, *3* — mid-pelvic (narrow) plane, *4* — pelvic outlet; *a* — *b* — pelvic axis

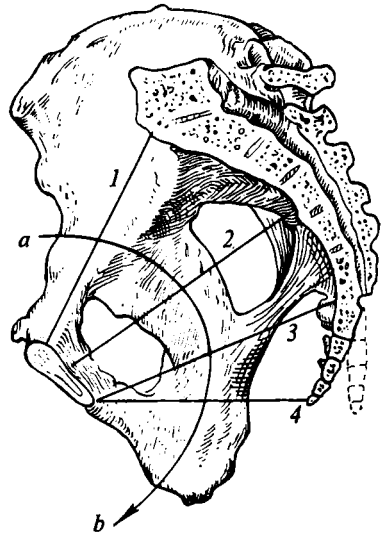

planes therefore meet anteriorly and diverge like a fan posteriorly.

If we now connect the centres of the anteroposterior diameters we obtain a curve rather than a straight line. The curve bisecting the anteroposterior diameters is called the *pelvic axis* (Fig. 28).

The superior portion of the axis is straight but then it curves downward (toward the symphysis) to follow the curvature of the sacrum.

The pelvic axis describes the direction through which the foetus traverses the pelvic cylinder during labour.

Pelvic angle. The superior margin of the symphysis of a woman in the upright position is inferior to the sacral promontory. The true conjugate is normally inclined to an angle of 55-60°. The *relation of the pelvic plane of inlet to the horizontal plane is called the pelvic angle* (*inclinatio pelvis*) (Fig. 29). The degree of inclination depends on body build. The degree of inclination varies depending on many factors such as the physical activity and the body posture. For example, the gravity centre of a pregnant woman is displaced by the end of pregnancy, and the pelvic angle increases by 3-4 degrees. A great angle of inclination can be the cause of the abdomen sagging during pregnancy due to a delayed fixation of the presenting part in the pelvic inlet. The labour in such cases is slow, the foetal head often appears in the wrong position, and the perineum is more likely to tear.

The pelvic angle can be slightly altered (increased or decreased) by placing a cushion under the sacrolumbar region of a woman in the supine position. The elevation of the lumbar region increases and of the sacrum decreases the angle of pelvic inclination.

Effect of body position on pelvic diameters. Pregnancy evokes changes in the pelvic joints. The cartilage of the symphysis becomes hyperhydrous and loosens and the cavity between the mating bones increases. The articular capsules and the ligaments of the symphysis and sacroiliac joints also become more extensible. These changes in the pelvic joints make them more movable and the pelvis can thus ensure normal passage of the foetus.

The changes occurring in the joints during pregnancy also make it possible to alter to a certain degree the pelvic diameters by varying the body posture.

Walcher's position. The parturient is put on her back so that the coccyx rests against the end of a high bed or table. The legs freely hang down (without reaching the floor). The true conjugate (pelvic inlet) increases by 0.3-0.5 cm in this position, while the pelvic outlet diameter decreases correspon-

Fig. 29. Pelvic angle

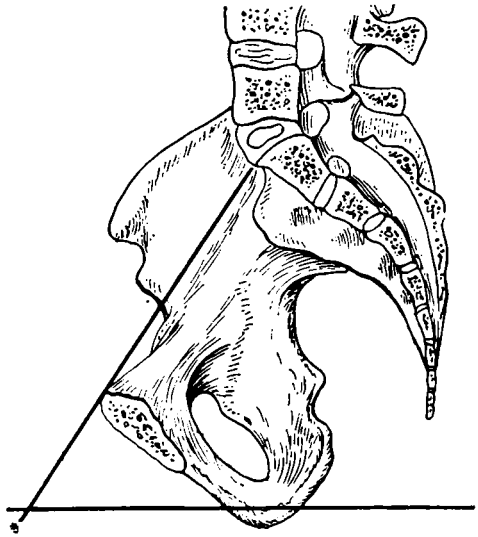

dingly. If the legs are drawn up to the body (the knees are bent and the thighs are flexed on the belly) the pelvic outlet diameter will be slightly increased.

These positions were recommended to parturient women with narrow pelvis.

Development of the Pelvis

In the early intrauterine period, the future pelvis, as well as the entire skeleton, is cartilage. The ossification of the sacral vertebrae begins during the intrauterine period, the fusion being completed only by the age of 17-25; the coccygeal vertebrae continue ossifying till the age of 20.

The cartilage joining the ilium, ischium and pubis into the innominate bone ossifies at puberty.

The pelvis of a newborn girl differs markedly from that of an adult woman both in size and form. The sacrum of a neonate is straight and narrow and directed almost downward, while the sacral promontory is almost absent; its plane is above that of the pelvic inlet. The plane of the inlet into the small pelvis is oval. The wings of the iliac bones are almost upright and the pelvic cylinder narrows significantly towards its outlet.

As the infant grows, the size and the form of the pelvis change significantly.

The development of the pelvis, like the entire body, depends on the environmental and hereditary factors. The manner of sitting, standing and walking is very important for the development of the pelvis in childhood. When the child begins to sit, the downward thrust of weight bearing is brought against the pelvis (through the spinal column). When the child begins to stand and walk, the pressure of the lower extremities on the pelvis is added. As a result of the downward pressure, the sacrum moves forward and encroaches into the pelvic cavity. The pelvis gradually increases in size. The transverse diameters of the pelvis gradually increase while the anteroposterior diameters relatively diminish. The sacrum, which opposes the downward thrust, turns round its horizontal axis so that its promontory lowers and slightly enters the pelvic cavity. The plane of the pelvic inlet thus gradually assumes the shape of a transverse oval with an indention at the promontory region. As the sacrum turns about its horizontal axis, its apex is not displaced posteriorly but is retained in its former position by the tension of the sacrospinal and sacrotuberal ligaments. The interacting forces give the curvature to the sacrum specific to an adult woman.

Defective intrauterine growth may interfere with the normal development of the pelvis. Diseases, malnutrition (or inadequate nutrition) and other disorders in the mother may become the cause of defective pelvis in the child.

Certain diseases of childhood and puberty can also adversely affect the development of the pelvis. These are rickets, various osteites, arthrites, and processes provoking scoliosis. Dislocation of the femur, fractures of the lower extremities and pelvic bones, amputation of the lower extremities, etc., also distort the normal configuration of the pelvis.

The delayed development of the pelvis to the adult form and its inadequate architecture may become the cause of difficult labour or present insurmountable obstacle to child bearing.

Differences in the Male and Female Pelvis

The pelvis of an adult woman differs significantly from the male pelvis. The bones of the female pelvis are thinner, smoother and less massive (Fig. 30).

The female pelvis is wider and lower than the male one (Fig. 31). The female sacrum is wider and placed more posteriorly, while the male promontory projects into the pelvis to a greater extent than in women; the symphysis of the female pelvis is shorter and wider. The pelvic inlet in women is greater, its configuration is oval with an excavation at the promontory, while the pelvic inlet in men can be described like a heart of playing cards (the projection of the promontory is more significant).

The true pelvis of a woman is more spacious and its configuration is more like a cylinder narrowing anteriorly, while the male pelvis is smaller, funnel-shaped, narrowing inferiorly.

The transverse diameter of the pelvic outlet in women is greater because (a) the distance between the ischial tuberosities is greater, (b) the pubic angle is wider (90-100°) than in men (70-75°), while the coccyx is less prominent anteriorly than in the male pelvis.

The described features of the female pelvis provide conditions for the passage of the foetus during labour.

Pelvic Muscles

The pelvic muscles are classified as the parietal and muscles of the pelvic floor.

The **parietal muscles** are so arranged inside the pelvis that they do not decrease its capacity.

Two pairs of parietal muscles, viz., internal iliac muscle and the greater psoas muscle, are found inside the false pelvis.

The *internal iliac muscle* (m. iliacus internus) is a wide muscle originating from the iliac crest, lining the iliac cavity and joining here with the greater psoas muscle.

The *greater psoas muscle* (m. psoas major) is a long muscle; it originates from the lateral surface of the 12th thoracic and four upper lumbar vertebrae, descends into the false pelvis where it joins with the inner iliac mus-

Fig. 30. Female pelvis

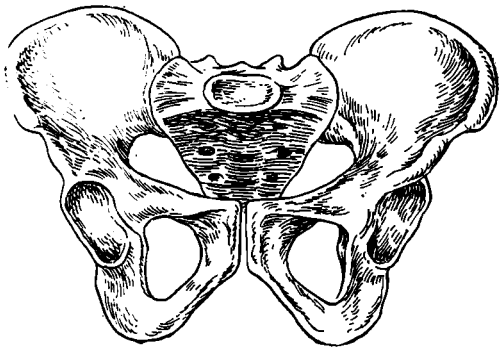

Fig. 31. Male pelvis

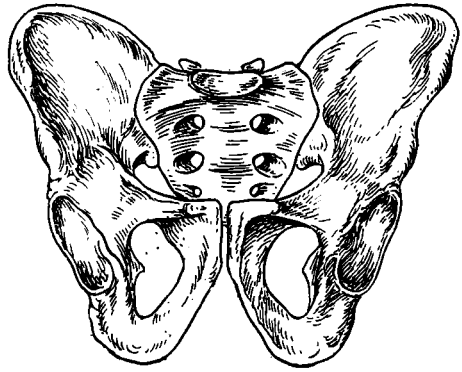

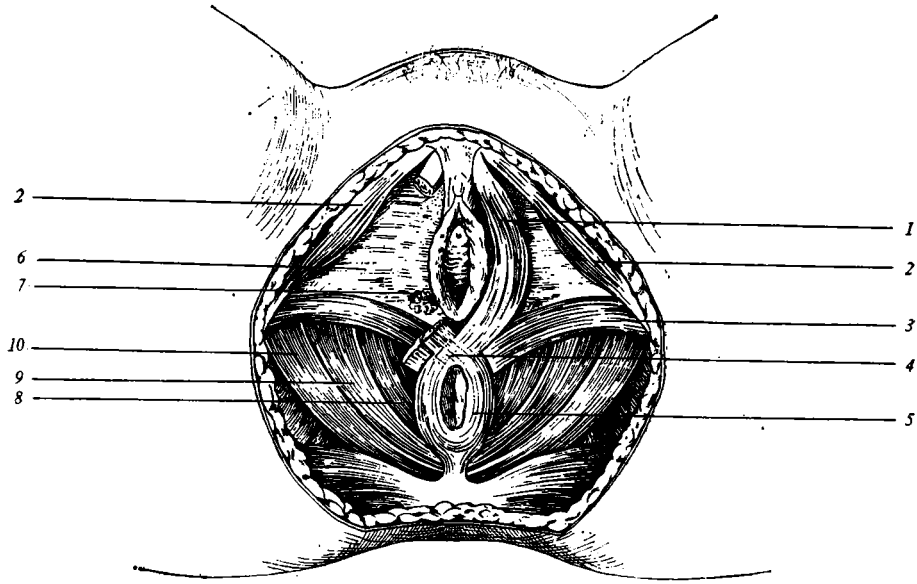

Fig. 32. Pelvic floor muscles:
1 — bulbocavernous muscle, *2* — ischiocavernous muscle, *3* — superficial transverse muscle of perineum, *4* — perineum tendon centre, *5* — sphincter ani, *6* — urogenital diaphragm, *7* — Bartholin's gland, *8* — *10* — pelvic diaphragm (m. levator ani)

cle. The two muscles now form one compound iliopsoas muscle, which passes beneath the Poupart (inguinal) ligament to the lesser trochanter of the femur.

The inlet to the small pelvis is only partly closed by the margins of the iliopsoas muscles. The parietal muscles (piriform and internal obturator muscles) line the lateral walls of the true pelvis without decreasing its capacity.

The *piriform muscle* (m. piriformis) originates from the anterior surface of the sacrum, extends in the transverse direction, leaves the pelvis through the greater sciatic foramen, and is attached to the greater trochanter of the femur.

The *internal obturator muscle* (m. obturator internus) originates from the margin of the obturator foramen, leaves the pelvis through the smaller sciatic foramen and is attached between the trochanters of the femur.

Pelvic floor. The pelvic outlet is closed with a massive muscle-fascia membrane known as the pelvic floor. Part of the pelvic floor, bounded anteriorly by the posterior commissure and posteriorly by the anus, is called the obstetric or anterior perineum (the posterior perineum is the part of the pelvic floor between the anus and the coccyx).

The pelvic floor is composed of three layers of muscles coated by fasciae (Fig. 32).

The *lower* (outer) *layer* consists of muscles meeting at the tendon centre of the perineum; the muscles are arranged in the form of an 8 suspended from the pelvic bones.

1. The bulbocavernous muscle (m.

bulbocavernosus) encircles the vestibule of the vagina; it is attached to the tendon centre of the perineum and the clitoris; as this muscle contracts it constricts the vestibule.

2. The ischiocavernous muscle (m. ischiocavernosus) originates from the inferior ramus of the ischium and is attached to the clitoris.

3. The external sphincter of anus (m. sphincter ani externus) embraces the end of the rectum. The deep muscle bundles originate from the coccyx tip, embrace the anus and terminate at the perineal centre.

4. The superficial transverse muscle of perineum (m. transversus perinei superficialis) originates from the ischial tuberosity and terminates at the centre of the perineum.

The *urogenital diaphragm* (diaphragma urogenitale) occupies the anterior portion of the pelvic outlet. This is a triangular musculomembranous layer located inferiorly to the symphysis in the pubic arch. The diaphragm surrounds the urogenital ducts (the urethra and the vagina). The muscle bundles of the anterior portion of the urogenital diaphragm surround the urethra to form its external sphincter. The posterior portion of the urogenital diaphragm contains muscular bundles extending in the transverse direction to the ischial tuberosities. This portion of the urogenital diaphragm is the deep transverse muscle of the perineum (m. transversus perinei profundus).

The *upper* (internal) *layer* of perineal muscles is called the pelvic diaphragm (diaphragma pelvis). It consists of a paired muscle which lifts up the anus (m. levator ani).

Both wide muscles raising the anus form a vault whose top is directed downward and is attached to the lower end of the rectum (slightly above the

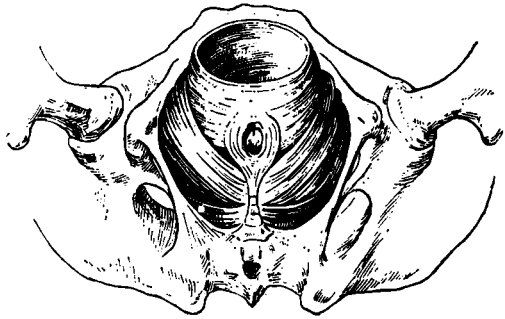

Fig. 33. Pelvic floor muscles during foetus expulsion

anus). The wide base of the vault is turned upward and attached to the inner surface of the pelvic walls. The anterior portion of the pelvic diaphragm, between the muscle bundles lifting up the anus, contains a longitudinal cleft through which passes the urethra and the vagina (hiatus genitalis). The muscles raising the anus consist of separate muscular bundles originating from various points of the pelvic walls; this is the strongest muscular layer of the pelvic musculature.

All muscles are coated in fasciae.

The muscles of the pelvic floor invested in fasciae perform the following functions:

1. The pelvic floor supports the internal genitalia and maintains them in the normal position. The muscles raising the anus are of special importance. When they contract, the pudendal cleft is closed, and the lumen of the rectum and the vagina is narrowed. Incompetence of the pelvic floor is the cause of prolapse of the genitalia, and also of the bladder and the rectum.

2. The pelvic floor is the stationary support not only to the genitalia but to the other viscera as well. The muscles of the pelvic floor, together with the diaphragm and the muscles of the

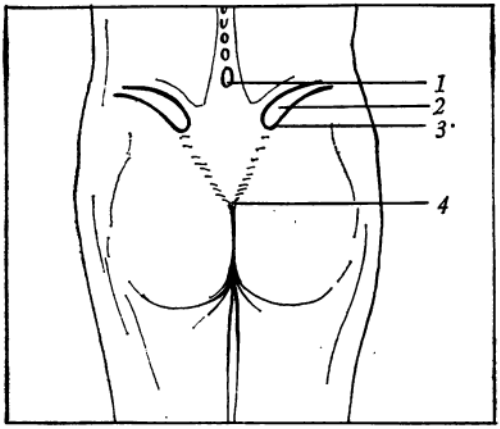

Fig. 34. Michaelis' rhomboid:
1 — spine of 5th lumbar vertebra, *2* — iliac crest, *3* — superior posterior spine, *4* — sacral tip

Fig. 35. Pelvimeter

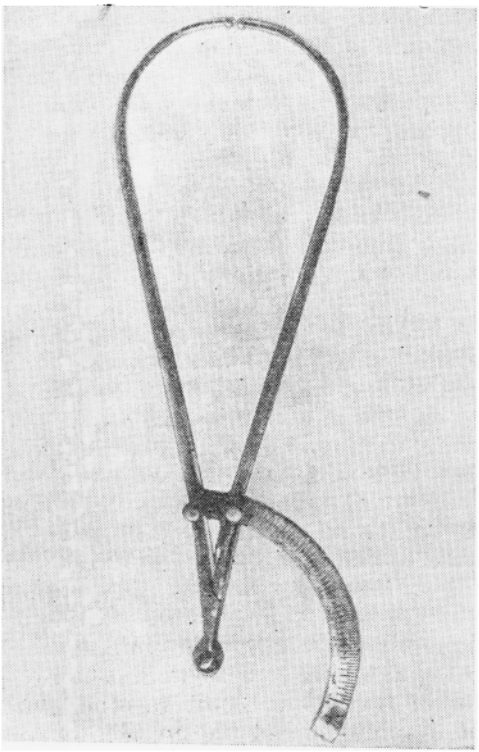

abdominal wall, are involved in the control of the intra-abdominal pressure.

3. During labour all the three layers of the pelvic musculature are distended to form a wide tube which is the continuation of the birth canal (Fig. 33). After delivery the pelvic muscles contract again to assume the initial position.

Examination and Mensuration of Pelvis

Examination of the pelvis is of great obstetrical importance since its structure and diameters have a decisive effect on the course of labour and its outcome. A normal pelvis is a prime requisite in normal delivery. Deviations in the pelvic structure, and especially small size of the pelvis, may become the cause of difficult labour or present an insuperable obstacle for normal obstetric delivery. The examination of the pelvis consists in its inspection, palpation, and mensuration.

All features of the pelvis are important but special attention should be given to the Michaelis rhomboid (Fig. 34).

The rhomboid is a diamond-shaped area on the posterior surface of the sacrum. Its upper angle is the dimple between the spine of the 5th lumbar vertebra and the beginning of the median sacral crest; the lateral angles correspond to the posterior superior spines of the ilium, while the lower angle is the apex of the sacrum. The rhomboid is bounded superiorly and posteriorly by projections of large dorsal muscles, and inferiorly and posteriorly by the projections of the gluteal muscles. The rhomboid of a normal pelvis in a well-built woman is almost

a square which is clearly seen during examination.

If the constitution and the pelvis are not normal, the rhomboid outline is indistinct and its shape is distorted.

The obstetric examination of the large pelvis includes palpation of the iliac crests and spines, the symphysis, and the trochanters of the femur. The internal examination includes palpation of the inner surface of the sacral cavity, the lateral walls of the pelvis and the symphysis, and the sacral promontory (if it is accessible to palpation). The procedure gives a tentative picture of the pelvic capacity and architecture.

Mensuration of the pelvis is very important. Once the pelvic diameters are known, the obstetrician can predict the course of labour, its possible complications, and assess feasibility of spontaneous obstetric delivery with a given pelvis.

Most pelvic diameters cannot be measured directly. The external dimensions of the pelvis are therefore first measured and a tentative judgement on the capacity and the architecture of the small pelvis is then drawn. A special tool known as a pelvimeter (Fig. 35) is used for the purpose. The pelvimeter is provided with a scale which reads pelvic diameters in centimeters. The pelvimeter arms are provided with bulbs which are placed against the points between which the distance is measured. For measuring the transverse diameter of the pelvic outlet plane a special pelvimeter with crossing arms has been devised. To measure the pelvis, the examiner stands at the right side of the woman in the supine position. The bulbs of the pelvimeter arms are held between the thumb and the forefinger. The scale of the instrument is in the upright position. The points,

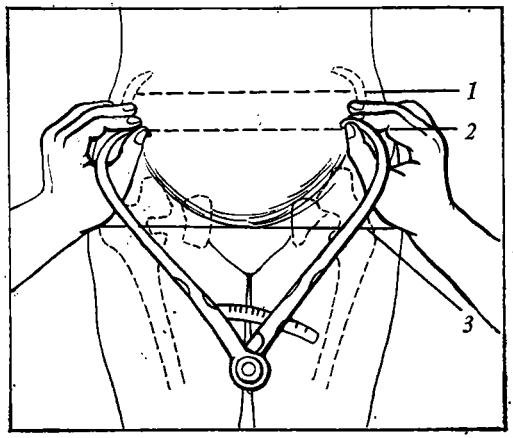

Fig. 36. Measuring transverse pelvic diameters:
1 — distantia cristarum, *2* — distantia spinarum, *3* — distantia trochanterica

between which the distance is to be measured, are palpated by the forefingers and the bulbs of the separated pelvimeter arms are pressed against these points. The diameter is now read off the scale (Fig. 36).

Four pelvic diameters are determined as a rule, viz., three transverse and one anteroposterior diameter. The three transverse diameters are as follows:

1. Distantia spinarum (interspinous distance), the distance between the anterior-superior spines of the ilium.

The bulbs are pressed against the anterior edges of the anterior-superior iliac spines. The distance is normally 25-26 cm.

2. Distantia cristarum (intercristal distance), the distance between the most remote aspects of the iliac crests. After the interspinous distance has been measured, the pelvimeter bulbs are moved along the anterior edge of the iliac bones until the tool reads the maximum measurement. This is the intercristal distance, measuring on an average 28-29 cm.

3. Distantia trochanterica, the distance between the trochanters of the femur. During taking this measurement, the woman should lie on her back with the legs extended and held together. The pelvimeter arms rest on the most prominent points of the greater trochanters. The normal distance is 30-31 cm.

Subcutaneous fat interferes with palpation of the trochanters in obese women. The location of the wanted points can be facilitated if the woman turns her feet inwardly and outwardly.

The transverse diameters are to a certain degree indicative of the size of the small pelvis. The relationship between the transverse measurements is also important. For example, the difference between the interspinous and intercristal distances is normally 3 cm. If the difference is smaller, the architecture of the pelvis is abnormal.

4. Conjugata externa (the external conjugate) is the anteroposterior diameter. The patient is placed on her side, with the lower leg flexed on the abdomen and the upper leg extended. One arm of the pelvimeter rests on the superior margin of the symphysis, and the other arm on the dimple overlying the lumbosacral junction found between the spine of the 5th lumbar vertebra and the beginning of the median sacral crest (the dimple coincides with the upper angle of the Michaelis rhomboid). The external conjugate is normally 20 cm (Fig. 37).

Fig. 37. Measuring the external conjugate

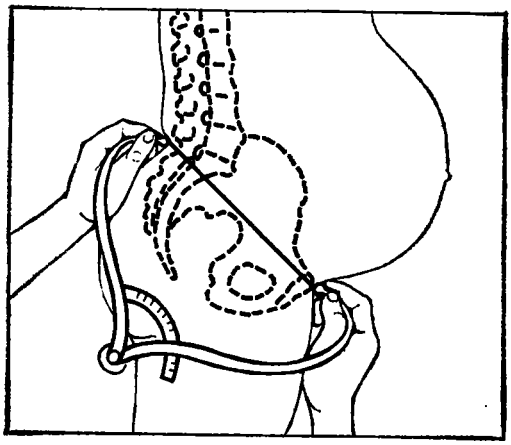

The superior margin of the symphysis pubis is easy to locate. The lumbosacral junction can be located by palpating the spines of the lumbar vertebrae (descending toward the sacrum). The dimple is easily palpated under the spine of the last lumbar vertebra.

It is difficult or even impossible to palpate the dimple in obese women. The lumbosacral junction is then situated 3-4 cm superiorly to the imaginary line connecting the lateral angles of the Michaelis rhomboid. This point corresponds to the sacral dimple upon which the pelvimeter arm should rest.

The *external conjugate is a very important measurement* since the true conjugate can be determined by subtracting 9 cm. For example, the external conjugate measures 20 cm. The true conjugate will then be 11 cm. If the external conjugate is 18 cm, the true conjugate is 9 cm, etc.

The difference between the external and the true conjugate depends on the thickness of the sacrum, the symphysis pubis, and the soft tissues. The thickness of these bones and tissues varies in women, and the difference is not therefore 9 cm in all cases.

The *true conjugate can be determined more accurately from the diagonal conjugate* (conjugata diagonalis) which is the distance between the most prominent aspect of the sacrum (promontory) and the inferior margin of the symphysis pubis. The diagonal conjugate is measured during the vaginal examination

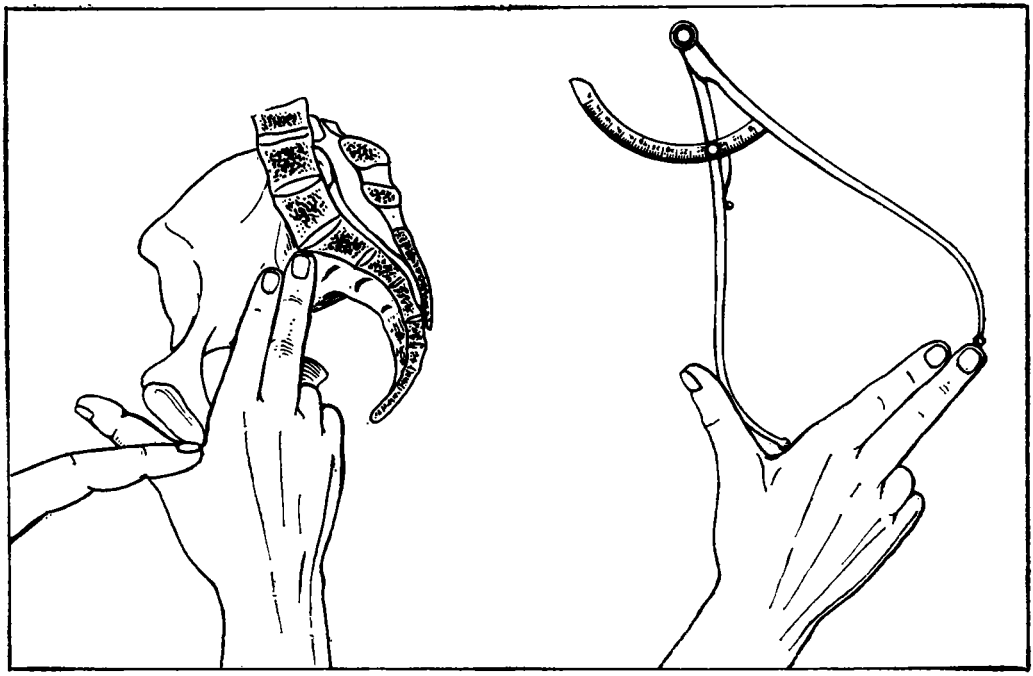

Fig. 38. Measuring the diagonal conjugate

of woman (Fig. 38) with observation of all aseptic and antiseptic rules. The index and the middle fingers of the examining hand are introduced into the vagina, with bent fourth and the little fingers resting upon the perineum. When the middle finger is felt to be touching the sacral promontory, the index finger of the other hand is used to mark the point on the examining hand where it touches the inferior margin of the symphysis pubis. After removing the hand from the vagina, the distance from the tip of the middle finger to the point where the index finger of the other hand marks the contact with the symphysis is measured. A pelvimeter or a common ruler are used for the purpose.

The diagonal conjugate is normally 12.5-13 cm long. The true conjugate is determined by subtracting 1.5-2 cm.

It is not always easy to measure the diagonal conjugate since the examiner's finger may fail to reach the promontory, or it can be palpated with difficulty. If a stretched middle finger does not reach the promontory, the capacity of the pelvis can be considered normal or nearly normal.

The transverse diameters of the pelvis and the external conjugate should be measured in all pregnant and parturient women.

If any suspicion arises that the pelvis might be narrow, the *diameters of its outlet plane* are measured (Fig. 39). The woman is placed on her back with the legs flexed on the belly and abducted (the lithotomy position). The antero-

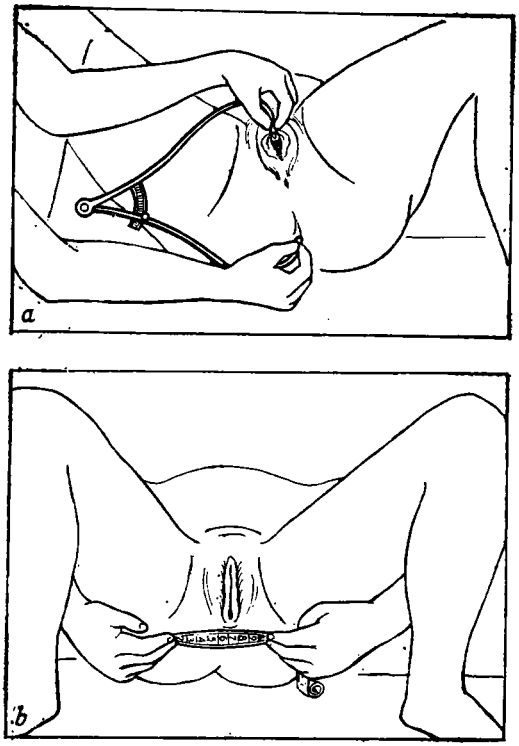

Fig. 39. Measuring the pelvic outlet:
a — measuring the anteroposterior diameter,
b — measuring the transverse diameter of pelvic outlet

Fig. 40. Outlining the pubic arch

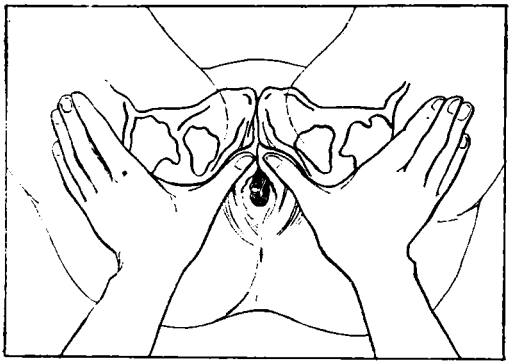

posterior diameter of the pelvic outlet plane is measured by a common pelvimeter, with one arm resting on the inferior margin of the symphysis pubis and the other arm on the coccyx tip.

The transverse diameter is measured by the tape or a pelvimeter with crossing arms. The inner surfaces of the ischial tuberosities are found by palpation, and the intervening distance (bi-ischial diameter) is measured. To introduce the correction for the thickness of soft tissues that separate the bulbs of the pelvimeter from the tuberosities, 1-1.5 cm should be added to the found value.

Outlining the pubic arch is also of certain clinical importance. The subpubic angle in a pelvis of normal size is 90-100°. Any deviation from this value will indicate abnormality of the pelvic architecture.

The pubic arch is outlined as follows. The patient is placed on her back with the legs flexed on the abdomen. The thumbs of the examiner touch against the inferior margins of the pubic and ischial bones; the tips of the thumbs should meet on the inferior surface of the symphysis pubis. The outline formed by the two thumbs gives a visual impression of the shape of the pubic arch (Fig. 40).

Oblique diameters are measured in contracted pelvis.

The following measurements are taken to reveal asymmetry of the pelvis.

1. The distance between the anterior superior spine to the posterior superior spine of the opposite side, and vice versa.

2. The distance from the superior margin of the symphysis pubis to the right and left posterior superior spines.

3. The distance from the lumbosacral

junction to the right and left anterior superior spines.

The right and left oblique diameters are then compared. They are equal in normal pelvis. If the difference between them exceeds one centimetre, the pelvis is considered asymmetrical.

Pelviradiography with subsequent measurement of anteroposterior and transverse diameters gives a complete impression of the overall volume of the small pelvis. But this method is only used where it is necessary to know exactly the pelvic architecture and the degree of contracture, and to assess the suspected cephalopelvic disproportion.

Ultrasound is also used now to measure the size of the foetus head and the pelvic diameters.

Chapter Three

FERTILIZATION. INTRAUTERINE DEVELOPMENT OF FOETUS AND FOETAL MEMBRANES

Fertilization

Fertilization is the fusion of a spermatozoon (a mature male germ) with an ovum (the female reproductive cell) into one cell which gives the start of a new organism.

The maturation of the ovum and spermatozoon is a complicate process during which the quantity of chromosomes in the nuclei of both cells is halved. The nucleus of a new cell resulting from the fertilization contains a complete set of the chromosomes.

Spermatogenesis. The spermatozoa are formed in contorted seminiferous tubules of the male sex glands. A spermatozoon comprises a head, a neck, and a long thin tail (Fig. 41). The head is the nucleus of the germ surrounded by a thin layer of cytoplasm, while the neck and the tail are cytoplasm proper.

The motility of a spermatozoon depends on the movements of its tail. The spermatozoon acquires the power of motility after it is mixed with the prostatic fluid and the secretion from the seminal vesicles. The mixture of spermatozoa and the secretion from the seminal vesicles and the prostate is the sperm or semen.

About 5-8 ml of the seminal fluid are ejaculated into the vagina during coitus. This portion contains 200-500 million spermatozoa. The semen is mainly accumulated in the posterior fornix into which the cervical portion of the uterus is projected. The external os of the endocervical canal is bathed in the sperm accumulated in the posterior fornix which provides favourable conditions for fertilization.

During sexual excitement, the uterine muscles are contracted to open the external os of the cervix slightly. The mucous stopper of the cervix is protruded into the semen deposited in the posterior fornix during copulation. After coitus, the mucous stopper is pulled back into the cervix together with the spermatozoa.

The main condition for penetration of the spermatozoa into the uterus is however their own motility. The vagina reacts acid and the spermatozoa move toward the uterine cervix where the reaction is alkaline and favourable to their reproductive function. The alkalinity of the uterus and the fallopian tubes maintains the reproductive potential of spermatozoa and their motility for a few days.

Spermatozoa travel at a rate of 3-3.5 mm per min. In 60-90 minutes they can be found in the uterus cavity, and in two or three hours in the fallopian tubes where they meet the ovum.

Fertilization usually occurs at the ampullar portion of the tubes.

The ovum cannot move by itself. With the rupture of a mature follicle, the ovum, surrounded by the radiating crown, is washed by the escaping fluid

into the abdominal cavity and further into the fallopian tube.

The peristaltic activity of the tube and the motion of its ciliated lining induce a current of fluid which entraps the ovum and propells it from the infundibulum to the uterine end of the tube.

In the opinion of K. K. Skrobansky, the propulsion of the ovum into the tube is aided by the reflectory contraction of the abdominal prelum occurring during ovulation.

Many million spermatozoa travel to the ampullar portion of the tube to meet the ovum. Some of them will gain entrance into the ovum through a tubercle on its surface (Fig. 42).

There are only few out of millions that will pass the transparent membrane (zona pellucida) and get into the protoplasm of the ovum. Their penetration is facilitated by hyaluronidase, the enzyme produced by the spermatozoa, which dissolves the transparent membrane of the ovum, mucinase, the trypsin-like enzyme, etc.

All other spermatozoa die, disintegrate, and are absorbed in the tube lining.

Of the few spermatozoa, which found their way into the ovum, only one fertilizes the egg. Its nucleus moves toward the nucleus of the ovum and fuses with it. This is fertilization, or the onset of pregnancy.



Fig. 41. Spermatozoa

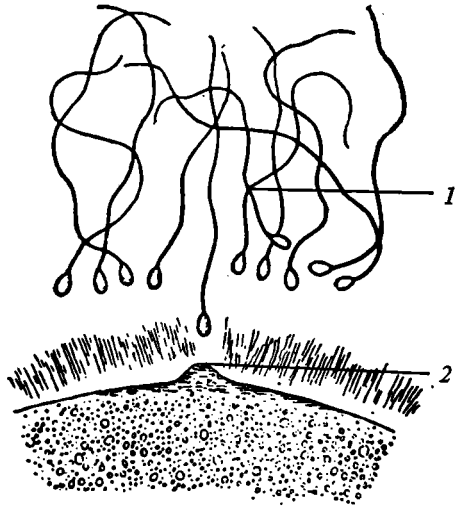

Fig. 42. Entrance of the spermatozoa into the ovum:
1 — spermatozoa, *2* — protuberance formed at the site of expected entrance of the spermatozoon

Division and Passage of the Fertilized Ovum into the Uterus

A fertilized egg is characterized by an intensified metabolism. The fusion of the nuclei is followed immediately by the division process (Fig. 43). The karyokinetic division first gives two daughter cells, blastomeres, which undergo further division. The rapid division of the blastomeres results in cell accumulation (morula) resembling mulberry in appearance.

The dividing ovum moves along the tube to enter the cavity of the uterus in 8-10 days following the fertilization. The ovum is mainly transported by the rhythmic peristalsis of the tube musculature. The fibrillation of the cilia is only of secondary importance.

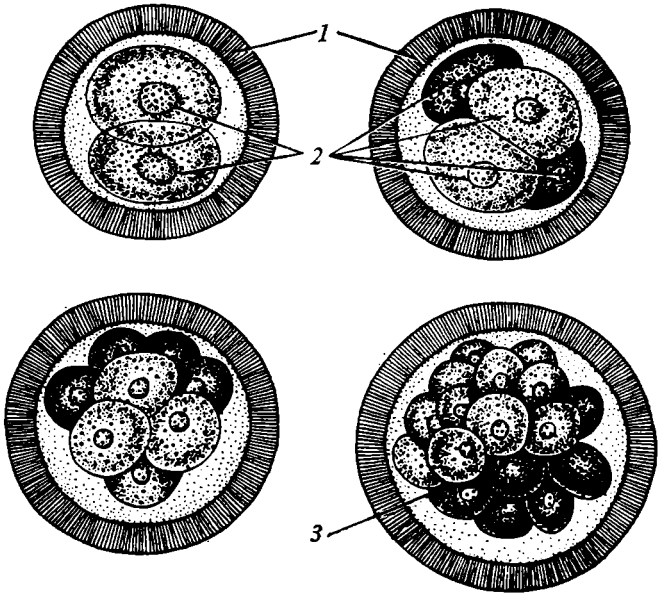

Fig. 43. Division of a fertilized ovum and formation of morula:
1 — zona pellucida, *2* — blastomeres, *3* — morular stage

Implantation

Qualitative changes also take place in a fertilized ovum along with the mitosis. When in the fallopian tube, the fertilized egg is separated from its transparent coat (zona pellucida). By the moment the ovum enters the uterus, the outer layer of the morula cells is converted into the trophoblast, and the inner cells into the embryoblast. The embryoblast develops into the embryo.

The trophoblast is a layer of tissue which attaches the ovum to the uterine wall and supplies nutrition to the embryo developing from the embryoblast.

The cells of trophoblast secrete enzyme-like substances which dissolve the tissues of the uterine mucosa. As the ovum sets on the superficial layer of the endometrium (normally on the anterior or posterior wall, at the level of insertion of the tubes), its trophoblast dissolves the epithelial lining, the glands, the stromal cells and the vessels of the uterine mucosa and is gradually embedded into the functional layer of the endometrium (Fig. 44). When the ovum is completely embedded into the mucosa, the site of entrance becomes sealed. This moment is assumed to mark the completion of the implantation process (Fig. 45).

The endometrium is at this moment at its secretory phase and contains substances necessary for the nutrition of the embryo.

When the uterine mucosa is dissolved by the trophoblast, the tissues around the settled ovum disintegrate to give nutrition to the embryo (embryotroph). The embryotroph contains proteins, carbohydrates, fats, vitamins, salts and other substances necessary for the nutrition and growth of the embryo.

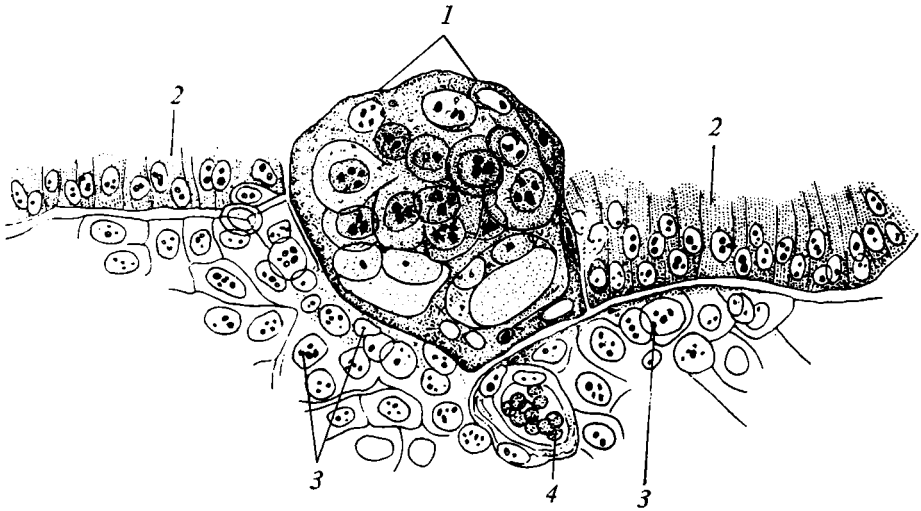

Fig. 44. Initial stage of implantation of the ovum into the endometrium:
1 — dividing ovum, *2* — columnar epithelium of the endometrium, *3* — decidual cells, *4* — blood vessel

Fig. 45. The final stage of implantation: *1* — mesoblast, *2* — ectoblastic vesicle, *3* — entoblastic vesicle, *4* — trophoblast (cytotrophoblast), *5* — syncytium, *6* — disintegrating cells of the endometrium, *7* — decidual membrane, *8* — the healed site of the ovum implantation

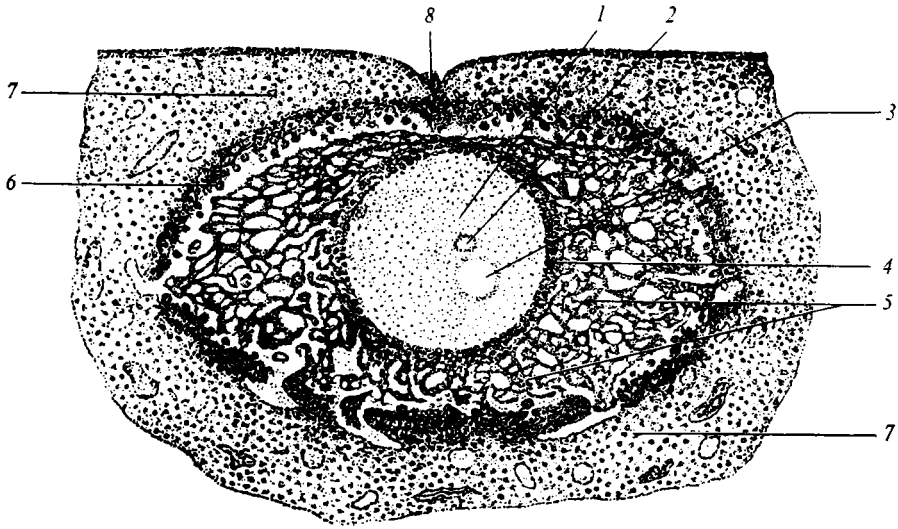



Fig. 46. Early stages of trophoblast and embryoblast development:
1 — primary villi, *2* — primary intervillous space, *3* — ectoblastic vesicle, *4* — stalk, *5* — entoblastic vesicle, *6* — decidual cells, *7* — embryonal germ, *8* — mesoblast

Development of Foetal Membranes

Following the implantation, the ovum rapidly grows. Projections (villi) are formed on the trophoblast. At this stage they have no blood vessels and are actually *primordial villi* (Fig. 46). The outer coat of the ovum is now called the *chorion*. Tissues between the villi and the endometrium disintegrate and the maternal blood starts circulating. The space between the chorionic villi and the surrounding endometrium is the primary intervillous space, which surrounds the entire ovum. At later terms the intervillous space remains only in the region of the placenta and is called the secondary intervillous space.

Along with the trophoblast, the inner cells of the ovum, embryoblast, develop as well. The development of the embryoblast begins when the ovum is in the tube. Cavities filled with fluid are formed in the middle of the embryoblast, which are then fused into one cavity, exocoelom, and the ovum transforms into the blastocyst. The cells surrounding the blastocyst cavity form the mesoblast.

Cells accumulate in one segment of the blastocyst. Two nodules can be distinguished in this accumulation, the ectoblast and the entoblast. Cavities are soon formed in the centres of these nodules and the ectoblast turns into the ectoblastic vesicle and the entoblast into the entoblastic vesicle (Fig. 46). The ectoblastic vesicle is connected through a stalk with the trophoblast which then forms the amniotic cavity. The wall of this cavity turns into a *fluid sac*, the *amnion*. The entoblastic vesicle is situated closer to the centre. Later it develops into the *yolk sac*.

The ectoblast and entoblast cells situated between the amnion and yolk sac form the *embryo*.

The size of the exocoelom cavity increases and the mesenchymal cells are displaced toward the chorion (trophoblast), the amnion, yolk sac, and the embryo in between them. The walls of the vesicles and the chorion become double layered. The embryo is composed of three layers, viz., the ectoderm, mesoderm, and entoderm. All tissues and organs of the foetus develop from these three layers.

The amnion rapidly increases in size due to the accumulation of a clear fluid in the sac, while its wall (the amnion proper) moves toward the villous membrane and becomes attached to it. The blastocyst cavity (exocoelom) disappears. The embryo, which was situated between the amnion and the

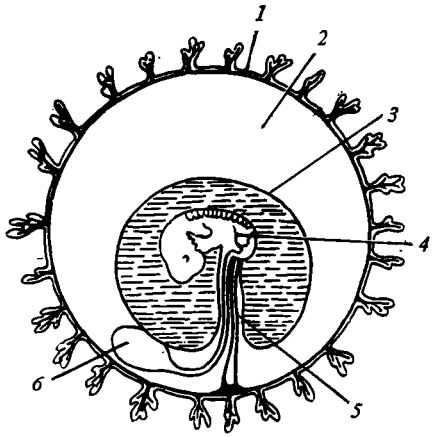

g. 47. Formation of membranes:
— chorion, *2* — exocoelom, *3* — amnion, *4*— embryo, *5* — allantois with the stalk, *6* — lk sac

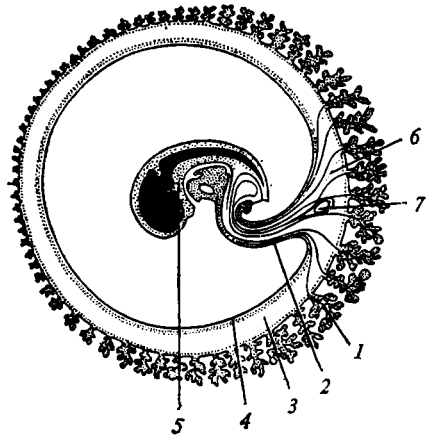

Fig. 48. Later stage of formation of membranes:
1 — chorion, *2* — developing umbilicus, *3* — exocoelom, *4* — amnion, *5* — embryo, *6* — allantois, *7* — remnants of the yolk sac

lk sac starts screwing into the amnion vity and is gradually completely emded into it (Fig. 47). As the amtic cavity increases in size, the yolk decreases and disintegrates (Figs. 47 d 48).

Coincident with the development of membranes, allantois is formed m the hind-gut of the embryo. The ntois extends to the villous memne along the stalk that connects amniotic vesicle with the trophost (Figs. 47 and 48). The allantois ests vessels that course from the bryo body to the villous chorion. vessels grow into each villus of chorion (Fig. 48). At this stage the ntoic blood circulation of the em is started.

As soon as the initial stages of the bryo growth have been completed, foetus becomes surrounded by the otic fluid and three membranes, ely the decidual membrane, the on and the amnion. The decidual brane is maternal (it is formed from the endometrium) while the chorion and the amnion belong to the foetus.

The **decidual membrane** is the functional layer of the endometrium which is modified during pregnancy. After parturition the decidua is expelled from the uterus together with the other membranes and the placenta. Hence the name 'decidual' (thrown off) membrane.

By the moment of implantation, the uterine mucosa is at the secretory phase: the glands are filled with the secretion, the stromal cells become rounded and contain glycogen, and the functional layer of the endometrium becomes delineated into the spongiosa and compacta layers (Fig. 49). The spongiosa layer mainly consists of glands, while the compacta layer consists of rounded stromal (decidual) cells (Fig. 50) between which the excretory glandular ducts pass. After the ovum has been implanted, the endometrium thickens, becomes engorged, the glands become

Fig. 49. Decidual membrane of three month's gestational age:
1 — muscular layer, *2* — basal layer of mucosa; endometrium, *3* — spongiosa layer, *4* — compacta layer

more filled with the secretion, the stromal cells become enlarged, and the amount of glycogen in them increases. These modified stromal cells are called the decidual cells of pregnancy.

The ovum embedded in the compacta layer is surrounded by the decidual membrane. Depending on the part of the ovum to which the decidual membrane is adjacent, it is subdivided into the following (Fig. 51):

(1) the capsular decidua (decidua capsularis), the portion of the decidual membrane overlying the ovum on the side of the uterine cavity;

(2) the basal decidua (decidua basalis), the underlying portion of the membrane found between the ovum and the uterine wall;

(3) the parietal decidua (decidua parietalis), the portion of the decidua lining the uterus elsewhere than at the site of the ovum attachment.

As the ovum grows, the capsular and the parietal decidua are stretched, thinned, and become closer to each other. A human ovum of four months' gestational age occupies the entire cavity of the uterus. The two portions of the decidua fuse into one and become even thinner, while the basal decidua, on the contrary, thickens and many vessels develop in it. This portion of the mucous lining turns into the maternal placenta.

The **chorion** develops from the trophoblast and the mesoblast. The primary villi have no vessels, but by the end of the first month of pregnancy, the vessels grow into them from the allantois.

The villi first cover uniformly the entire surface of the ovum. At the second month of pregnancy the villi of the chorion portion adjacent to the capsular decidua become atrophied. At the third month of pregnancy the villi disappear from this portion of the chorion and it becomes smooth (chorion laeve). On the opposite side of the chorion (which is adjacent to the basal decidua), the villi develop into vascular processes (chorion frondosum) (Fig. 52). This portion will later form the embryonic portion of the placenta.

The **amnion.** This is a membranous sac containing the foetus surrounded by the amniotic fluid. The amnion is adjacent to the chorion; it lines the inner surface of the placenta, passes

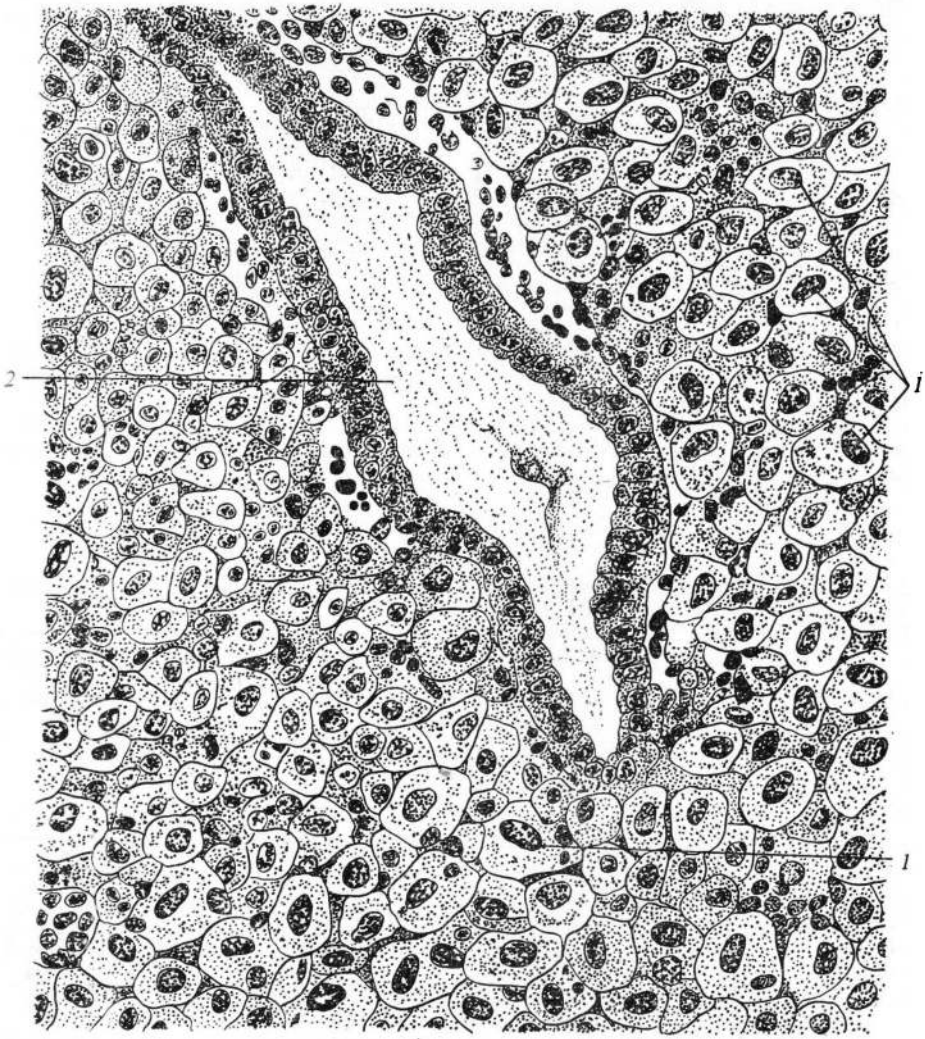

Fig. 50. Compacta layer of decidual membrane:
1 — decidual cells, 2 — gland

onto the umbilical vesicle to cover it as if with a case, and fuses with the outer coats of the foetus at the umbilical region. The amnion is a thin membrane which comprises the epithelium and connective tissue cells formed by the mesenchyma.

The innermost membrane, which is the closest to the foetus, is the amnion. Next follows the chorion, and finally the decidual membrane (Fig. 53).

The **amniotic fluid.** The amnion cavity is filled with fluid whose amount by the end of pregnancy is 1-1.5 l.

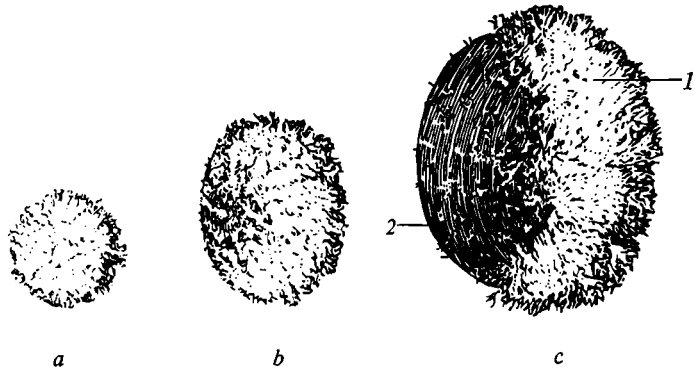

Fig. 51. Chorion development:
a — ovum of one month's gestational age (uniform growth of villi), *b* — chorion of two months' gestational age, *c* — chorion of three months' gestational age; *1* — chorion frondosum, *2* — chorion laeve

Fig. 52. Portions of the decidual membrane: *1* — decidua parietalis, *2* — decidua capsularis, *3* — decidua basalis, *4* — chorion frondosum, *5* — chorion laeve, *6* — amnion

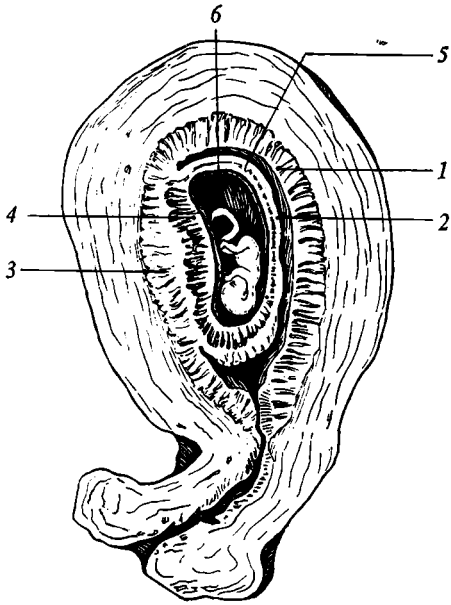

Fig. 53. Arrangement of the membranes in the uterus:
1 — chorion laeve, *2* — amnion, *3* — fused decidua capsularis and decidua parietalis, *4* — amnion cavity, *5* — umbilicus, *6* — decidua basalis, *7* — chorion frondosum

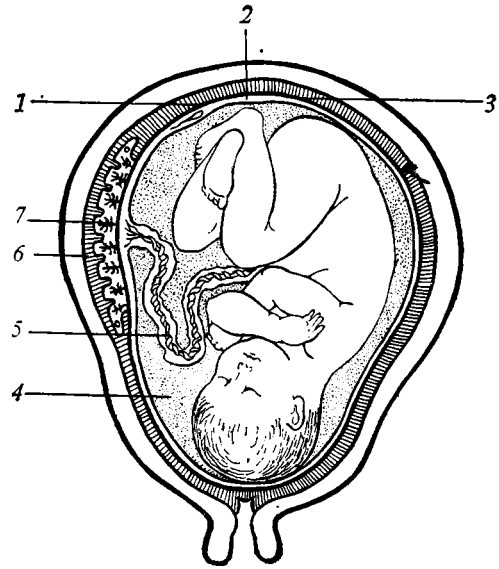

Fig. 54. Villi of term placenta

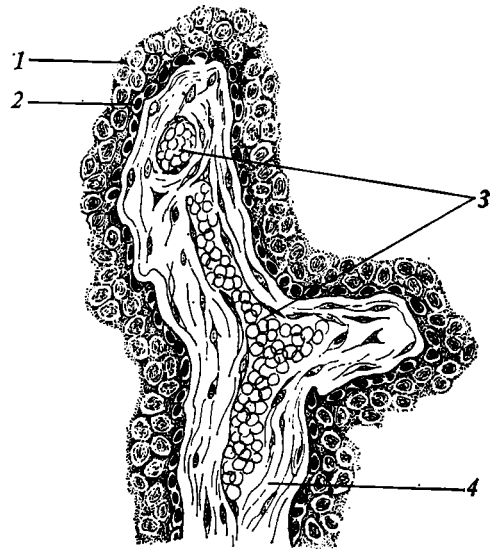

Fig. 55. Microscopic structure of the villus: *1* — syncytium, *2* — cytotrophoblast, *3* — blood vessels, *4* — embryonal connective tissue

The fluid is formed by secretion from the amnion epithelium. Part of the fluid is possibly formed by sweating out of the blood from the maternal vessels and as a result of the functioning of the foetal kidneys. The fluid is mixed with scaling off epidermis, the products of the sebaceous glands of the skin and the fine hair of the foetus body (lanugo).

The amniotic fluid contains protein, salts, urea, fat, sugar, hormones (folliculin, gonadotropic hormone), microelements, etc.

It has great physiological importance:

(1) the amniotic fluid provides conditions for favourable growth of the foetus, and its movement inside the uterus; unsufficient amounts of the fluid (oligohydramnios) can be the cause of congenital abnormalities of the foetus; the amniotic fluid is involved in the foetal metabolism;

(2) the fluid protects the delicate foetus from unfavourable external effects;

(3) the amniotic fluid precludes the umbilical compression between the foetus body and the uterine wall (the compression can cause foetal death);

(4) the amniotic fluid contained in the foetal membrane promotes normal dilation of the cervical os (effacement).

Placenta

The placenta is a very important organ through which the foetus breathes, obtains nutrition and gets rid of the metabolites. The placenta thus performs the functions of the lungs, the alimentary and digestive tract, the kidneys, the skin, and other organs.

The gonadotropic hormones, oestrogens, and progesterone are produced by the placenta. It also contains hy-

drocortisone, the growth hormone, the adrenocorticotropic and other hormones.

The placental tissue contains proteins, carbohydrates, lipids, phosphatides, vitamins, microelements, iron and other substances.

The placenta is formed from the basal decidua and strongly developed chorionic villi. The villi, which are the main mass of the placenta, are intensely ramifying tree-like formations (Fig. 54). The vessels invested in the large villi also ramify and enter newly formed villi; the terminal villi contain only capillary loops. The villus surface is coated by two layers of epithelium. The outermost coat consists of a protoplasmic mass (having no cell coats) containing nuclei; this layer is known as syncytium (Fig. 55). It has the power to dissolve the cells and vessels of the decidual membrane. Underlying the syncytium is cytotrophoblast (the Langhans cells).

Some villi grow into the basal decidua, dissolve the decidual cells and destroy large vessels. These villi intercommunicate the maternal and the foetal portions of the placenta (anchoring villi). Many fine villi end freely and are washed with the blood circulating in the intervillous space. The blood washing the villi is derived from the vessels of the maternal placenta destroyed by the syncytium (Plates 1, 2).

The maternal blood washing the villi does not clot; nor does it mix with the foetal blood flowing in the vessels inside the villi. A permanent exchange is established between the maternal blood washing the villi and the blood flowing in the vessels of the villi themselves. The foetus obtains oxygen and nutrition from the maternal blood, while the metabolites and carbon dioxide are excreted from the foetus body into the maternal blood.

In appearance the placenta resembles a thick oval cake (from Latin *placentas*, a flat cake). At the end of pregnancy, and by the moment of delivery, the diameter of the placenta is 15-18 cm; its thickness is 2-3 cm and the weight, 500-600 g. The placenta has two surfaces, the maternal, adjacent to the uterine wall, and the foetal, facing inward into the amnion cavity (Fig. 56). The foetal surface is lined with a smooth lustrous membrane under which are found chorionic vessels leading in the radial direction from the point of the umbilical attachment to the placental periphery.

The greyish-red uterine surface of the placenta is divided by more or less deep sulci into lobes (the cotyledons). The greyish colour of the maternal surface is due to thin decidual membrane overlying the propagated villi which constitute the main bulk of the placenta. The placenta is normally attached to the upper portion of the uterus, to its anterior or posterior wall; in rare cases it can be attached to the fundus of the uterus or in the region of insertion of the tubes.

Umbilicus

The umbilical cord (funiculus umbilicalis) is formed from the allantois carrying the vessels from the foetus to the chorion and passing the abdominal stalk; the umbilical primordium also comprises the remnants of the yolk sac.

The umbilicus is a cord-like formation containing two arteries and one vein which carry blood from the foetus to the placenta and back. The umbilical arteries carry venous blood from the foetus to the placenta, and the vein

supplies the foetus with the arterial blood enriched with oxygen in the placenta. The umbilical vessels are surrounded by Wharton's jelly, a substance containing embryonal connective-tissue cells. The umbilical vessels are coiled and the entire cord looks as if twisted. The umbilicus is coated on the outside with a thin membrane which is continuous with the amnion. The umbilical cord connects the foetus with the placenta. Its one end is attached to the umbilical portion of the foetus, while the other to the placenta. The umbilicus may be attached at the centre of the placenta (the central attachment), to the sides of the placenta (the lateral attachment) or to its edge (the marginal attachment). In rare cases the umbilical cord is attached to the membranes before it reaches the placenta (the membranous attachment). The umbilical vessels pass between the membranes in this case.

The length and width of the umbilical cord vary with age of the foetus. The length normally equals the length of the intrauterine foetus. At term it normally measures 50 cm; its diameter is about 1.5 cm. But it can often be longer (60-80 cm) or shorter (35-40 cm). Its thickness varies depending on the amount of Wharton's jelly.

The afterbirth comprises the following: (1) the placenta; (2) the umbilical cord; (3) the amnion, the chorion, and the decidua. The afterbirth is expelled from the uterus following parturition.

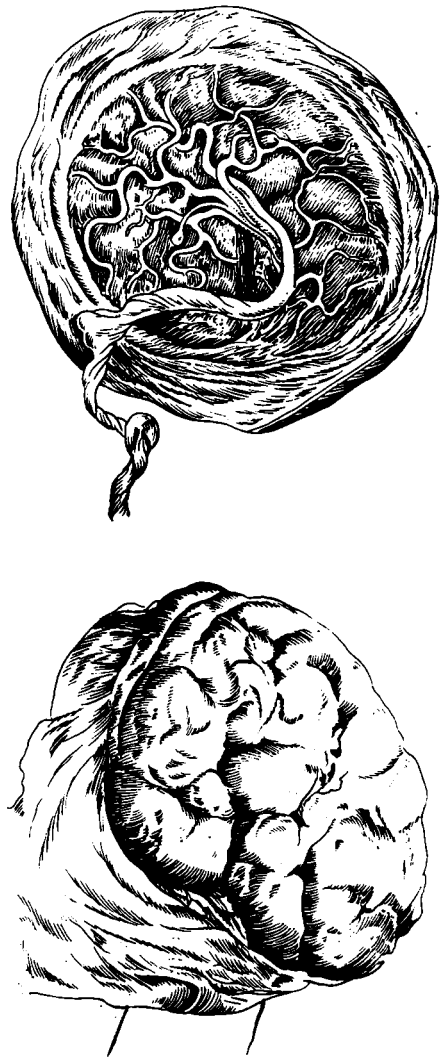

b

Fig. 56. Placenta:
a — foetal surface, *b* — maternal surface

Development of Foetal Systems

The **nervous system.** The primordial brain is formed during the early stages of the embryonal growth. Its development is rapid. The elements of the reflex arch have been found in the embryo at the second month of the intrauterine growth. The motor reflexes induced by the stimulation of the neuromuscular apparatus have been observed in a 2-3 month foetus. Reflexes of the

skin, mucous membranes, the tendons, etc., have been observed in foetuses of the second to fifth months of gestational age. The spinal cord is formed by the fifth month of the intrauterine growth. The cerebral gyri complete their development by the sixth or seventh month of the foetal growth, but their functioning begins mainly after birth. The most important functions of the foetus are controlled during the intrauterine period of growth by the spinal cord and the other parts of the central nervous system found below the cerebral cortex.

The **haematopoietic system.** The elements of the foetal blood first originate in the wall of the yolk sac. The main haematopoietic centre of the foetus of the second and third months of the gestational age is the liver, and from the end of the third month, the bone marrow. The haematopoietic function of the spleen initiates from the fourth month of the intrauterine life (E. V. Kravkova).

The formed elements and the haemoglobin of blood are deficient at early stages of the foetal growth. The erythrocytes are mainly nucleated. The amount of erythrocytes, haemoglobin and leucocytes in the peripheral blood increases with the foetal age.

The erythrocytes and haemoglobin counts of a mature foetus are higher than in adults. This facilitates oxygen supply to the foetus. The quantity of leucocytes in a foetus is lower than in adults. The main fractions of proteins of the serum and the blood coagulating system are formed during the second half of the intrauterine life.

The glands of the internal secretion also develop during the intrauterine period; the pituitary, thyroid and adrenal glands start functioning in the foetus. Primordial follicles begin growing in the ovaries but they undergo back development without having grown to a significant stage.

Blood circulation. The foetus heart begins contracting on the second week of the intrauterine life, i.e. soon after the implantation. The circulatory function can be divided into several stages.

The nutrition is supplied to the embryo immediately after the implantation through the trophoblast from the disintegrating tissues surrounding the egg. Vessels and blood elements are formed in the wall of the yolk sac during the second week of gestation, and the vitelline circulation is thus started. By the end of the first month of pregnancy the allantoic vessels enter the chorionic villi to initiate the allantoic circulation. The placenta is formed during the third month of pregnancy and the allantoic circulation is replaced by the placental one.

The intrauterine foetus obtains nutrition and oxygen from the maternal blood through the placenta. The foetal circulation has therefore its own features (Plate 3). The foetal blood enriched with oxygen and nutrients in the placenta enters the foetus body through the umbilical vein. After entering the foetus abdomen through the umbilical ring the umbilical vein ramifies into the liver, and passes to the inferior vena cava into which it empties the arterial blood. The arterial blood is mixed in the inferior vena cava with the venous blood delivered from the lower portion of the foetus body and the internal organs. The portion of the umbilical vein extending from the umbilical ring to the inferior vena cava is called the Arantius duct (ductus venosus).

From the inferior vena cava the blood enters the right atrium into which

also empties the superior vena cava.

The eustachian valve prevents mixing of the blood from the inferior and superior venae cavae. The valve directs the blood flow of the inferior vena cava from the right atrium to the left atrium through the oval foramen situated between the two atria. The blood from the left atrium is delivered into the left ventricle, and from the ventricle into the aorta. The blood of the ascending aorta, which contains comparatively much oxygen, passes to the vessels supplying blood to the head and the upper part of the foetus body.

Venous blood delivered into the right atrium from the superior vena cava is passed into the right ventricle and further into the pulmonary arteries.

Only a small part of the blood from the pulmonary arteries passes into the non-functioning lungs, the main bulk being discharged into the descending aorta through the ductus arteriosus (Botallo's duct). The blood of the descending aorta containing considerable amount of the venous blood supplies the lower portion of the body and the lower extremities of the foetus. Oxygen-depleted blood of the foetus passes to the umbilical arteries (branches of the iliac arteries) and further to the placenta where the blood is enriched with oxygen and nutrition, separated from carbon dioxide and the metabolites, and returned into the foetus through the umbilical vein.

Thus only the umbilical vein, the ductus venosus, and the hepatic branches carry purely arterial blood. The inferior vena cava and the ascending aorta carry mixed blood, but it contains more oxygen than the blood of the descending aorta. The upper portion of the foetus and its liver are better supplied with the arterial blood than the lower portion of the body. As a result, the liver of the foetus is large and the upper portion of the body develops faster than the lower one during the first half of pregnancy.

The oval foramen narrows, the eustachian valve diminishes with the growth of the foetus, and the arterial blood is now more evenly distributed in the foetus to level the development of the upper and the lower portions of its body.

Immediately after birth the foetus takes its first breath and this initiates the pulmonary respiration and the extrauterine blood circulation (Plate 4).

The mechanism of the first breath is complicated. The placental circulation discontinues with the birth of the infant. The oxygen supply to the foetus is now stopped and carbon dioxide accumulates in the infant body to stimulate the respiratory centre. As a result the newborn takes the first breath. Reflectory reactions arising in response to thermal, tactile and other stimuli applied to the skin receptors of the newborn also have their effect on the onset of the extrauterine respiration.

As the newborn respires, the pulmonary alveoli are unfolded and the blood is supplied to the lungs. The lungs are now supplied with blood through the pulmonary arteries, whereas the ductus arteriosus and the ductus venosus stop functioning.

The neonate blood enriched with oxygen in the lungs passes along the pulmonary veins into the left atrium, then into the left ventricle and into the aorta; the oval foramen between the atria is closed to initiate the extrauterine circulation.

Respiratory system. The respiratory organs do not function till the moment of birth, when the newborn makes its first respiratory movement.

It was established in the past century (Ahlfeld) that the superficial respiratory movements occur in the intrauterine foetus. The amniotic fluid penetrates the nasopharynx and is immediately expelled from it. During these respiratory movements the fluid does not travel far inside the foetus because the rima glottidis is closed. The respiratory movements create rarefaction inside the foetal chest which intensifies the foetal circulation (I. A. Arshavsky).

The foetus is supplied with oxygen through the placenta. The oxygen of the maternal blood circulating in the intervillous space of the placenta passes into the foetal blood through the villi; carbon dioxide is removed from the foetus into the maternal blood. The exchange of gases between the foetus and the mother is effected by diffusion through epithelium and the stroma of the villi and the endothelium of the foetal capillaries.

The foetus develops rapidly, its metabolism is intense, and the oxygen demands are high.

If the oxygen supply through the placenta is insufficient, hypoxia develops which inhibits the intrauterine growth of the foetus and can become the cause of its death. The causes interfering with normal oxygen supply can often induce accumulation of carbon dioxide in the foetal blood; intrauterine asphyxia develops during which the foetus suffers from lack of oxygen and excess carbon dioxide. Should the cause of asphyxia be not removed, the foetus dies.

Gas metabolism of the foetus can be disturbed during some diseases of the mother or in various changes in the placenta and the umbilicus. Anaemia, diseases of the heart and lungs, fever, toxicosis of pregnancy and other diseases of the mother can result in inadequate oxygen transport to the foetus. Hypoxia can also develop due to the decrease in the surface of the placental exchange between the foetus and the mother. This can be due to significant bleeding and anaemic infarcts (areas of necrotic placental tissue). Haemorrhage and infarct often develop in the placenta during toxicosis of pregnancy, diseases of the kidneys and of the cardiovascular system of the mother.

Gas exchange becomes impaired in premature separation of the placenta from the uterine wall. The larger the area across which the placenta is separated, the greater the disturbances in the gas exchange of the foetus. If half the total maternal floor is affected by infarct or is separated, the foetus is lost.

In pathological labour (protracted labour, frequent pains, lengthy dry period) the foetus is affected by asphyxia because of the disturbed uteroplacental circulation.

Oxygen transport to the foetus and withdrawal of carbon dioxide from it are often disordered in affected blood circulation in the umbilical cord. This can be due to true umbilical knots, entanglement of the umbilical cord, compression of the umbilicus between the birth canal and the foetus.

The umbilical vessels are highly sensitive: cooling, compression, and even slighter mechanical effects can cause contraction of the lumen in the vessels and affect blood circulation and gas exchange.

Nutrition of the foetus. The glandular function of the digestive organs begins during the intrauterine period of life. The liver synthesizes glycogen and produces bile at the fourth and fifth months of gestation; primary faeces (meconium) are formed in the intes-

tine of the foetus. Meconium consists of amniotic fluid, bile, swallowed lanugo, epidermic scales, and the secretion of the sebaceous glands of the foetal skin. It is a thick yellowish mucilagenous material in appearance. Intestinal enzymes have been found in the gastrointestinal tract.

The digestive function of the foetus is however performed by the placenta. The nutritive substances are delivered to the foetus from the mother through the placenta. The placenta produces the enzymes which split the nutrients. Proteins, fats, and carbohydrates of the maternal blood are captured by the placental villi and undergo complicated enzymatic treatment to pass to the foetus in the form suitable for assimilation. Some products of cleavage of proteins and carbohydrates (amino acids, glucose) and also mineral salts and water penetrate the placenta by diffusion. Vitamins required for the growth and vital functions of the developing foetus are delivered to it through the placenta as well.

Thus, the growth of the foetus depends entirely upon the nutrition which passes to it from the mother. The rational diet of the pregnant is therefore very important for both the expectant mother and the foetus.

Inadequate nutrition can become the cause of defective growth of the foetus and its death. Defective intrauterine development of the foetus and abortion can also be the result of hypovitaminosis of the pregnant.

Excretory function of the foetus. The metabolites (degraded proteins, fats, and carbohydrates) are discarded by the foetus into the maternal blood through the placenta; the blood of the mother is purified from these metabolites through the excretory function of her organs, in the first instance by her kidneys. The renal function of the foetus begins at the sixth or seventh month of pregnancy; it is however insignificant during this period. Some authors suggest that the foetus excretes a small amount of urine into the amniotic fluid at the end of its intrauterine life. Immediately upon delivery, the neonates, even premature, release the urine.

The hormones required for the normal intrauterine growth of the foetus, but which are not produced by the foetus itself, are supplied from the mother through the placenta. When the internal secretion organs start functioning, the hormones produced by the foetus pass to the mother through the placenta. It has been established that foetal insulin (the hormone produced by the pancreas) passes to the mother suffering from diabetes mellitus and sometimes relieves her malady.

The placenta is permeable to many chemical agents. Mercury, arsenic, phosphorus, iodine, bromine, copper, carbon monoxide, chloroform, ether, alcohol, nicotine, morphine, quinine, atropine, chloral hydrate, antibiotics, sulpha drugs, cardiac preparations and other substances pass to the foetus from the mother.

Many of these substances are poisons to the foetus, though their amounts might be small (morphine, alcohol, nicotine, mercury, arsenic, etc.). This should be remembered by the obstetrician when giving prenatal instructions to the pregnant.

The placenta is normally an insurpassable barrier to microorganisms, but some pathogenic microbes, including those causing infectious diseases, can penetrate the placenta, especially when it is affected by some pathology (the dystrophy of the epithelial villi or their defects, infarcts, bleeding).

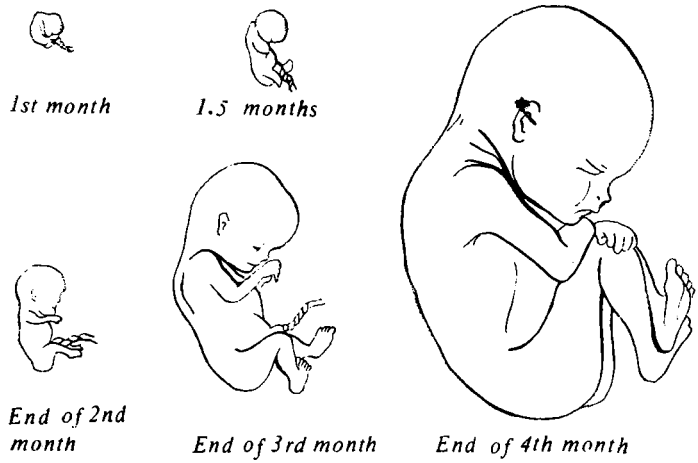

Fig. 57. The human embryo at various stages of its intrauterine development

Viruses that cause influenza, measles, rubella and other diseases can penetrate the placenta and infect the foetus. These viruses can become the cause of defective growth of the foetus, its death, and hence abortion.

Intrauterine Growth of the Foetus

Pregnancy normally continues for 280 days, or ten lunar (obstetrical) months, or forty weeks counting from the first day of the last menses. During this period the fertilized egg develops into a mature foetus capable of extrauterine life.

During the first month of pregnancy the egg undergoes division; an embryo with its membranes is formed.

At the end of the second month the length of the foetus body is about 3-3.5 cm; its body has the buds which will later develop into the extremities; the cephalic enlargement is equal in length to the rest of the body; the eyes, nose and mouth are distinguishable (Fig. 57).

At the end of the third month of gestation the foetus is 8-9 cm long; it weighs 20-25 grams; the head is large; sex differences can be distinguished; the extremities begin moving, the digits can be found on the hands and feet (Fig. 57).

At the end of the fourth month the foetus is 16 cm long; it weighs 120 g; the face is distinguishable, the movements of the extremities become more active but still not perceptible by the mother; the sex differences are quite apparent.

At the end of the fifth month of gestational age the foetus is 25-26 cm long, weighing 280-300 g. The skin is red, covered with wooly hair (lanugo). The sebaceous glands start secreting fat-like substance which is mixed with desquamated epithelial cells to form vernix caseosa, the cheesy varnish. Meconium is formed in the foetus intestine. Quickening of the foetus is felt by the mother. The foetal heart can be heard on auscultation of the belly of the pregnant.

At the end of the sixth month the foe-

tus is 30 cm long, weighing 600-680 g. Its movements are more energetic. The foetus can be born alive; it makes respiratory movements but soon dies.

At the end of the seventh month the foetus is 35 cm long and weighs 1000-1200 g. The subcutaneous fat is meagre, the skin is folded, covered with the cheesy varnish (vernix caseosa) and lanugo. The cartilage of the ears and nose is soft, the nails on the hands and feet do not reach the ends of the digits. The testes are not lowered into the scrotum in boys, and the labia minora are not covered by the labia majora in girls. The foetus is born alive, it respires, but the survival rate is low.

In 28 weeks of gestation a viable foetus can be born prematurely; special care should however be given so that it might survive.

At the end of the eighth month the foetus is 40 cm long, its weight is 1500-1600 g; the foetus is viable but requires postnatal care.

At the end of the ninth month the foetus is 45 cm long, weighing 2400-2500 g; the subcutaneous fat increases in quantity, the skin is smooth, pink, wooly hair on the body is found in smaller quantity, the hair on the head becomes longer. The foetus is viable.

By the end of the tenth month the signs of dysmaturity disappear and the foetus is born mature. Full maturity is attained at the end of the tenth obstetrical (lunar) month. There are rare cases when a foetus born at full term has signs of immaturity which may be the result of inadequate intrauterine development (diseases of the mother, malnutrition, etc.). As a result, a full-term neonate is premature. There are also cases when mature foetuses are born prematurely.

The age of the neonate can be determined by measuring its length and weight. The table below (Haas' scheme) shows the method of determining the gestational age of the foetus from its length.

Lunar month (end)	Calculation	Foetus length, cm	Lunar month (end)	Calculation	Foetus length, cm
I	1×1	1	VI	6×5	30
II	2×2	4	VII	7×5	35
III	3×3	9	VIII	8×5	40
IV	4×4	16	IX	9×5	45
V	5×5	25	X	10×5	50

The table shows that the length of the foetus during the first half of pregnancy is the square of the number of months, but beginning with the sixth lunar month it is the number of months multiplied by five.

The table below gives the weight of foetus at various terms of pregnancy:

Month (lunar)	Foetus body weight, in grams (average)
III	20-25
IV	120
V	280-300
VI	600-680
VII	1000-1200
VIII	1500-1600
IX	2400-2500
X	3200-3400

At the sixth and seventh months of its growth the foetus doubles its weight compared with the previous month; the greatest gain in weight is at the ninth and tenth months (an average of 800 g).

Signs of Foetal Maturity

The maturity of a neonate is assessed by the combination of the following signs.

1. Length of a full-term mature neonate is on an average 50 cm (varying between 47 and 57 cm); the weight is 3200-3400 g (varying from 2600 to 5000 g and over).

The length of the foetus body is less variable than the weight and it is therefore a more significant sign of foetal maturity.

Neonates measuring over 47 cm are considered to be mature. Those under 45 cm are immature. Neonates measuring between 45 and 47 cm can be regarded as both mature and immature depending on a careful analysis of all other signs.

The final conclusion on the degree of maturation of the foetus is drawn by the obstetrician and the paediatrist. If only the weight of the foetus is taken into account, neonates weighing under 2500 g are considered immature.

2. The chest of a mature neonate is convex; the umbilical ring is at the midpoint between the umbilicus and the xiphoid.

3. The skin of a mature foetus is pale pink, the subcutaneous fat is well developed; the skin has traces of the cheesy varnish; the wooly hair is only present on the shoulders and the upper third of the back; the hair on the head is 2 cm long; the nails extend beyond the finger tips.

4. The ear and nose cartilage is firm.

5. The testes are lowered into the scrotum in boys, and the labia minora and the clitoris are covered by the labia majora in girls.

6. The movements of a mature neonate are active, the cry is loud, the eyes are open, the infant readily takes the breast.

The Head of a Mature Foetus

The study of the foetal skull is of great obstetrical importance. In most cases (96 per cent) the head is the first to travel through the birth canal during labour. As it passes through the birth canal it performs a series of movements (rotations). The skull sutures and the frontal fontanelle (Fig. 58) are identified during the examination which helps to outline the course of labour.

The *skull of a mature foetus* has certain features. The face bones of the foetus are joined rigidly, while there are slit-form sutures and fontanelles between the bones of the skull. When the head traverses the birth canal, the sutures and fontanelles give certain freedom to the skull bones which can thus be moulded. The skull bones are rather flexible which accounts for the *plasticity* of the foetal head, i.e. the ability to moulding, which is very important as the head passes through the birth canal.

The foetal skull is composed of two frontal bones, two parietal, two temporal, one occipital, basal and ethmoid bones (Fig. 59). The following sutures are of special obstetrical significance (Fig. 58):

The *sagittal suture* (sutura sagittalis). It passes between the parietal bones; anteriorly the sagittal suture is continuous with the frontal fontanelle and posteriorly it is bounded by the occipital fontanelle.

The *frontal suture* (sutura frontalis) is the junction between the two frontal bones; its direction is the same as of the sagittal suture.

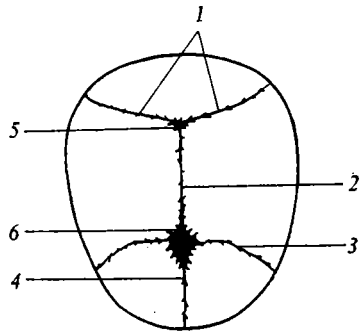

Fig. 58. Superior view of the foetal skull showing the sutures and the fontanelles: *1* — lambdoid suture, *2* — sagittal suture, *3* — coronal suture, *4* — frontal suture, *5* — occipital (posterior) fontanelle, *6* — frontal (anterior) fontanelle

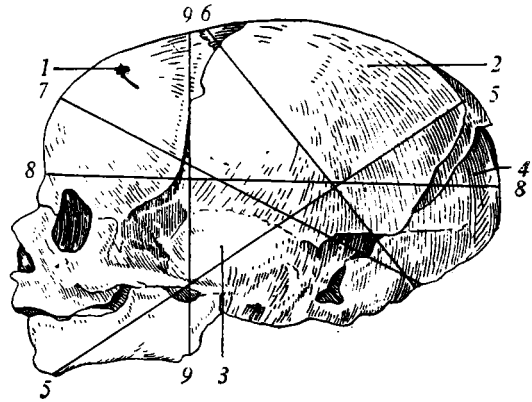

Fig. 59. Lateral view of neonatal skull: *1* — frontal bone, *2* — parietal bone, *3* — temporal bone, *4* — occipital bone, *5* — occipitomental diameter, *6* — suboccipito-bregmatic diameter, *7* — suboccipitofrontal diameter, *8* — occipitofrontal diameter, 9 — vertical diameter

The *coronal suture* (sutura coronalis). This is the junction between the frontal bone and the two parietal bones. Its course is perpendicular to the sagittal and the frontal sutures.

The *lambdoid suture* (sutura lambdoidea). This is the line of junction between the occipital and the parietal bones.

The sutures meet at the point where they form fontanelles, soft spots free from ossification. The frontal and the occipital fontanelles are of practical significance.

1. The *frontal (anterior) fontanelle* is found at the point of junction of the sagittal, frontal and coronal sutures. It has a rhomboid shape. Four sutures originate from the fontanelle: the frontal (anteriorly), the sagittal (posteriorly), and the right and left coronal sutures (laterally).

2. The *occipital (posterior) fontanelle*. This is a small triangular unossified area from which originate the sagittal suture (anteriorly) and the left and right lambdoid sutures (laterally).

The occipital protuberance, two parietal eminences and two frontal tubers on the foetus head are of practical importance as well.

Fig. 60. Superior view of neonatal skull: Transverse diameters: *1* — biparietal diameter, *2* — bitemporal diameter

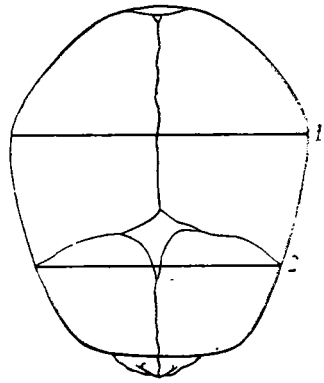

Foetus Body and Head Diameters

The average diameters of the head of a mature foetus are as follows (Figs. 59 and 60):

1. The *occipitofrontal diameter* is the distance between the midpoint of the frontal bone (glabella) and the external occipital protuberance (12 cm). The circumference of the head as measured by this diameter is 34 cm.

2. The *occipitomental diameter* is the distance from the external occipital protuberance to the most prominent midpoint of the chin (13 cm). The circumference of the head at this level is 35-36 cm.

3. The *suboccipitobregmatic diameter* is the distance from the lowest posterior point of the occiput to the anterior angle of the frontal fontanelle (9.5 cm). The head circumference here is 32 cm.

4. *Suboccipitofrontal diameter* is the distance from the lowest posterior point of the occiput to the anterior margin of the haired part of the forehead. The circumference of the head at this level is 33 cm.

5. The *vertical diameter* (s. trachelobregmatica) is the distance from the vertex to the sublingual region (9.5-10 cm). The head circumference at this level is 33 cm.

6. The *biparietal diameter* is the distance between the most remote aspects of the parietal eminences (9.5 cm).

7. The *bitemporal diameter* is the distance between the two extremities of the coronal suture (8 cm).

The obstetrically important **body diameters** are:

1. The *biacromial diameter*, which is the distance between the extreme points of the shoulder girdle (12 cm). The circumference here is 35 cm.

2. The *bisiliac diameter*, which is the distance between the two most remote points of the iliac crests (9 cm). The circumference is 28 cm.

The weight and length of neonates is noted to increase during the past years, which is probably due to improving well-being of people, better nutrition and improved labour conditions. The improved medical service for pregnant women can also be listed among the probable causes.

Chapter Four

PHYSIOLOGICAL CHANGES OF PREGNANCY

The developing foetus requires more oxygen, proteins, fats, carbohydrates, salts, vitamins and other substances, which all are supplied from the mother. At the same time the metabolites of the growing foetus pass into the maternal blood and are then excreted from the mother by her excretory organs. Hence the mother body performs additional work requiring intensification or even reconstruction of the function of her vital systems and organs.

The new load on the body of a woman imposed on her by pregnancy involves numerous and complicated alterations in the maternal body. These are physiological changes which promote normal development of the foetus and prepare the woman for labour and breast-feeding.

These alterations are controlled by the central nervous system.

The growing foetus stimulates the nerve endings of the uterus and the stimuli are transmitted to the central nervous system. The responses arising in the central nervous system stimulate the development of changes in various organs and systems of the body.

The changes occurring in the central nervous system are due not only to the reflectory mediation but also the hormonal action. The function of many organs of the internal secretion is altered at the very beginning of pregnancy to upset the hormonal balance in the circulating blood. The hormonal shifts in turn affect the central nervous system and other organs of the mother.

Nervous System

The excitability of the brain and the spinal cord is altered in pregnant women.

During the first three or four months of pregnancy the excitability of the cerebral cortex is inhibited but later it increases and remains so till the end of pregnancy. The excitability of the lower portions of the central nervous system and the nervous apparatus of the uterus remains inhibited during the entire pregnancy. The inhibited reflectory excitability accounts for certain inertness of the uterus which is important for the normal course of pregnancy.

The excitability of the spinal cord and the nervous elements of the uterus increases before delivery to promote the onset of labour.

The character of the inhibition and excitation processes in the cerebral cortex changes during pregnancy. The cortex-subcortex relationship is also affected. The tone of the vegetative nervous system is altered. All these changes account for certain drowsiness, swings in moods, changes in taste and olfactory senses, and for nausea, increased salivation, vomiting, constipations, vertigo. As a rule, these phenomena are associated with the first

months of pregnancy, and subside at later terms.

The peripheral nerves become more excitable; neuralgic pains in the sacrolumbar region, and convulsions in the leg muscles also occur. All these phenomena then completely disappear.

Endocrine System

The internal secretion organs undergo substantial changes during pregnancy. A new gland of internal secretion, the corpus luteum of pregnancy, develops in the ovary from the onset of pregnancy. Progesterone produced by the corpus luteum prepares the uterus for implantation of the ovum and normal course of pregnancy.

The follicles stop ripening in the ovaries during pregnancy. Hence the absence of ovulation. The inhibition of these processes is associated with the secretion from the corpus luteum. In the second half of pregnancy the corpus luteum undergoes regression and its functions are now performed by the placenta.

The *placenta* is a new active organ of internal secretion. It produces and accumulates gonadotropic and oestrogenic hormones, and also progesterone, the growth hormone, etc.

The ratio of the hormones in the maternal body varies during pregnancy. The hormones inhibiting excitability and contractility of the uterus prevail in the first half of pregnancy which is important for its normal development. At later terms the content of the oestrogens increases and the excitability of the uterus is thus enhanced before the onset of labour.

The *pituitary*. The anterior lobe of the pituitary gland strongly increases in size during pregnancy through multiplication and hypertrophy of the cells producing hormones. The production of the gonadotropic hormones of the pituitary gland is markedly intensified. The hormone stimulating the function of the corpus luteum of pregnancy is produced in especially great amount. The anterior lobe of the pituitary produces the growth hormone and also the hormones stimulating the function of the mamary glands, the thyroid, and the adrenal cortex. The growth of the uterus and other organs of the reproductive system during pregnancy is associated with the enlargement of the anterior pituitary. The posterior lobe of the pituitary produces oxytocin which stimulates the contraction of the uterine muscles to induce labour and to contract the uterus after delivery.

The *thyroid*. The thyroid function is intensified during the first months of gestation, but is decreased in the second half of pregnancy.

These alterations in the function of the thyroid gland induce the changes in the metabolism of the pregnant.

Parathyroids. These glands are concerned with calcium metabolism and function intensely during pregnancy. Convulsions and spasms that sometimes occur in pregnancy are associated with the decreased amounts of calcium in the body due to the reduced function of the parathyroids.

Adrenal glands. The glands are enlarged through thickening of the cortex, where the cells are multiplied and the lipoids (cholesterol in particular) are accumulated. The adrenal function accounts for the increased lipoid content of blood and pigmentation of skin in pregnancy.

The adrenal glands produce greater amounts of hormones which regulate the protein, carbohydrate and mineral metabolism.

Metabolism

The metabolism changes substantially during pregnancy which depends on the reconstruction of the function of the central nervous system and the endocrine organs. The metabolism of pregnancy is rather intense. The assimilation processes are intensified markedly in the second half of pregnancy.

Proteins. Proteinous substances are accumulated in the female body during pregnancy. They are utilized for: (1) growth of the uterus and the mammary glands; (2) growth of the foetus; (3) part of the proteins is retained in depots from which they are later spent for breast-feeding.

If the diet of the pregnant contains surplus proteins, the products of their incomplete cleavage are accumulated in the body and can adversely affect the woman.

Carbohydrates. Carbohydrates are the source of energy in pregnancy. They are readily assimilated and the sugar content of blood is usually normal. The glycogen is deposited in the liver and the muscles of the body, as well as in the placenta and uterine musculature. Carbohydrates are delivered through the placenta to the foetus in the form of glucose. Excess intake of carbohydrates can be the cause of sugar in the urine which is due to increased permeability of the renal epithelium. Should glucosuria occur, it can easily be removed by an adequate diet.

Fats. Amounts of neutral fats, cholesterol and lipids are increased in the blood of the pregnant. Fats are also accumulated in the adrenal glands, the placenta and the mammary glands. Subcutaneous fat also increases in some women. Lipids are consumed for the reconstruction of the maternal and foetal tissues; neutral fats are the source of energy. Increased lipid content of blood accounts for the easiness with which the pregnant responds to ether and other anaesthetics.

In the process of metabolism fats are split into water and carbon dioxide (the end products). If pregnancy is adversely affected by some factors (excess intake of fats in particular) the cleavage of fats to the end products can be disturbed and harmful acid products of incomplete metabolism of fats can be accumulated in the pregnant. The diet of the pregnant should therefore be so balanced that the amounts of proteins and fats be sufficient to meet the demands of the mother and the foetus, but should not exceed these requirements.

Mineral salts and body fluids. Calcium salts are retained in the body during pregnancy and utilized for the construction of the foetal bones. Phosphorus, which is necessary for the formation of the nervous system and the skeleton of the foetus, and also for the synthesis of proteins in the mother is assimilated at a higher rate.

Iron, which is the constituent of the haemoglobin, is passed to the foetus from the mother and is accumulated in the foetal liver and spleen. If the intake of iron with food is insufficient, the pregnant develops anaemia and the foetus growth is affected adversely.

These features of the metabolism of pregnancy show that the prospective mother should take food containing sufficient amounts of iron, calcium and phosphorus compounds.

The removal of sodium chloride with urine and sweat is retarded during pregnancy. The accumulation of chlorides in the tissues helps retain water in the body to account for the progressive hydration of tissues which is especially marked in the second half of

pregnancy. The increase in the total body water facilitates the normal course of labour, it promotes distensibility of tissues which is especially important for the normal passage of the foetus through the birth canal. In normal pregnancy body water and chlorides are not retained in excess amounts and the fluids are rapidly excreted from the body by the kidneys. In cases of pathology the excretion of fluids is retarded; water and chlorides are then accumulated in the body and cause oedema.

Vitamins. The demand for vitamins increases in pregnancy since part of them is consumed by the foetus.

The requirement for vitamin C especially increases since this vitamin is necessary for growth of the foetus and its membranes. The requirement for vitamins A, B_1, D and E also increases since these vitamins promote the development of pregnancy. If the diet is poor in vitamins, the pregnant develops hypovitaminosis, or even avitaminosis, which is a pathological state and is detrimental to the pregnancy in general.

Body weight. The woman gains in weight during the entire course of pregnancy but especially during its last months. During the second half of pregnancy the woman gains 300-350 g weekly and by the end of pregnancy the total gain in weight is 10-12 kg. This is due to several causes, such as the growth of the foetus, accumulation of the amniotic fluid, the enlargement of the uterus, increased amount of subcutaneous fat, and of the blood of the pregnant.

Blood

The haematopoietic process is intensified during pregnancy. The haemoglobin, erythrocyte, and leucocyte counts increase along with the enlargement of the total volume of the circulating blood and plasma.

The volume of the blood and the counts of erythrocytes and haemoglobin start increasing from the first months of pregnancy and continue so till the sixth-eighth months. The intensity of haematopoiesis decreases before labour. The volume of the circulating blood increases by 35-40 per cent by the end of pregnancy, and the erythrocyte count, by 15-20 per cent. The haemoglobin, erythrocyte and leukocyte counts are normal in healthy pregnant women. The mean sedimentation rate of erythrocytes may be slightly increased.

Cardiovascular System

The cardiovascular function is intensified during pregnancy since a new, placental circulation is added and the vascular network of the uterus increases significantly.

The heart of a healthy pregnant woman is gradually adapted to the new conditions and meets the additional load. Pregnancy is characterized by hypertrophy of the muscular elements of the heart and its intensified contractility.

The capillary walls become more permeable to water, salts and finely dispersed proteins of the blood serum—albumins. The increased capillary permeability intensifies the exchange between the blood and the tissues of the pregnant.

The arterial pressure usually remains unaffected during the entire pregnancy. In some women, however, it tends to be unstable at early terms and is elevated during the last months of preg-

nancy. However if the pregnancy is normal, the maximum arterial pressure does not exceed 125 mm Hg. The pulse rate does not change during pregnancy.

If the pregnancy is not the first, the woman may have the veins of her lower extremities dilated. Haemorrhoids may also develop due to blood congestion in the organs of the small pelvis.

Gastrointestinal Tract

Nausea (morning sickness), sometimes with vomiting, particularly in the morning, are often manifested in many women during the first two or three months of their pregnancy. The senses of taste and smell change and the woman may feel disgust to certain foods and on the contrary feel desire for some unusual substances such as clay, chalk, etc.

All these symptoms subside by the end of the third or fourth month of pregnancy. In rare cases they may persist till later terms. The gastrointestinal function does not normally change. Sometimes the tone of the intestine may decrease which will be manifested in varying degrees of constipation.

As the pregnant uterus enlarges, it displaces the intestine upward and lateralward. If the foetus is large, or the pregnancy is multiple or else there is an excess of the amniotic fluid, the stomach and even the liver can be shifted upward.

The liver is involved in the metabolism of all substances and renders harmless the toxic products of intermediate metabolism. The load on the liver increases which is associated with metabolic changes of pregnancy. Moreover, the liver renders harmless the metabolites of the foetus.

Respiratory System

The respiratory function of the lungs is intensified during pregnancy in connection with the increased demands for oxygen. Although the uterus elevates the diaphragm at the end of pregnancy the functional surface of the lungs does not decrease because the chest of the pregnant enlarges. The respiratory rate slightly increases by the end of pregnancy.

Urinary System

The load on the kidneys of the pregnant increases since they remove also the metabolites of the growing foetus. Traces of protein can be found in the urine during the last months of pregnancy. If the protein content exceeds 1 mg per litre, this indicates the onset of a serious disease, the toxicosis of pregnancy.

During the first months of pregnancy the woman becomes aware of frequent urination which is due to compression of the bladder by the uterus. At later terms the bladder distends and is shifted upwards, which in turn distends and straightens the urethra. The tone of the ureters decreases, their lumen widens. At the end of pregnancy. the foetal head presses against the inlet to the small pelvis and may exert pressure on the bladder: the urination thus becomes more frequent.

Skin

Certain changes occur in the skin during pregnancy. A frequent symptom is the pigmentation of certain regions of the skin, of the white line of the abdomen, the breast nipples and the

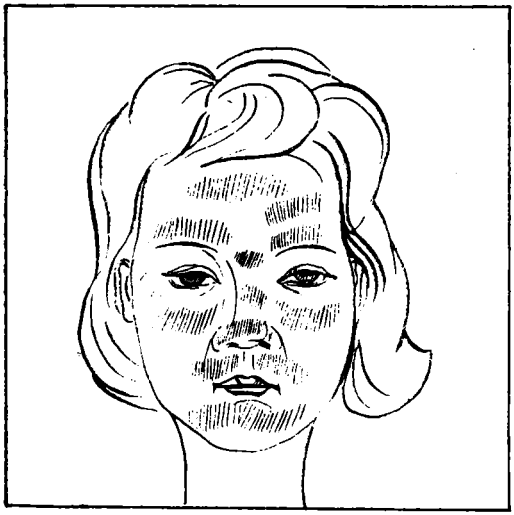

Fig. 61. Mask of pregnancy

areola (Fig. 62). Discolouration over the forehead, the bridge of the nose, and the upper lip, which is known as chloasma or the mask of pregnancy Fig. 61) is especially frequent in pregnancy. The discoloration is especially apparent in the dark-haired.

The pigmentation is associated with the altered function of the adrenal cortex and the pituitary.

The abdominal wall is distended by the growing uterus. If the distension is considerable and the skin is not sufficiently elastic, striae of pregnancy (striae gravidarum) occur in the skin (Fig. 63).

The striae are formed due to separation of the connective tissue and the elastic elements of the skin. The malpighian layer of the skin can be seen at points of tissue separation through the epidermis. The striae are pink, reddish, or bluish-red stripes. They can usually be found on the abdomen, and less frequently on the thighs and breasts. Later the striae tend to become white and lustrous. In subsequent pregnancies new bluish-red scars of pregnancy can appear by side of the old white striae.

Changes occur in the umbilical re-

Fig. 62. Pigmentation of the nipples and the white line

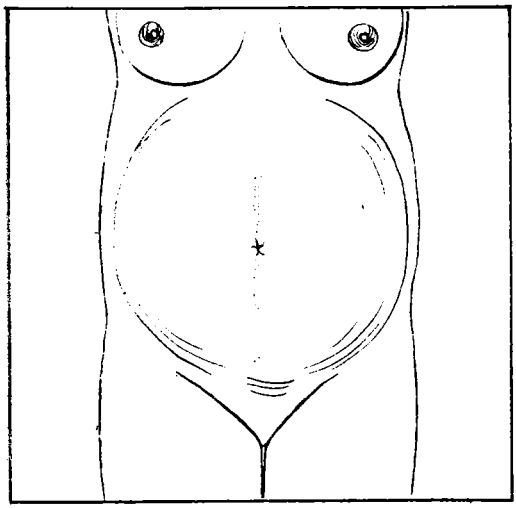

Fig. 63. Striae in the skin

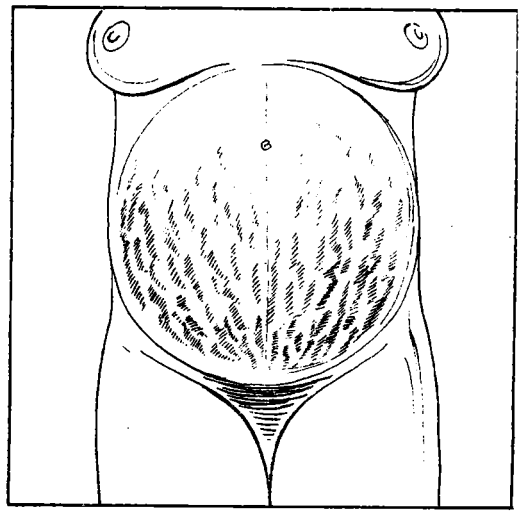

gion as well. During the second half of pregnancy the navel becomes levelled and by the tenth month becomes protruded.

The straight muscles of the abdomen may be separated in multiparous women or in multiple pregnancy, which is associated with accumulation of large amounts of the amniotic fluid. The tendons, cartilages and the synovial membranes become soaked with serum during pregnancy.

The symphysis cartilage becomes loose, its slit increases in size, and the ligaments of the symphysis and the sacroiliac joint become distensible.

Reproductive Tract

Pregnancy induces changes in the entire female body but they are most pronounced in the uterus. The size, shape, position, consistency and reactivity (excitability) of the uterus are altered.

The uterus increases in size progressively throughout pregnancy. The length of the uterus before pregnancy is only 7-8 cm, while by the end of pregnancy it is 38 cm long. The transverse diameter of the uterus increases from 4-5 to 25-26 cm. Normally the uterus weighs 50-100 g, whereas by the end of pregnancy it weighs 1000-1200 g (less the foetus, the amniotic fluid, etc.). The volume of the uterus cavity increases 500 times (at term) mainly through hypertrophy and hyperplasia (i.e. through the increasing dimensions and the quantity) of the uterine muscular fibres.

Each muscular fibre increases in length about ten times and thickens 4-5 times. At the same time the muscular fibres multiply and muscular elements develop.

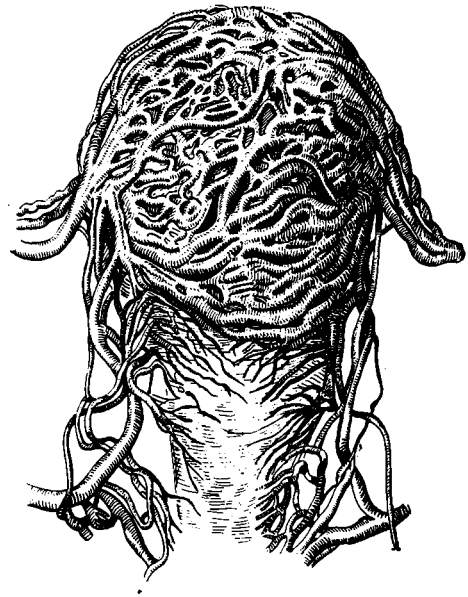

Fig. 64. Vascularization of the pregnant uterus

Hyperplasia of muscular fibres occurs mainly during the first half of pregnancy while at later terms the size of the uterus mainly increases through extension of its walls by the growing foetus, its membranes and the amniotic fluid. The connective tissue of the uterus proliferates and becomes loose. The quantity of elastic fibres increases. The endometrium undergoes substantial changes and turns into the decidual (thrown off) membrane.

The vascular network of the uterus increases significantly. The arteries and veins of the uterus elongate and widen. The lumen of the veins increases in particular. The arteries become sinuous, sometimes spiral, which helps their adaptation to the changing dimensions of the uterus during its contractions (Fig. 64). The flow rate of blood through the vessels increases several times during pregnancy.

Nerve elements of a pregnant uterus undergo hypertrophy, the lymphatic vessels become elongated and wide, the serous coat of the uterus increases in size as well. Actomyosin (the system responsible for the contraction and relaxation of the uterine muscles) content in the wall of a pregnant uterus increases along with the increase in the amount of calcium, glycogen and phosphocreatine, which all are necessary for the contraction of the uterus during labour.

The cervix of a pregnant uterus becomes soft and extensible. The vessels become elongated, the veins sharply widen and become filled with blood. The colour of the cervix becomes bluish.

Till the end of the first trimester the conceptus occupies the uterine cavity proper, but beginning with the fourth month the lower pole of the growing conceptus distends the isthmus of the uterus to incorporate it into the main cavity of the uterus. Together with the lower portion of the uterus body the isthmus now forms the lower uterine segment.

During labour the isthmus and the uterine cervix form the outlet tube.

The external and internal os remain closed in the primipara till the onset of labour. If the delivery is not the first, the endocervical canal distends during the last months of pregnancy and sometimes passes a finger.

The shape of a pregnant uterus changes. In the early weeks of pregnancy, the angle where the fertilized egg has been implanted, becomes projected, but beginning with the third month of gestation the uterus becomes rounded to turn into a sphere, and finally into an ovoid.

The position of the uterus varies with the progressing pregnancy. During the early weeks of pregnancy the anteflexion of the uterus increases, while later the angle between the uterine body and the cervix disappears; the uterus straightens, sometimes inclines to the right and rotates from left to right (posteriorly with its right edge). As the third month of pregnancy expires, the uterus bottom rises above the pelvic inlet plane and at the end of the ninth month it is found as high as the hypochondrium. The pregnant uterus becomes soft, especially at the isthmus.

The *fallopian tubes* become thick and juicy due to hyperaemia and serous impregnation of the tissues. As the uterus grows further, the tubes assume more vertical position and by the end of pregnancy they hang down along the uterus edges.

The *ovaries* slightly increase in size, become softer and discontinue ovulating. One ovary contains the corpus luteum of pregnancy. As the uterus increases in size, the ovaries rise from the pelvic cavity to assume a new position in the abdominal cavity (at the lateral surface of the uterus).

The *ligaments* of the uterus elongate and become thicker. The round and uterosacral ligaments undergo especially marked hypertrophy which is necessary to maintain the uterus in normal position during labour. The round ligaments of the uterus can be palpated through the abdominal wall and their position can be used to determine the point of attachment of the placenta. If the round ligaments are parallel or diverging downward, the placenta is attached to the anterior wall of the uterus. If the placenta is attached to the posterior wall, the round ligaments converge in the downward direction.

The *connective tissue* of the pelvis becomes loose, easy to stretch, and hyperhydrous.

The *vagina* undergoes substantial

changes as well. The blood supply of the vaginal walls increases considerably and all its layers become soaked with serum. They become loose, hyperhydrous, and readily distensible. The vaginal mucosa becomes bluish.

The muscular connective-tissue elements of the vagina undergo hyperplasia and hypertrophy during pregnancy and the vagina elongates and widens; its rugae become more pronounced.

Because of loosening the absorbing capacity of the vaginal mucosa increases and syringing with poisonous substances such as corrosive sublimate, Acetarsol or other bactericidal drugs is therefore dangerous.

The *external genitalia* loosen during pregnancy, the mucosa of the vestibule becomes cyanotic. Varices often develop in the external genitalia of multiparous women.

Breast

The growth of the breasts begins at puberty under the stimulation of the sex hormones.

During pregnancy the breasts are prepared for the secretion of milk. The lobules increase in size, and fine particles of fat develop in the alveolar epithelium. The blood supply to the breasts is intensified, subcutaneous veins are dilated and show through the delicate skin. The breasts become engorged and tingling is often felt by the pregnant. The nipples increase in size, and the areolar area is characterized by a greater degree of pigmentation. The Montgomery glands become more prominent. The smooth muscles of the nipple become more excitable. When stimulated mechanically, the nipple muscles contract, the areolar area decreases in size and the nipple becomes more projected.

Small amount of fluid (colostrum) may be expressed from the nipple during the early months of pregnancy.

The breasts get prepared for lactation under the action of placental hormones and the lactogenic hormone of the anterior pituitary.

Thus, all changes occurring in the female body during pregnancy are physiological; they facilitate normal growth of the foetus without causing any harm to the expectant mother. Moreover, pregnancy gives a new impetus to the bloom of the woman.

Chapter Five

DIAGNOSIS OF PREGNANCY. EXAMINATION OF THE PREGNANT

The main duty of the obstetrician is to examine the pregnant in order to reveal certain diagnostic symptoms. As soon as pregnancy has been diagnosed, its terms are determined and the date of pregnancy-leave appointed.

The examination of the pregnant should reveal any possible complications or diseases of pregnancy which may adversely affect the course of pregnancy and labour.

A set of diagnostic signs and anamnestic data should be used to establish the diagnosis of pregnancy. The following objective methods are used in obstetrics:

1. Common clinical examination of the patient (external examination, examination of the internal organs by percussion, auscultation, palpation, etc.).

2. Special examination. These are: (a) external and vaginal examination; (b) examination with specula; (c) palpation of the foetus; (d) determining pelvic diameters and architecture; (e) measuring the intrauterine foetus, etc.

3. Laboratory tests aimed to reveal possible complications of pregnancy (examination of blood, urine, serological tests, etc.).

Taking History

The history taking follows the conventional pattern. All data are put down in the obstetric record.

1. Patient identification (name, surname), age, occupation, address.

The age of the pregnant is very important since very young and aged primipara often develop complications of pregnancy and labour.

2. Patient's complaints. As a rule, the pregnant would seek for medical care in cases of amenorrhoea and suspected pregnancy. They often complain of changes in the taste, nausea and vomiting, and other disorders occurring in the early weeks of pregnancy. Some complain of vaginal smearing which is a symptom of many complications (abortion, ectopic pregnancy, vesicular mole, placental presentation, etc.).

Sometimes the pregnant complains of disorders which indicate toxicosis of pregnancy, cardiovascular diseases, diseases of the respiratory and digestive organs, etc. All complaints should be carefully recorded and used in establishing the diagnosis.

3. Hereditary traits and past medical history. Hereditary diseases are important since they can adversely affect the intrauterine development of the foetus. It is necessary to know if the maternal family or the family of the husband had genetically transmitted psychic disorders, diseases of the blood, metabolic and other disorders. It is also necessary to find out if any of the family had intoxications, such as alcoholism, smoking and the like.

The knowledge of the past history is very important. Diseases of childhood are of special importance. For example, rickets of childhood can be the cause of pelvic deformations which will cause complications of labour. The presence of rickets in the past history should therefore be obligatory revealed (delayed eruption of teeth, delayed walking, skeletal deformations, etc.).

Mumps, measles, recurrent tonsillitis and other diseases can retard the development of the entire body and its reproductive system. Diphtheria of the vulva and the vagina gives cicatricial constrictions. Diseases of the kidneys, which often develop after scarlet fever, aggravate the course of pregnancy and are indications for its interruption. Past infectious and gynaecological diseases of adulthood should also be taken into account.

Past cardiovascular diseases, renal, pulmonary and other disorders can also affect the normal course of pregnancy and labour. Moreover, pregnancy and labour can provoke exacerbation of heart, kidney, liver and other diseases.

4. The menstrual function.

Questioning of the prospective mother should reveal the following: (a) the age of menarche and the onset of regular menses; (b) type of menses (length of the menstrual cycle and bleeding, quantity of blood shed during menses, pains if any, etc.); (c) whether or not the menstrual cycle has changed since the commencement of sexual life, childbirth or abortion; (d) the date of the last menses. The menstrual function characterizes the condition of the reproductive system and the entire body of the woman. The first menses at the age of 16-17 or in later years, the long period extending from the first menses till the onset of regular menstrual cycle (over five months), painful menses (dysmenorrhoea) are specific to underdeveloped reproductive system.

Disorders in the menstrual function following the commencement of sexual life, childbirth or abortions are usually the symptoms of inflammatory diseases of the internal genitalia or ovarian dysfunction.

5. Secretory and reproductive function.

It is necessary to establish if the secretion from the reproductive organs is normal. Pathological discharge (profuse, purulent, mucous or watery containing pus, etc.) usually indicates the presence of inflammatory diseases. Polyps, erosion, cancer of the cervix, etc., can also be the cause.

The pregnant should be asked if she feels any pains or has vaginal bleeding provoked by coitus.

6. Childbearing function or obstetric anamnesis.

The following important data should be obtained by questioning the pregnant:

(a) The chronological order of the present pregnancy.

(b) Complications of the previous pregnancies, if any: toxicoses of pregnancy (vomiting, increased salivation, oedema, etc.), diseases of the cardiovascular system, kidneys, liver, and other organs. The presence of these diseases in the past history requires special supervision of the pregnant.

(c) The outcome of the previous pregnancies: childbirths, abortions, etc.

With abortions in the past history, it is necessary to establish their character: spontaneous, artificial, gestational age by the moment of abortion, diseases after the abortion (if any) and their character.

Premature labour and spontaneous

abortions are signs of underdeveloped reproductive system (infantilism) or some diseases which adversely affect the course of pregnancy (endometritis, tumours, infectious diseases, malnutrition or inadequate nutrition, etc.).

Spontaneous and artificial abortions are often followed by inflammatory diseases of the genitalia, complications of subsequent pregnancies, or habitual abortions; labour may be abnormal and accompanied by bleeding.

(d) Characteristics of the previous labour: at term or premature; character of labour. Normal previous labour is an evidence of normal health of the pregnant and absence of abnormalities in the birth canal. Any complications or operative interventions in previous labour, stillbirths or early postnatal deaths indicate possible abnormalities in the birth canal or systemic diseases of the pregnant, toxicosis, etc.

Pathological labour in the past (aggravated obstetrical anamnesis) indicate possible complications of the present pregnancy and labour.

(e) Postnatal diseases of the past. Postnatal diseases can cause severe complications in subsequent pregnancies (abnormal labour, retained placenta, the rupture of the uterus).

7. Recording the time that has elapsed from the commencement of the sexual life and the onset of the first pregnancy. Sterility for several years (without taking contraceptives) can be the result of infantilism which will account for sluggishness of uterine contractions during labour (uterine inertia), etc.

8. Medical history of the husband. Diseases that can be detrimental to pregnancy and future infant (gonorrhoea, tuberculosis, etc.) should be revealed.

9. Work and living conditions are very important for the health of the prospective mother and the intrauterine development of the foetus. The information concerning life of the pregnant should therefore be as complete as possible and the appropriate measures should be taken to improve the living conditions of the pregnant.

As soon as the anamnesis has been collected, the pregnant woman should be given an objective examination.

Examination of the Pregnant

External examination often suggests useful information for diagnosis. A short woman, for example, may presumably have narrow pelvis. Deformations of the spine and lower extremities, ankylosis of the joints and other bone malformations may indicate abnormal architecture of the pelvis. Underdeveloped breasts and scarce pubic hair may suggest underdevelopment of the genitalia. Oedema of the lower extremities and other parts of the body is an evidence of complications of pregnancy (toxicosis, heart disease, etc.).

Pallor of the skin and the visible mucosa, bluish lips, or yellow skin and sclera are symptoms of certain serious diseases.

Examination of the abdomen during the second half of pregnancy can sometimes reveal abnormalities. If pregnancy is normal (normal presentation), the abdomen is ovoid. In transverse presentation, the abdomen sides are extended laterally; spherical abdomen indicates excess of the amniotic fluid (hydramnion) and its size is usually much greater than it should be at a given moment of pregnancy. Abnormal shape of the abdomen can also indicate narrow pelvis.

The configuration of the Michaelis

rhomboid, in combination with other signs, can also be used for the assessment of the pelvic architecture.

Examination of Internal Organs

The external examination should be followed by the examination of the heart, lungs and the abdominal viscera following the conventional pattern (auscultation, percussion, palpation).

Examination of the heart, lungs and other organs of the pregnant is necessary to reveal in due time possible contraindications to pregnancy.

The pregnant should have her arterial pressure measured, the urine and blood tested, and the body weight determined. During the second half of pregnancy, the measurement of the arterial pressure and weight (and the urine test) should be performed regularly.

Next follows special obstetrical examination.

Different methods are used for early and later diagnosis of pregnancy.

Early Diagnosis of Pregnancy

Pregnancy is not doubted if the examiner can palpate various parts of the foetus, can hear its heart, feel its quickening, or observe the foetus skeleton on an X-ray pattern. These certain signs of pregnancy can only be seen at later terms of pregnancy (fifth or sixth month of gestation).

Early diagnosis of pregnancy can be established by positive and presumptive signs.

Presumptive signs of pregnancy. These are general changes in the entire body of the woman associated with pregnancy.

(1) Changes in the taste and appetite, abnormal desire for piquant and spicy food, for unusual substances such as chalk, carbon black, etc.; nausea, vomiting in the morning.

(2) Changes in the sense of smell (a dislike of perfumes, tobacco smoke, etc.).

(3) Changes in the nervous system: irritability, drowsiness, swings in mood, etc.

(4) Discolouration of the skin on the face, the white line of the abdomen, the nipples and the areola.

Positive signs of pregnancy. These are changes in the genitalia and the menstrual function.

(1) Cessation of the menses. The menses can however be suspended in grave diseases and frustration (fear, distress, etc.). The cessation of menses in a normal woman would usually be associated with the onset of pregnancy.

(2) Cyanosis of mucosa of the vagina and the uterus cervix.

(3) Changes in the size, configuration and consistency of the uterus.

(4) Colostrum can be expressed from the lactiferous ducts opening on the nipple.

Positive signs become apparent on (a) examination of the external genitalia and the mucosa of the vestibule; (b) examination with specula; (c) vaginal and bimanual examination of the woman; (d) palpation of the breast and pressing out of colostrum.

The vaginal examination should be performed on the patient in a gynaecological chair or on an examining table. In the latter case the legs of the woman are flexed on the abdomen and set apart (lithotomy position). A cushion should be placed under the sacrum of the patient.

The examiner prepares his hands by washing them with warm water and



Fig. 65. Vaginal specula:
a — two-valved speculum, *b* — spoon-shaped speculum

soap using a brush, and then treats them with a disinfectant (chloramine, 0.5 per cent solution, lysoform, 1 per cent solution, etc.). The examiner should better use a sterile glove. The patient's vulva is cleansed with a dilute (1:600) solution of potassium permanganate or other disinfectant solution and dried with sterile cotton wool. The labia majora and labia minora are set apart by the thumb and the index finger of the left hand and the vulva, the mucosa of the vestibule, the outlets of the Bartholin glands, the meatus, and the perineum are inspected.

Speculum examination. After examination of the external genitalia and the mucosa of the vestibule, the examiner proceeds with the examination using specula. Speculum examination may reveal cyanosis of the cervix and the vaginal mucosa (positive signs of pregnancy) and also diseases of the cervix and the vagina (inflammation, erosion, polyps, cancer).

Spoon-shaped and two-valved vaginal specula (Fig. 65) can be used for vaginal examination. The two-valved speculum is introduced into the vagina until it reaches the vault and then its blades are separated and the cervix becomes exposed to the observer. The vaginal walls are inspected when the speculum is gradually withdrawn from the vagina. The cervix and the vagina become readily accessible to examination with spoon-shaped specula (Fig. 66) First one speculum is introduced into the vagina and slightly pressed against its posterior wall and the perineum.

Fig. 66. Vaginal examination with spoon-shaped specula

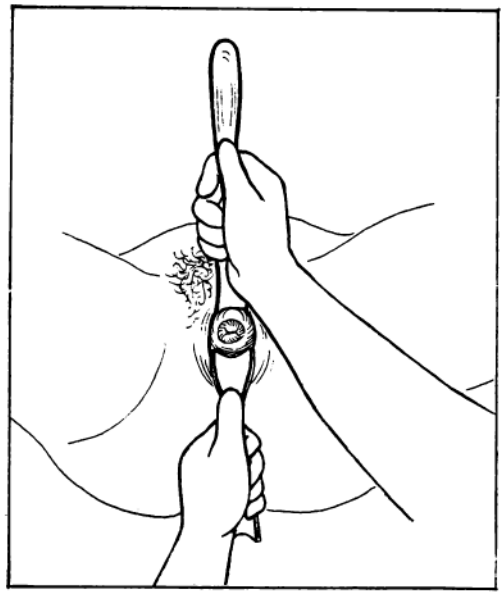

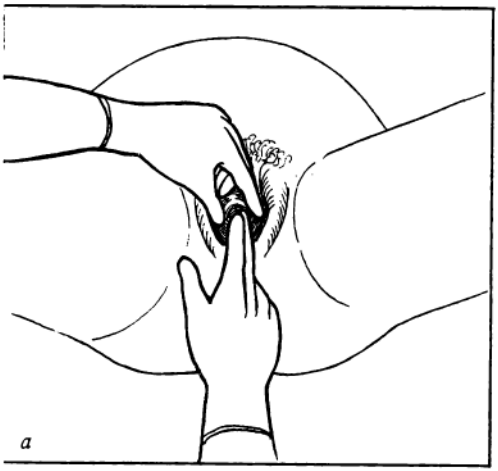

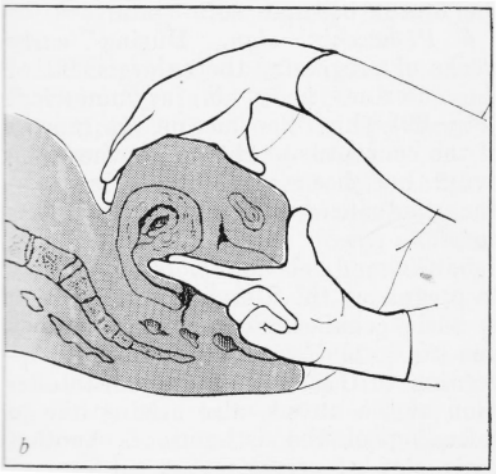

Fig. 67. Vaginal examination
a — introduction of the fingers into the vagina, *b* — bimanual examination

Next another speculum is inserted and the anterior wall of the vagina is elevated. As soon as the cervix and the vagina have been inspected the examiner proceeds to manual examination.

Vaginal examination of the pregnant. Using the thumb and the index finger of the left hand the examiner separates the labia majora and labia minora and introduces the middle and the index fingers of the right hand into the vagina so that the thumb is raised upwards while the fourth and the fifth fingers are bent (Fig. 67, *a*) and rest against the perineum. The fingers examine the muscles of the pelvic floor, the vaginal walls (rugae, distensibility, looseness), the vaginal fornices, the cervix (shape, consistency) and the external os of the endocervical canal (open or closed, oval or slit-shaped configuration).

Bimanual examination. When the palpation of the cervix has been completed, the physician proceeds to the bimanual examination (Fig. 67, *b*).

The fingers of a more adept (right) hand are introduced into vagina, placed in the anterior fornix, and the uterus cervix is then pulled slightly posteriorly. The fingers of a less dominant (left) hand press carefully on the abdominal wall in the direction of the small pelvis to meet the fingers of the other hand in the anterior fornix. As the fingers of both hands approach each other, the examiner locates the uterus and outlines its position, configuration, the size and consistency. The fallopian tubes and the ovaries are examined next. The fingers of the examining hands move gradually from the angles of the uterus to the lateral walls of the pelvis. The bimanual examination is completed by palpating the inner surface of the pelvic bones and measuring the diagonal conjugate.

The diagnosis of pregnancy is established by the following signs.

1. *Enlargement of the uterus.* The increase in the size of the uterus can be assessed by the 5-6th week of gestation. The uterus first grows in the anteroposterior direction and becomes more like a sphere; later it grows in the transverse direction as well. The en-

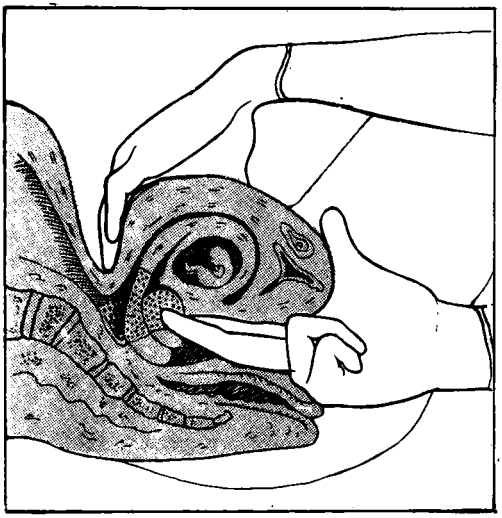

Fig. 68. Gorvits-Hegar sign

Fig. 69. Piskacek's sign

largement of the uterus becomes more evident as pregnancy advances. By the end of the second month the uterus grows to the size of a goose egg, and by the end of the third month its fundus rises to the level of the symphysis.

2. *Gorvits-Hegar's sign.* (Fig. 68). The uterus consistency is soft, especially in the isthmic region. The fingers of the examining hands (bimanual examination) meet almost without resistance at the isthmus. This sign is characteristic of early pregnancy.

3. *Snegirev's sign.* A pregnant uterus is characterized by marked changeability of its consistency. During bimanual examination the softened pregnant uterus becomes more compact and contracts in response to mechanical stimulation. As soon as the exciting action of the examining hands ceases, the uterus becomes soft again.

4. *Piskacek's sign.* During early weeks of pregnancy the enlargement of the uterine body is asymmetrical (Fig. 69) which depends on the growth of the conceptus at the angle where the ovum has been implanted. As pregnancy advances, the asymmetry disappears.

5. *Gubarev and Gaus noted* that early in pregnancy the uterus cervix position is easily changeable which is mainly due to softening of the isthmus. According to Genter, pronounced anteflexion of the uterus, also arising due to softening of the isthmus, is another early sign of pregnancy.

Thus the examination of the patient gives a combination of signs which can be used to diagnose pregnancy. All positive and presumptive signs revealed during the examination of the woman should be taken into account.

Should the early diagnosis of pregnancy be doubtful, the woman should be given another examination in one or two weeks' time, when all signs become more evident with the advancing pregnancy (enlargement of the uterus, etc.).

Differential Diagnosis of Pregnancy

Pregnancy would be usually diagnosed from the data of clinical studies (anamnesis, inspection, vaginal examination, etc.). Difficulties arise in diagnosing some pathological conditions associated with pregnancy. It is often difficult to differentiate between the ectopic pregnancy and adnexitis. Difficulties may also arise in differentiating pregnancy from cancer of the uterus, etc.

In such cases, in addition to careful clinical studies of the woman, biological pregnancy tests should be carried out.

Aschheim-Zondek test. From the onset of pregnancy large amount of the gonadotropin is produced in the female body and excreted with urine.

When given subcutaneously to immature female mice, the urine stimulates the growth of the uterus and the follicles, and provokes haemorrhage into the enlarged follicles, which then develop into the corpus luteum.

Female mice weighing 6-8 g are injected with 0.2 to 0.4 ml of first morning urine six times in two days and then are sacrificed in 96-100 hours. The uterus and the ovaries are examined and the presence of haemorrhage in the follicles (which is vivid to a naked eye) or the enlarged uterus is considered a positive sign.

The *Frog test*. Males of some amphibia (frogs and toads) produce sperm cells under the action of the gonadotropin contained in the urine of the pregnant. A test animal is injected with 2.5 ml of the urine into a lymph sac on the back and the cloacal fluid is taken by a pipette in 1 to 2 hours. The test is considered positive if microscopy reveals the presence of mobile spermatozoa.

Immunological diagnosis of pregnancy. An immunological method using the haemagglutination test is now used to diagnose pregnancy.

A specially prepared antiserum of female rabbits agglutinates sheep erythrocytes treated with the human chorionic gonadotropin. When the urine of a pregnant woman (containing the gonadotropin) is added, the erythrocyte agglutination is retarded.

Some additional methods are also used in the diagnosis of pregnancy such as ultrasound, which can be used to detect the foetal heart tones as early as the 8-10th week. Ultrasound also shows the presence of the conceptus in the uterus.

Late Diagnosis of Pregnancy

Undoubted or absolute signs develop during the second half of pregnancy. They are as follows:

1. *Identification of the foetus by palpation*. The foetal head, back, and the extremities can be palpated during the second half of pregnancy.

2. *The foetal heart tones* can be clearly and consistently heard in the second half of pregnancy as rhythmic beats (130-140 per minute). The heart tones can sometimes be heard by the 18-19th week of pregnancy.

3. *Foetal motion* may be noted by the examiner in the second half of pregnancy. The woman can feel quickening of the foetus by the 20th week. If the present pregnancy is not the first, the woman can feel it at earlier terms. These signs are however not absolute since they can be mistaken for some other signs, e.g. intestinal peristalsis.

4. *X-ray visualization of the foetus.* X-ray evidence of pregnancy can be obtained by the fifth month. Since the exposure of the foetus to X-rays is undesirable, it should only be used in emergency cases. X-rays are especially contraindicated in the early weeks of pregnancy.

5. *Objective diagnostic methods* include recording the heart beats of the foetus by electrocardiography, phonocardiography, and ultrasound.

Presentation

The examination of the pregnant or parturient woman includes determination of the foetal position in the uterus.

1. *The placement of the body members.* The foetus body is normally flexed, its chin is pressed against the chest, the legs are flexed upon the thighs, and the hands are crossed on the chest. When in the normal position, the foetus has the shape of an ovoid, with the average length at term being 25 cm. The wider part of the ovoid (the caudal end) is found in the fundus of the uterus while the narrower part (the occiput) is directed toward the pelvic inlet.

During foetal motion inside the uterus, the position of the extremities can change for a short period of time but this would not upset the normal position of the foetus.

2. *Location of the foetus relative to the vertical diameter of the uterus.*

The following positions are distinguished:

(a) longitudinal—the long axes of the foetus and the maternal bodies coincide (Fig. 70, *a*);

(b) transverse—the long axis of the foetus body is found to lie at a right angle to the vertical axis of the uterus (see Fig. 76).

(c) oblique—the long axis of the foetus forms an acute angle with the vertical axis of the uterus.

The longitudinal presentation is considered normal and occurs in 99.5 per cent of cases. The transverse and oblique presentations are less frequent (0.5 per cent of cases) and considered to be a pathological condition.

3. *The position of the foetus spine relative to the sides of the uterus.* The *left* and *right* positions are distinguished, in which the foetus back lies on the left or right side of the uterus, respectively.

The left position is more common which can be explained by the rotation of the pregnant uterus anteriorly with its left side.

In cases of transverse or oblique presentation, the left or right position of the foetus is determined not by its back but by its head.

The foetal back is not always directed lateralward, but is usually slightly turned anteriorly or posteriorly.

4. *Anterior* (Figs. 70 and 71) *and posterior* (Figs. 72 and 73) *positions* are thus distinguished.

5. The *large portion of the foetus* (*its presenting part*) *gives the name to presentation* which may be cephalic (the foetus head rests against the pelvic inlet), or pelvic (breech) presentation (the buttocks of the foetus are presenting) (Figs. 74 and 75).

6. The *presenting part is the portion of the foetus that is the nearest to the inlet of the small pelvis and is the first to travel through the birth canal.*

The cephalic presentation can be subdivided into the occiput, vertex (anterior), brow (frontal), and face (mentum) presentations depending on whether the occiput, the vertex, brow or face is presenting. The occiput (flexed) presentation is typical; it occurs in

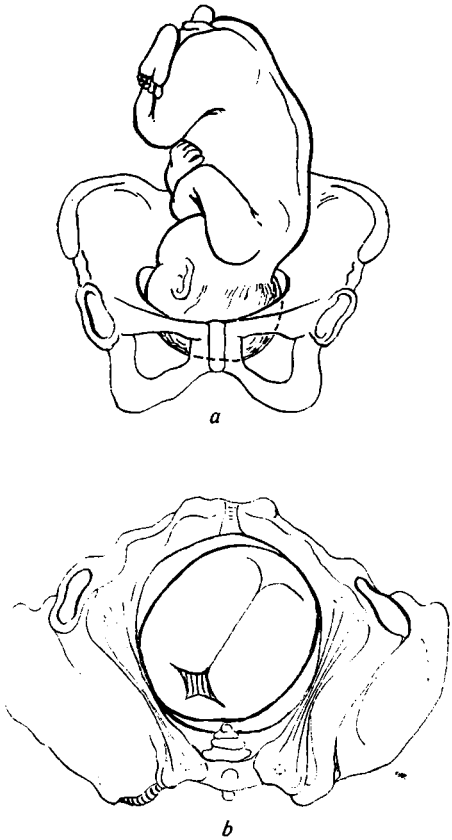

Fig. 70. *a* — longitudinal, left occiput anterior presentation, *b* — inferior view: the sagittal suture in the right oblique diameter; the left anterior position of the posterior fontanelle

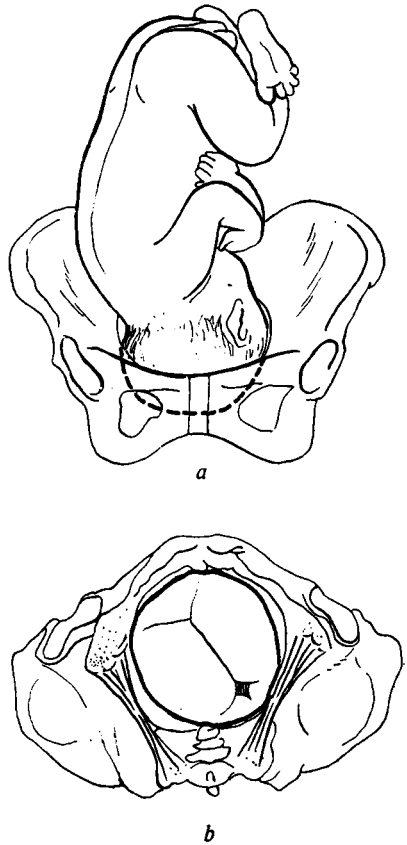

Fig. 71. *a* — longitudinal, right occiput anterior presentation, *b* — inferior view: the sagittal suture in the left oblique diameter; right anterior position of the posterior fontanelle

95 per cent of all longitudinal presentations. In anterior vertex, brow and face presentations the head is found in various degrees of flexion. Deflexed presentation occurs in 1 per cent of all longitudinal presentations.

Breech presentation can be complete (double breech), footling (single or double) or incomplete.

7. *Synclitism and asynclitism are distinguished in the position of the sagittal suture of the foetal head relative to the symphysis pubis and the sacral promontory.* In case of synclitism the sagittal suture is equidistant from the symphysis and the promontory. The asynclitic condition is characterized by the displacement of the sagittal suture toward the promontory or the symphysis. If the sagittal suture is closer to the promontory the condition is known as anterior asynclitism (an-

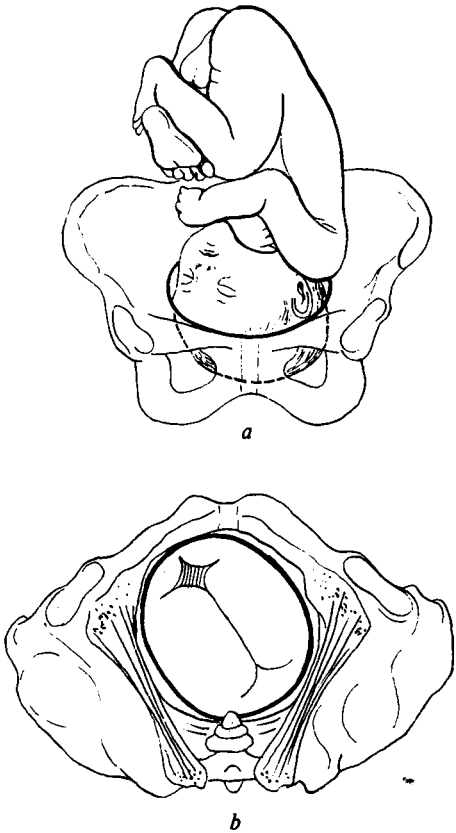

Fig. 72. *a* — longitudinal, left occiput posterior presentation, *b* — inferior view: the sagittal suture in the left oblique diameter; left posterior position of the posterior fontanelle

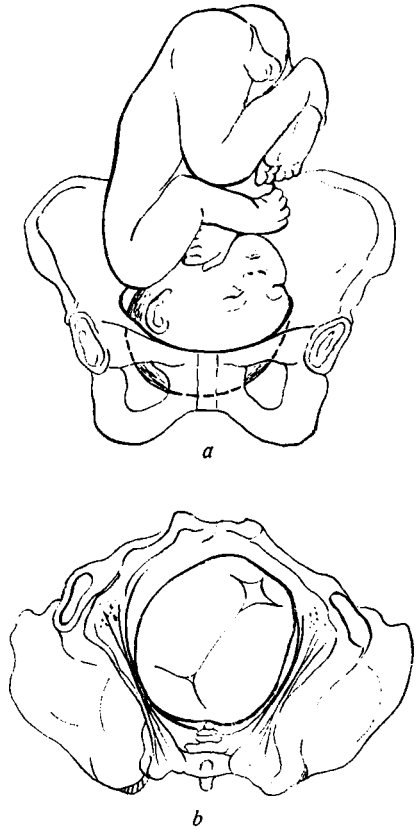

Fig. 73. *a* — longitudinal, right occiput posterior presentation, *b* — inferior view: the sagittal suture in the right oblique diameter; right posterior position of the posterior fontanelle

terior parietal bone presentation). If the sagittal suture is nearer the symphysis, it is referred to as posterior asynclitism (posterior parietal bone presentation).

Synclitism is defined as the normal state of parallelism. Slight anterior asynclitism sometimes occurs in normal labour. The phenomenon is only transient and is removed spontaneously. Marked anterior or posterior asynclitism are pathological conditions.

The mentioned positions of the foetus can be arranged orderly as follows:

I. Longitudinal Presentations:

A. Cephalic presentation

1. *Occiput presentation* (flexed)
   - Left occiput anterior (LOA) (see Fig. 70
   - Left occiput posterior (LOP) (see Fig. 72)
   - Right occiput anterior (ROA) (see Fig. 71)

Right occiput posterior (ROP) (see Fig. 73).

2. *Deflexed presentation*
   (a) Vertex presentation:
   Left occiput anterior (LOA)
   Left occiput posterior (LOP)
   Right occiput anterior (ROA)
   Right occiput posterior (ROP)
   (b) Brow presentation:
   Left fronto-anterior (LSinA)
   Left fronto-posterior (LSinP)
   Right fronto-anterior (RSinA)
   Right fronto-posterior (RSinP)
   (c) Face or mentum presentation:
   Left mento-anterior (LMA)
   Left mento-posterior (LMP)
   Right mento-anterior (RMA)
   Right mento-posterior (RMP)

B. Breech Presentation

1. *Complete breech presentation*:
   Left sacrum anterior (LSA)
   Left sacrum posterior (LSP)
   Right sacrum anterior (RSA)
   Right sacrum posterior (RSP)
2. *Incomplete breech presentation*
   Left sacrum anterior (LSA) (see Fig. 74)
   Left sacrum posterior (LSP)
   Right sacrum anterior (RSA)
   Right sacrum posterior (RSP) (see Fig. 75)
3. *Footling presentation* (double footling)
   Left anterior
   Left posterior
   Right anterior
   Right posterior

II. Transverse Presentation

Left scapula anterior (LScA)
Left scapula posterior (LScP)
Right scapula anterior (RScA)
Right scapula posterior (RScP)

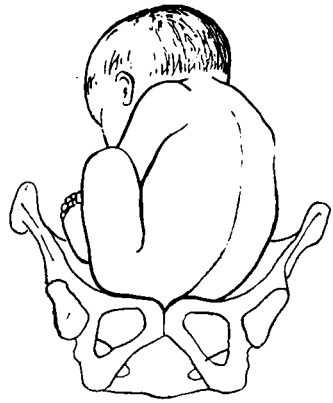

Fig. 74. Longitudinal left sacrum anterior presentation

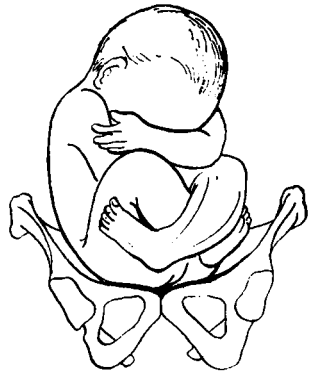

Fig. 75. Longitudinal right sacrum posterior presentation

Fig. 76. Transverse left shoulder anterior presentation

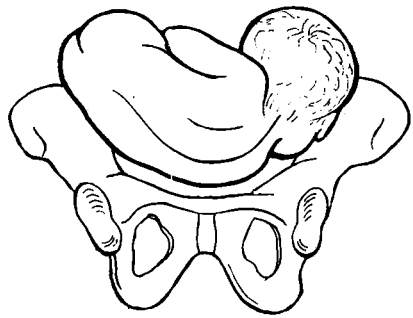

Obstetric Examination During the Second Half of Pregnancy and Labour

The main methods of obstetric examination of the woman in her second half of pregnancy and labour are *palpation* and *auscultation* of the abdomen (of the foetus in the uterus), and the *determination of the pelvic diameters*. The *vaginal examination* is obligatory

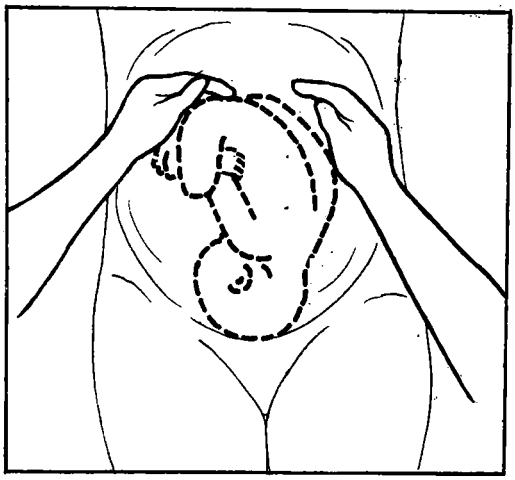

Fig. 77. The first manoeuvre

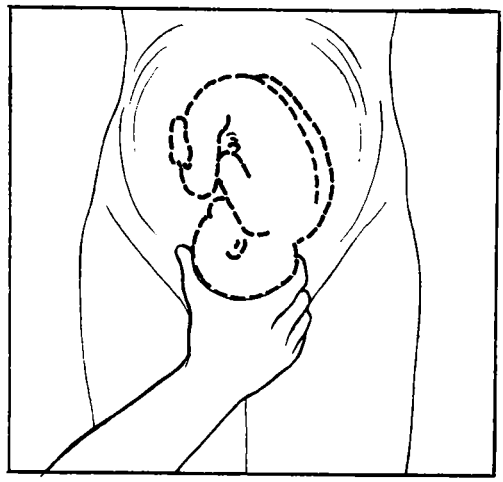

Fig. 79. The third manoeuvre

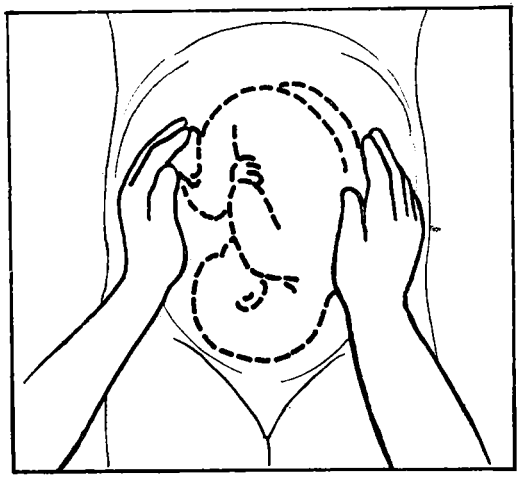

Fig. 78. The second manoeuvre

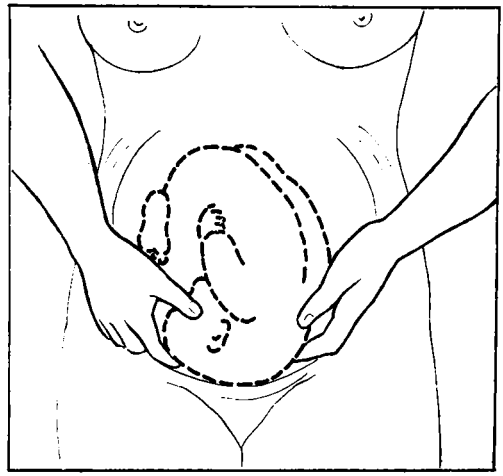

Fig. 80. The fourth manoeuvre

during labour, but it is only carried out for special indications in the second half of pregnancy. To determine the gestational age, the obstetrician should measure the girth of the abdomen, the level to which the pregnant uterus has risen, and the size of the foetus in the uterus.

Palpation. The main method of external examination of the pregnant is palpation of her abdomen. The palpation is used to identify separate parts of the foetus, to outline its habitus and reveal its position in the uterus (the presenting part, foetus position with respect to the pelvic planes, etc.), to

feel the motion of the foetus and also to assess the amount of the amniotic fluid and the condition of the uterus.

The palpation of the abdomen includes four manoeuvres according to Leopold.

The pregnant lies on her back and the obstetrician assumes the position on her right side, face to face.

The *first manoeuvre* (Fig. 77). The examining hands are placed on the bottom of the uterus and moved toward the centre to detect the upper edge of the uterus. The level of the uterus is indicative of the gestational age. The first manoeuvre demonstrates which of the foetal poles is in the uterine fundus. (As a rule the buttocks are palpated.)

The *second manoeuvre* (Fig. 78) is used to identify the back and smaller parts of the foetus. The hands of the obstetrician move downward to the navel and rest on the sides of the uterus. First the left hand remains motionless, while the fingers of the right hand feel gently the left side of the abdomen to identify the foetal parts. Then the right hand supports the side of the uterus while the left hand seeks the parts of the foetus facing the right side of the uterus. If the foetal position is longitudinal, one hand feels the foetus back while the other one feels smaller parts of the foetus. The back is located as a firm smooth object, while the small parts are felt by the examining fingers as small prominences which often change their position. The examiner can sometimes feel the jerk-like motion of the foetal extremities.

The *third manoeuvre* is designed to identify the presenting part. The obstetrician stands at the right side of the pregnant, face to face. One hand (usually the right one) is placed slightly above the symphysis pubis so that the thumb is on one side and the other four fingers on the other side of the uterine lower segment (Fig. 79). The fingers are then slowly and gently depressed into the abdomen to grasp the presenting part. The head is felt as a dense and rounded part with definite outlines.

In breech presentation the fingers feel a bulky but softer part having no rounded shape. The presenting part cannot be identified in transverse or oblique presentation.

The third manoeuvre can be used to assess mobility of the head. By slightly pushing the head the examiner tries to move it to either side. The head is ballotable, which can be readily felt by the fingers; it is especially marked in multigravida. The higher the position of the head over the pelvic inlet, the more pronounced is the ballottement.

The foetus is not ballotable if its head is fixed in the pelvic inlet and also in breech presentation.

The third manoeuvre should be performed with special care since sharp jerks induce painful sensations and reflectory tension in the muscles of the anterior abdominal wall.

The *fourth manoeuvre* is to confirm the findings of the third one and, in addition, to determine the level of the presenting part. The examiner stands by the right side of the pregnant and faces the patient's feet. The hands are placed on both sides of the lower segment of the uterus with the tips of the fingers reaching the symphysis. The fingers are then gently impressed into the abdomen in the direction of the pelvic cavity where they identify the presenting part (the head or the buttocks) and determine its level (Fig. 80). The fourth manoeuvre reveals the position of the head: whether it is over the pelvic inlet plane or has been en-





Fig. 81. Apparatus for listening to the foetal heart tones: *a* — obstetrical stethoscope, *b* — ultrasound apparatus

gaged with its smaller or larger segment. If the engagement is significant, only the base of the head can be palpated. The level of the presenting pelvic pole can be determined likewise. The fourth manoeuvre is used to determine the position of the occiput or chin if the head is presenting. As labour progresses, the degree of engagement can also be assessed by the fourth manoeuvre.

Auscultation. The abdomen of the pregnant or parturient woman is auscultated by ultrasound apparatus or an obstetric stethoscope (Fig. 81). It differs from common stethoscopes by a wider funnel which is placed on the naked abdomen (Fig. 82). The examiner can listen for the sounds using no tool, i.e. by direct auscultation, but the method is less convenient and less accurate.

Auscultation of the pregnant is used to listen for the sounds of the foetal heart. Moreover, auscultation detects other sounds occurring in the woman's body, such as (1) the murmur of the abdominal aorta which is synchronous with the maternal pulse, (2) the uterine souffle, or the blowing murmur of large blood vessels invested in the lateral walls of the uterus (also coincident with the pulse), and (3) non-rhythmic intestinal murmurs.

The sounds of the foetus are the (1) heart tones, (2) muffled, non-rhythmic jerks of the foetus, which can sometimes be heard during auscultation.

The main object of auscultation is listening for the foetal heart tones which are an absolute sign of pregnancy. The heart sounds of the foetus are informative of the general condition of the foetus which is especially important during labour.

The foetal heart tones can be heard by the second half of pregnancy (less frequently by the 18 to 19th week) and become more audible as the pregnancy progresses. The foetal heart is best heard in the area where the infant's back approximates the anterior uterine wall (closer to the foetal head). The heart is better heard through its chest only with face presentation.

With occiput presentation, the heart is best heard in the area below the navel of the pregnant, namely, on the

left side with the left position and on the right side with the right position.

The heart is heard above the navel with pelvic presentation (nearer the foetal head) on the side of the abdomen to which the foetal back approximates, i.e. on the left side with the left position and on the right side with the right position (Fig. 83).

With transverse presentation, the foetal heart is best heard at the level of the mother's navel, closer to the foetal head.

With anterior vertex and breech presentations, the heart is best heard in the area nearer the midline of the maternal abdomen, and with posterior presentations—farther from the midline, on the side of the abdomen. During engagement and also after delivery of the foetal head, the heart is best heard nearer the symphysis, almost at the midline of the abdomen.

The foetal heart is heard as rhythmic double beats at a rate of 130-140 per minute.

During labour the foetal heart tones can be slowed down physiologically which is due to the transient compression of the uterine vessels during uterine contractions. The foetal heart rate becomes normal in the periods between pains. Slowing down of the heart rate

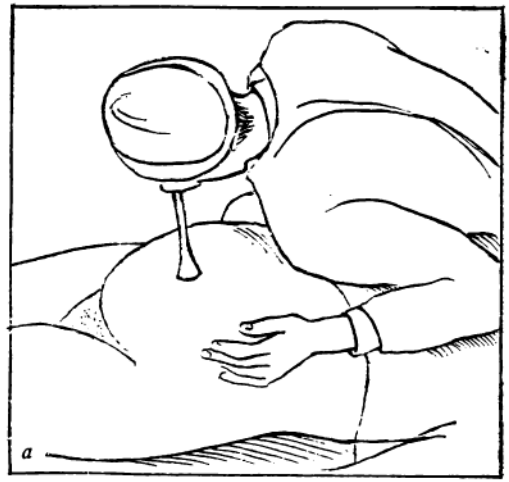

Fig. 82. Listening to the foetal heart tones using:
a — obstetrical stethoscope, *b* — ultrasound apparatus

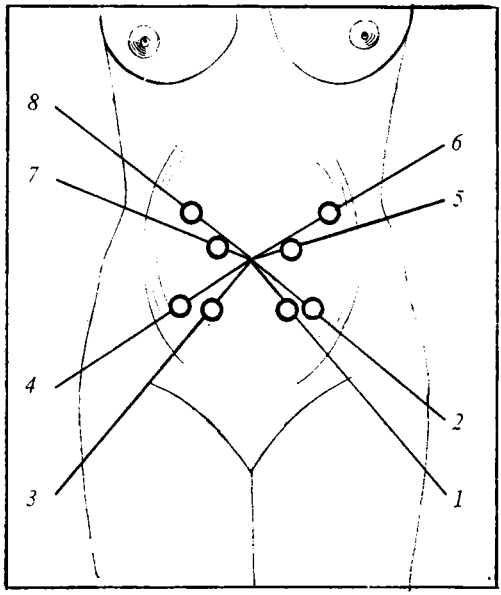

Fig. 83. Points where the foetal heart is best heard:
1 — left occiput anterior presentation, *2* — left occiput posterior presentation, *3* — right occiput anterior presentation, *4* — right occiput posterior presentation, *5* — left sacrum anterior presentation, *6* — left sacrum posterior presentation, *7* — right sacrum anterior presentation, *8* — right sacrum posterior presentation

to 110-100 beats and also its acceleration to over 150 beats per min between pains indicate possible asphyxia of the foetus.

Examination of the pelvis. The pelvis should be examined thoroughly during pregnancy and labour.

The **vaginal examination at late pregnancy and during labour.** The vaginal examination is fraught with danger of infection with pathogenic microbes which may get into the birth canal. These microbes can cause puerperal diseases.

1. All possible aseptic and antiseptic measures should be taken to preclude infection of the pregnant during the vaginal examination. The obstetrician must disinfect his hands and the external genitalia of the pregnant (parturient) before the examination (see Chapter 7).

2. The vaginal examination during the second half of pregnancy is only given if the visit to the doctor during the pregnancy is the first, and also if it is necessary to derive a more accurate judgement on the condition of the birth canal (the vagina, cervix, the inner surfaces of the pelvic bones) and to measure the diagonal conjugate.

The presenting part can be identified during late weeks of pregnancy by palpation through the vaginal fornices. The vaginal examination is therefore indicated in cases where the external palpation of the abdomen fails to reveal the position and presentation of the foetus.

3. According to the recommendations of the Ministry of Health of the USSR, the vaginal examination is given to women on their admission to the lying-in hospital and after the loss of the amniotic fluid. Further vaginal examinations are only done for special indications. These recommendations are aimed to facilitate timely diagnosis of complicated labour and to give the parturient the necessary medical aid.

The vaginal examination consists in the following.

The pregnant lies on her back with the legs flexed on the thighs, the thighs flexed on the abdomen, and abducted (Fig. 84). The hands of the examiner and the external genitalia of the pregnant are disinfected. The labia majora and labia minora are separated by the thumb and the forefinger of the left hand to inspect the pudendal cleft, the vestibule, the clitoris, the meatus, and the perineum. Next the forefinger and the middle finger of the right hand are

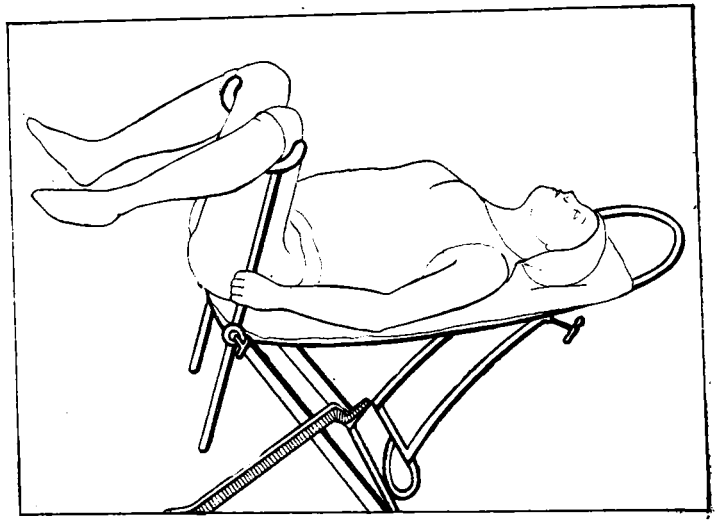

Fig. 84. Position of the pregnant during vaginal examination (lithotomy position)

gently introduced into the vagina (the thumb is raised, while the fourth and the fifth fingers are flexed and pressed against the palm) (Fig. 85).

The order of the examination is as follows:

1. The lumen of the vagina and its distensibility are determined; next the vagina is inspected for the absence of cicatrices, tumours, partitions or other pathologies.

2. The cervix is inspected and its shape, size and consistency determined. The degree of effacement (none, moderate, 100%) and maturity of the cervix are assessed in the parturient.

3. The condition of the external os of the endocervical canal (oval, slit-form, open, closed) is determined. The condition of the external os margins (soft, rigid, thick, thin) and the degree of os opening are assessed. The examiner attempts to insert the tip of one or more fingers into the external os. The degree of opening of the external os is assessed by the number of fingers that pass the opening (1, 2, 3 or 4 fingers, or complete opening).

4. The condition of the membranes is inspected (intact, ruptured, the degree of tension).

5. The presenting part is determined (the head, buttocks, legs); the descent of the presenting part is assessed: above the pelvic inlet plane; engagement with the smaller or larger segment; inside the pelvic cavity; at the pelvic outlet); the landmarks of the presenting part (sutures and fontanelles on the head, sacrum, anus, genitals on the caudal end of the foetus) are determined, and the mechanism of labour is prognosticated by the data obtained.

6. As soon as the information on the condition of the vagina, the cervix, the external os, the membranes and the presenting part has been obtained, the inner surfaces of the pelvic bones, the sacrum and the symphysis are palpated to reveal possible deformations of the pelvic bones (bony prominences, flattening of the sacrum, immovable sacro-coccygeal joint, etc.) and to assess the capacity of the pelvis.

7. The diagonal conjugate is measured finally.

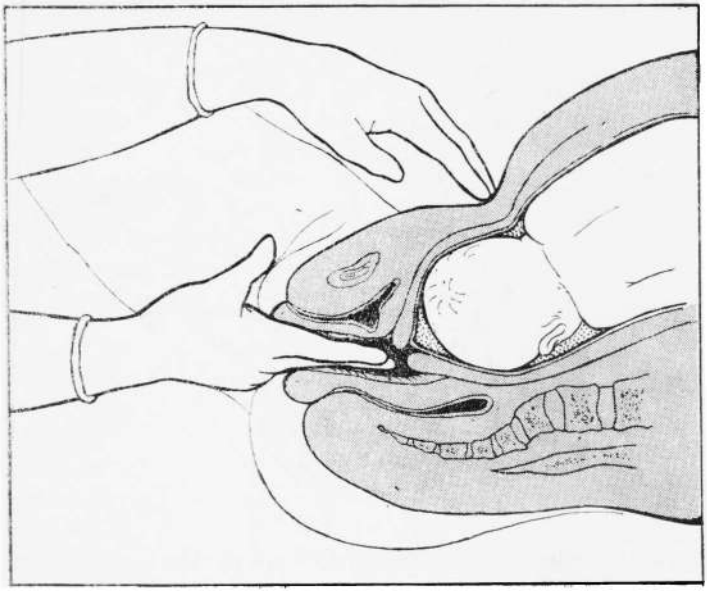

Fig. 85. Vaginal examination of the parturient

The progress of the foetal head during labour can be assessed by the Piskacek method. The forefinger and the middle finger are wrapped in sterile gauze, the finger tips are placed on the margin of the right labium majus and moved along and into the vagina, parallel to the vaginal tube, until they meet the presenting head. The fingers can reach the head if the latter is within the pelvic cavity or at the pelvic outlet. If the smaller segment is at the pelvic inlet, the Piskacek method proves ineffective.

When performing this test, special care should be taken that the fingers are not inserted into the vaginal lumen.

X-ray examination. Roentgenograms can reveal the position of the foetus and its presentation (Plate 5), multiple pregnancy, the pelvic architecture, and the diameters. X-ray examination should however be only used when the other methods (palpation, auscultation, vaginal examination, etc.) fail to give the examiner comprehensive data.

Special techniques. Electrophysiological methods (electrophonocardiography, ultrasound, amnioscopy, amniocentesis, etc.) are only used for special indications (threatened asphyxia, etc.). They are used to study the heart function of the foetus, its position and presentation.

Amnioscopy is used to inspect the condition of the membranes and the fluid (which can be seen through intact membranes). The change in the colour and clarity of the amniotic fluid (greenish, yellow, cloudy) is an indirect evidence of the developing asphyxia, haemolytic disease of the foetus, and other complications.

Amniocentesis is the perforation of the membranes to release the amniotic fluid for its examination (in suspicion for grave haemolytic disease and other complications).

Ultrasound. Ultrasound is used to listen to the foetal heart tones, to determine the size of the foetal head and pelvic diameters of the mother, the point of placental attachment, the presence of excess amniotic fluid, to reveal multiple pregnancy, etc.

Determining Gestational Age and Predicting the Time of Delivery

Determining the gestational age and predicting the time of labour are of certain importance since pregnant women are given many privileges in this country. Beginning from 1956 all working women are given a 112-day pregnancy leave (56 days before and 56 days after childbirth). The postpartum leave increases to 70 days if the labour had some complications. According to regulations of Ministry of Health of the USSR (1954), labour should be considered complicated in the following cases:

(a) multiple delivery; (b) delivery associated with, or preceded by nephropathy, preeclampsia, and eclampsia; (c) labour associated with the following obstetric operations: caesarean and other section during labour, application of forceps, classical and combined podalic version of the foetus, extraction of the foetus by its pelvic end, cutting the foetus in pieces, and manual removal of the placenta; (d) labour associated with considerable loss of blood inducing secondary anaemia (haemoglobin below 11 g%), and the related diseases; (e) labour associated with the rupture of the uterus, deep laceration of the cervix, perineal lacerations of the third degree, disjunction of the symphysis pubis; labour with subsequent puerperal diseases associated with fever persisting over eight days (grave endometritis, inflammation of the pelvic peritoneum and connective tissue, inflammation of the veins, general septic diseases, etc.); (f) labour in patients with organic cardiovascular diseases (endocarditis with anatomical affection of the heart valves, affections of the heart muscles, and persistent hypertension); active tuberculosis, diseases of the kidneys and the renal pelvis, exophthalmic goitre, diabetes mellitus and malaria exacerbated at the end of pregnancy or during labour, chronic parenchymatous affection of the liver with pronounced hepatic dysfunction; (g) premature labour (delivery of immature infant).

With the onset of pregnancy women are not admitted to night-time work. If a pregnant woman is given a lighter job, her former salary (that of six preceding months) remains unchanged.

All these privilegies are aimed to facilitate the normal course of pregnancy, to protect the woman's health and normal intrauterine growth of the foetus. Complete use of the privileges is only possible with the timely and correct determination of the gestational age.

The human pregnancy normally continues for 280 days, i.e. 40 weeks, or ten obstetrical (lunar) months, counting from the first day of the last menses.

Cases of delivering mature infants after 230-240 days of gestation have been reported. Cases of pregnancy lasting over 280 days are also known (postmature pregnancy, delayed labour).

Pregnancies lasting as long as 310-320 days were reported in the literature. The deviations from the mean duration of pregnancy present difficulties in determining the gestational age and the probable time of delivery. It

is difficult to accurately determine the time of delivery because it is impossible to establish the date of conception.

In order to determine the gestational age as accurately as possible it is necessary (1) to examine the pregnant in her early weeks of pregnancy with subsequent examinations once or twice a month; (2) to consider the anamnestic data and the results of the objective examination of the pregnant.

The exact date of the last menses and the date of the first quickening of the foetus are the anamnestic data especially important for the correct determination of the gestational age and the time of delivery.

The gestational age can be determined from the time which has passed from the first day of the last menses till the visit to the doctor.

To determine the date of delivery, 280 days (i.e. ten lunar months, or nine common months plus seven days) should be added to the first day of the last menses. There is a simpler way of dating the time of delivery: three common months are subtracted from the first day of the last menses and seven days added. For example, the first day of the last menses was October the 2nd. Subtracting three months we have the second of July. Now seven days are added to give the ninth of July. This is the probable day of delivery. If the first day of the last menses was the 20th of May, the probable date of delivery will be on the 27th of February, etc.

The first quickening of the foetus is normally felt by primigravida by the 20th week of gestation, i.e. at the middle of the full term. If the pregnancy is not the first, the first quickening of the foetus may occur two weeks earlier. If we add five lunar months in primigravida (five and a half in repeated pregnancies) to the day of the first quickening, we obtain the date of probable delivery.

In the first months of pregnancy the gestational age is determined by the size of the uterus. At terms following the third month, the level of the uterine bottom is determined, and at even later terms, the girth of the abdomen is measured and the size of the intrauterine foetus is verified.

The *size of the uterus and the level of its fundus are different at various gestational ages.* By the end of the first lunar month (four weeks) the uterus size is about that of a hen egg. It is almost impossible to diagnosticate pregnancy at this period.

By the end of the second lunar month (eight weeks of gestation) the uterus is about the size of a goose egg.

At the end of the third lunar month, the uterus is about the size of a full-term foetus head.

Beginning from the fourth month, the bottom of the uterus can be palpated through the abdominal wall and the gestational age can then be determined by its level (Fig. 86). It should be remembered that the level of the uterine bottom depends on the size of the foetus, the amount of the amniotic fluid, multiple pregnancy, malpresentation, etc. The level of the uterine bottom is therefore informative only in combination with other signs (the last menses, the first quickening, etc.).

By the end of the fourth lunar month (16 weeks of gestation) the uterine bottom is midway between the pubis and the navel (four finger-breadths above the os pubis level).

At the end of the fifth month (20 weeks) the uterine bottom is two finger-breadths below the navel; the promin-

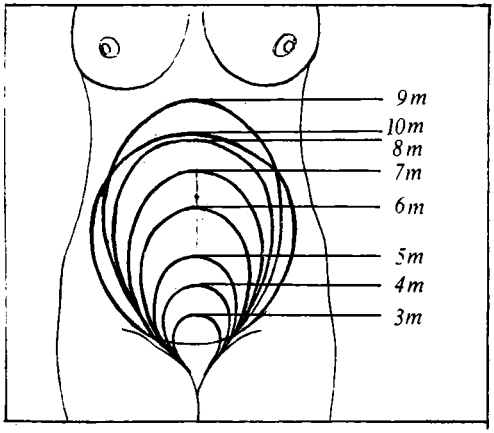

Fig. 86. Uterine levels in pregnancy

ence of the abdominal wall becomes vivid.

At the end of the sixth lunar month (24 weeks of gestation) the uterine bottom is at the level of the navel.

At the end of the seventh lunar month (28 weeks) the uterine bottom rises to the level of 2 or 3 finger-breadths above the navel.

At the end of the eighth lunar month (32 weeks) the uterine bottom is midway between the navel and the xiphoid. The navel starts levelling. The girth of the abdomen (across the navel) is 80-85 cm.

At the end of the ninth lunar month (36 weeks) the bottom rises to the xiphoid level. This is the uppermost point to which the bottom of the pregnant uterus rises. The average girth is 90 cm at this time. The navel is completely levelled.

At the end of the tenth lunar month (40 weeks of gestation) the bottom of the uterus drops to the level where it was found at the end of the eighth month, i.e. midway between the navel and the xiphoid. The navel protrudes. The girth of the abdomen is 95-98 cm. The head lowers: in primigravida it rests against the pelvic inlet or is lowered with the lesser segment into the pelvic inlet.

When the level of the uterus is the same at the eighth and the tenth lunar months, the gestational age is differentiated by the girth of the abdomen (80-85 cm at the eighth and 95-98 cm at the tenth month), by the position of the foetal head (high above the pelvic inlet plane and ballotable at the eighth month and lowered, or fixed in the pelvic inlet in primipara, at the tenth month), and by the condition of the navel (level at the eighth month and protruded at the tenth month). At the end of the tenth month the pregnant's breathing becomes easier because of 'dropping'.

The gestational age can also be determined by measuring the distance from the superior margin of the os pubis to the most prominent aspect of the uterine bottom, and by the girth of the abdomen.

The distance from the os pubis to the upper point of the uterine bottom is measured on a pregnant lying on her back with the legs extended and the bladder emptied. Using a measuring tape the following data are obtained:

Gestational age (lunar months)	Distance from os pubis to uterine bottom (cm)	Gestational age (lunar months)	Distance from os pubis to uterine bottom (cm)
4	6-7	8	28-30
5	12-13	9	32-34
6	20-24	10	28-32
7	24-28		

The tabulated data show that the distance from the upper margin of the os pubis to the uppermost point of the uterine bottom varies in women within

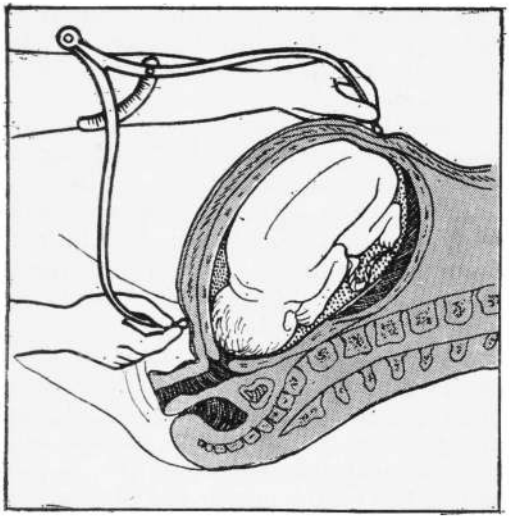

Fig. 87. Measuring the intrauterine foetus

the limits of 2 to 4 cm. The informative value of this measurement is therefore only relative.

The abdomen of the pregnant is measured by a tape during the second half of pregnancy. The girth is measured at the level of the navel anteriorly and the midpoint of the lumbar region posteriorly.

Measuring the length of the intrauterine foetus gives additional information for the determination of the gestational age. It is difficult to measure the foetus to sufficient accuracy and the measurements taken are thus only tentative.

An ordinary pelvimeter is used for the purpose. The pregnant lies on her back. (The bladder should be evacuated before taking measurements.) After identification of the foetal parts by palpation, one arm of the pelvimeter is placed on the lower pole of the foetal head while the other arm of the tool on the bottom of the uterus where the buttocks are normally situated (Fig. 87). According to V. V. Sutugin, the distance from the lower pole of the foetal head to the pelvic end is half the full length of the foetus (from the vertex to the heels). The taken measurement is therefore doubled, and 2 or 3 cm subtracted (the thickness of the abdominal wall). The obtained figure is then divided by five to determine the gestational age since during the second half of pregnancy the length of the foetus is the gestational age in months multiplied by five. For example, the distance from the lower pole of the foetal head to the pelvic end is 21 cm. This figure is doubled to give 42 cm and 2 cm subtracted. The length of the foetus is thus 40 cm. This is the length of a foetus at the end of the eighth month of its intrauterine growth (40:5=8).

Measuring the foetal head gives additional information to verify the gestational age during the second half of pregnancy. The pregnant lies on her back. The examiner palpates carefully the head of the foetus to identify its parts. The arms of the pelvimeter are then placed on the most prominent aspects of the head which are usually the sinciput and the occiput. The occipitofrontal diameter of the head at the end of the eighth month of gestation (32 weeks) is about 9.5 cm and at the end of the ninth month (35-36 weeks), 11 cm.

Dating the antepartum leave. Determining the gestational age is also important for dating the antepartum leave for pregnancy. This should be done with thorough consideration of all anamnestic data and the data of objective examinations. The first day of the last menses, the first motion of the foetus, the data collected during regular visits to the obstetrician are taken into account. Visit to the doctor in the early

weeks of pregnancy will enable the obstetrician to date accurately the probable time of delivery.

The findings may differ in women at the same gestational age of the foetus, since they depend on the size of the foetus, its position and presentation, the amounts of the amniotic fluid, the position of the presenting part, etc. The bottom of the uterus in 32 weeks of gestation is found midway between the navel and the xiphoid or slightly above this level in most women. The distance from the superior margin of the os pubis to the uppermost aspect of the uterine bottom, as measured by a tape, is 28-30 cm. The foetal head is fixed in the pelvis in primigravida and is movable in repeated pregnancies. The average occipitofrontal diameter of the foetal head is 9.5-10 cm. The girth of the maternal abdomen is 85-90 cm.

At the 36th week of pregnancy, the uterine bottom rises to the xiphoid level, the distance from the os pubis to the uppermost point of the uterine bottom being 31-32 cm. The girth of the abdomen, 90-95 cm. The head of the foetus is fixed in the pelvic inlet, and can be movable in repeated pregnancies. The occipitofrontal diameter is 11-11.5 cm.

The navel begins levelling at the 36th week of pregnancy. To verify the gestational age, the length of the intrauterine foetus is measured.

The level of the uterine bottom is 2-3 cm higher with pelvic presentations than with cephalic presentation.

Signs of Past Deliveries

The information concerning the past delivery history is obtained from the pregnant. Findings of the objective examinations also add to this information.

The signs of delivery in past history are striae (scars) on the abdomen, deep ruptures of the hymen (carunculae myrtiformes), cicatrices at points of former perineal lacerations, a wider (compared with nulliparous women) vagina, and the modified shapes of the external os (transverse slit, incomplete closure, cicatrices, etc.).

Assessing the Condition of Foetus

The obstetrician is often facing the problem of deciding whether the intrauterine foetus is alive or dead because of some pathology. During the first half of pregnancy, when the absolute signs of pregnancy are absent, this question is answered by the enlargement of the uterus. If the uterus size corresponds to the gestational age and the uterus continues enlarging, this is an evidence of the foetal life and growth.

During the second period of pregnancy the condition of the foetus is assessed by its cardiac tones and motion. Questions whether or not the foetus is alive usually arise when the heart tones are not heard by the examiner or the mother does not feel the foetus quickening. The absence of these signs is not however a direct indication of the foetus' death, since the heart tones may be inaudible because of excess amounts of the amniotic fluid, posterior presentation, malpresentation of the foetus, or obesity of the abdominal wall. If the mother does not feel the foetus quickening, it does not always indicate the foetal death either.

Foetal death can be definitely stated if the heart tones and the motion of the foetus were earlier quite vivid, but the final judgement can only be

drawn on repeated examination of the pregnant. The foetal death is manifested by the discontinuation of the growth of the uterus in addition to the absence of the heart tones and quickening. The uterus begins decreasing due to absorption of the amniotic fluid. The woman feels discomfort in the abdomen, unpleasant taste in the mouth, malaise, slight fever. The breasts become softer.

Roentgenography reveals postmortem changes in the foetal skeleton (dislocation of the cranial bones and their disjunction, abnormal flexion of the vertebral column, etc.). A sharp decrease of oestriol (an oestrogenic fraction) in the urine of the woman, and also negative findings of electrophonocardiography (the absence of bioelectrical activity of the foetal heart) are another evidence of foetal death.

Chapter Six

NUTRITION AND HYGIENE OF PREGNANCY

The changes occurring in the female body during normal pregnancy are physiological and are actually designed to adapt the woman to her new condition associated with the growth of the intrauterine foetus.

As a rule pregnancy produces a favourable effect on the woman to enhance her bloom. Pregnancy also promotes improvement or even complete recovery from many inflammatory diseases of the sexual organs originating from the preconception period.

All organs function normally during pregnancy but the load on them is increased, which is associated with the increasing requirements of the growing intrauterine foetus.

Being a physiological process, pregnancy is well tolerated by a healthy woman provided she adheres to the normal way of life. In cases of malnutrition, negligence of the hygienic requirements, overstrain, or other unfavourable environmental conditions, the normal functions of the body can be upset and complications of pregnancy develop.

The following rules should therefore be adhered to during pregnancy. Proper hygiene of the woman should (a) preserve and strengthen her health; (b) promote normal development of the intrauterine foetus; (c) favour the normal course of pregnancy and the postpartum period; (d) prepare the woman for breast feeding.

General conditions. If the woman leads normal life before pregnancy, her conduct during pregnancy need not be unusual. She should not abstain from routine activities if the pregnancy is normal. Moderate physical and mental activity produces a favourable effect on the pregnant. Work promotes normal function of the nervous, cardiovascular, haemopoietic, respiratory and other systems of the pregnant and improves her metabolism. Idle lying or sitting predisposes the pregnant to obesity, constipation, relaxation of the muscles and can cause uterine inertia during labour.

But the pregnant should avoid lifting weights, heavy jumps or overfatigue. The Soviet legislation prohibits employment of pregnant women during night time; any extraschedule work is prohibited beginning from the fourth month of pregnancy; the same holds for lifting or shifting heavy objects, exposure to elevated temperatures or chemicals that may adversely affect pregnancy.

Operating a treadle sewing machine, bicycling, horseback riding and the like exercises that involve shaking and jerking of the body, all sports connected with overstrain and jumps should be avoided.

During her free hours the pregnant should undertake short trips which however should not be lengthy or fatiguing. Walks have favourable effect

on the physical and psychic condition of the pregnant; lengthy stay in the open promotes the necessary oxygen supply to the intrauterine foetus.

Adequate sleep is essential for the normal course of pregnancy. The pregnant should sleep at least eight hours a day and avoid staying out of bed late at night (going to bed not later than at 10-11 p.m.). Walks and room airing are recommended before going to bed. The bed of the pregnant should be convenient but not too soft. The woman should better sleep on her right side or back.

Sexual intercourse should be avoided during the first or three months of pregnancy, especially so in habitual abortions and in primigravida. Changes in the uterus excitability and the blood supply which are provoked by the intercourse may stimulate abortion. Sexual intercourse is prohibited in the last two months of pregnancy, since it may become the cause of infection of the genitalia.

Alcoholic drinks and smoking are contraindicated since nicotine and alcohol produce a toxic action on the pregnant woman and the intrauterine foetus.

The pregnant woman should be protected from infections that are dangerous for both the mother and the child. Contact with patients with purulent diseases, especially of the skin, should be avoided as well, especially at the end of pregnancy.

Care of the skin. The pregnant should take special care of her skin. Cleanliness helps intensified respiration of the skin and excretion of harmful metabolites with perspiration.

The intensified excretory function of the skin facilitates the function of the kidneys which experience overload during pregnancy. Cleanliness of the skin is therefore prerequisite in adequate skin respiration and excretion of harmful metabolites with perspiration.

Showers are recommended but water should be reasonably warm. Baths should be avoided in the later weeks of gestation to prevent the possibility of intrauterine infection with the microorganisms that may be contained in water. Daily sponge baths with water at room temperature with subsequent wiping dry with a towel are recommended.

The pregnant should wash her external genitalia with warm water and soap twice a day (after thoroughly washing the hands). Douching with an ascending jet of water should be used for the purpose, or the genitals may be washed over a basin. The woman then squats over the basin and pours water from a vessel held in a less adept hand, using the other hand to wash the genitals in the direction toward the anus, not the contrary. Syringing should be avoided during pregnancy. If leukorrhoea or other pathological discharge from the vagina occurs, the pregnant should consult a doctor for examination and treatment. Special care of the mouth cavity should be taken during pregnancy as well. The teeth should be cleansed by a soft brush in the morning and the evening; the mouth should be gargled after meals. The pregnant should consult her dentist during pregnancy and treat all diseased teeth, if any, before childbirth.

The *breasts should be specially prepared during pregnancy for future nursing.* Years ago the pregnant women were recommended to treat their nipples with alcohol, tannin, fats and other substances to prevent fissures during early breast feeding. These measures however proved ineffective, and at present it is common practice to wash the breasts and the nipples daily with

soap and water at room temperature with subsequent wiping dry with a towel. This simple procedure prepares the breasts and nipples for nursing and prevents fissures of the nipples and mastitis. If the nipples are flat or inverted (Fig. 88), they should be given massage by clean fingers. The nipple is taken carefully by the thumb and the forefinger and pulled anteriorly. The procedure should last 3-4 minutes two or three times a day.

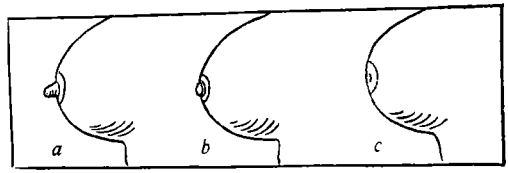

Fig. 88. Forms of nipples: *a* — normal, *b* — flat, *c* — inverted

The bras should be made of coarse textile fabric and tightly fit the breasts without pressing them (Fig. 89). The bra cups should therefore be sufficiently spacious and fit the shape and the size of the breasts.

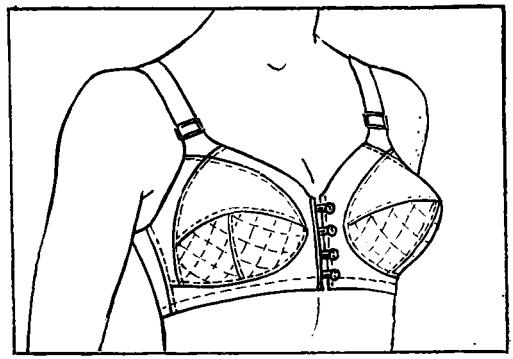

Fig. 89. Brassiere for the pregnant

Clothing. The clothing should be convenient and loose-fit, especially in the chest and abdomen (in the later months of pregnancy in particular). No round garters should be used to hold the stockings in place, and the stockinets must be without rubber on the waste, about the knees, etc. The pregnant should better wear smocklike gowns, and the skirt should preferably be held in place by suspenders so that its weight should be supported by the shoulders. The stockings should be held in place by a garter belt, and in the second half of pregnancy by an abdomen bandage. Cleanliness of clothing is of special importance during pregnancy.

The footwear should be convenient and without heels (or on low heels). High heels are not recommended because they increase the fatigue of the muscles of the spine and the lower extremities.

Abdominal bandage is indicated to pregnant women during the later months of pregnancy, especially if the pregnancy is not the first. The bandage should support the abdomen from

Fig. 90. Wearing an abdominal bandage

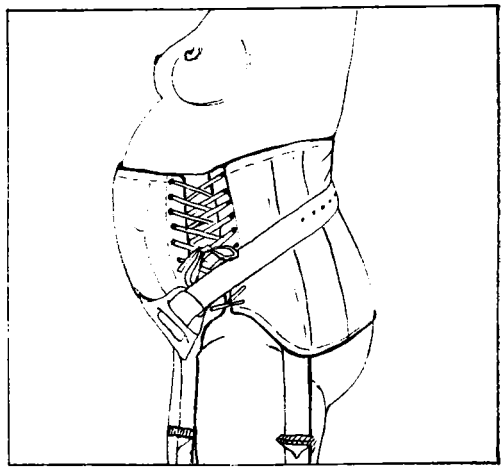

below and not compress it (Fig. 90). It should be put on in the supine position in the morning and removed before going to bed at night. The bandage will prevent excess distention of the abdominal wall and relieve the patient of the feeling of gravity in the lumbar region (strain of the spinal muscles due to the displacement of the gravity centre of the pregnant).

Nutrition. Reasonable diet during pregnancy is a prime requisite for the health of the pregnant and the normal intrauterine growth of the foetus. Malnutrition of the pregnant provokes the development of various diseases in the mother and impairs foetal intrauterine growth.

The diet is planned with consideration of (1) physiological changes occurring in the woman during her pregnancy, (2) the increased requirements for proteins, carbohydrates, fats, salts and vitamins of the pregnant and the developing foetus.

The diet during the first half of pregnancy need not be unusual and should contain all main nutritive substances. The food should be varied too.

No special limitations are imposed on the diet of the woman during the first months of her pregnancy. She is allowed to eat herrings, caviar, sour cabbage, pickled cucumbers, and other salt and piquant dishes if she feels like it. Taste would usually change only during the first months of pregnancy and by the end of the 3rd or 4th month the woman would not feel any unusual desire for special foods. Many women complain of nausea (morning sickness in particular) during their early months of pregnancy. If this is the case, the woman is recommended to take her morning food in bed and only then get up.

Dairy and vegetable products would usually be recommended to pregnant women during the second half of pregnancy; meat and fish are not prohibited but only limited. Milk, sour milk, yoghurt, curds, sour cream, butter, vegetables, potato and porridges are recommended. Fruits, berries, and unboiled vegetables (cabbage, carrots, etc.) are especially helpful since they contain many vitamins that are necessary for the health of the pregnant and the developing foetus. Meat should be limited to 3-4 times a week during the second half of pregnancy. The requirements for animal proteins should be compensated by eggs, curds, cheese and other dairy products. Milk and vegetable soups are best substituted for meat and fish ones. Alcoholic drinks, pepper, mustard, horse reddish, vinegar, spicy and piquant seasonings are prohibited.

During the second half of pregnancy the amount of salt taken with food should be minimized and water should be limited to 4-5 glasses a day.

These limitations in the diet are necessary to preclude dysfunction of the kidneys, liver and other organs on which an additional load is imposed by pregnancy.

The requirements for vitamins increase during pregnancy since they are necessary for both the pregnant and the developing foetus. Hypovitaminosis decreases the capacity for work and resistance of the body to infections. Deficiency of vitamins provokes the development of rickets, scurvy, diseases of the central nervous system, etc. Hypovitaminosis during pregnancy can cause malformations of the foetus, abortion, premature labour, etc. Foods containing vitamins necessary for the vital activity are therefore recommended for pregnant women.

Vitamin A is known as the growth

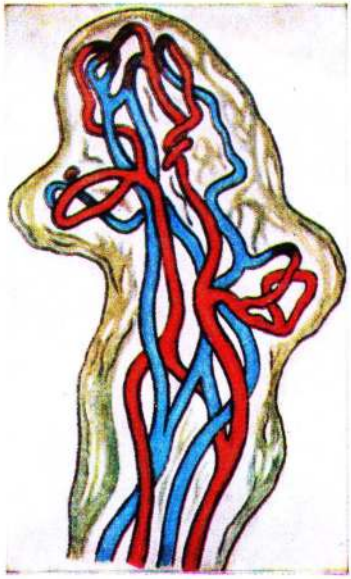

Plate 1. Villial vessels

Plate 2. Placental blood circulation: 1—umbilical arteries; 2—umbilical vein; *3*—maternal blood circulating in the intervillous space; *4*—myometrium; *5*—artery; *6*—vein; *7*—anchoring villi; *8*—decidua basalis; *9*, *10*—villi

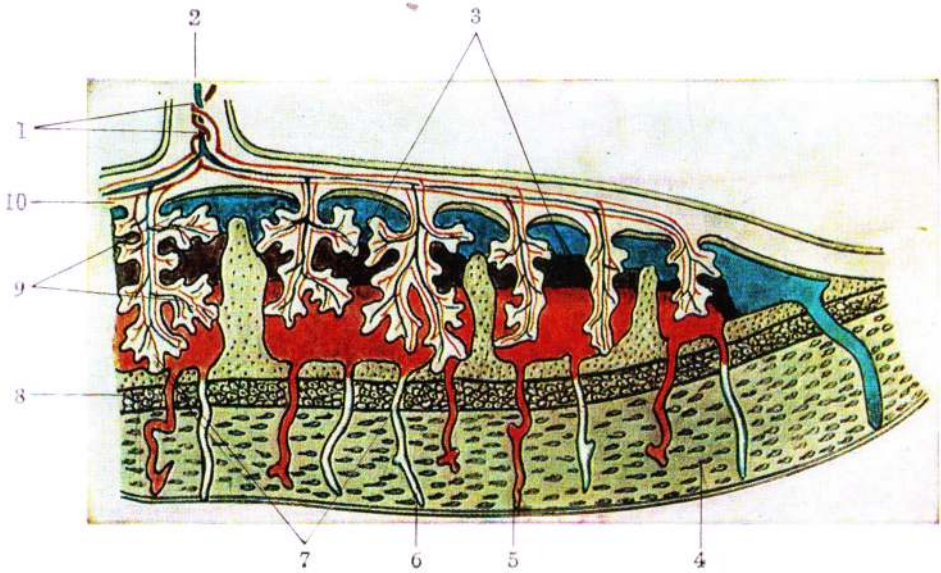

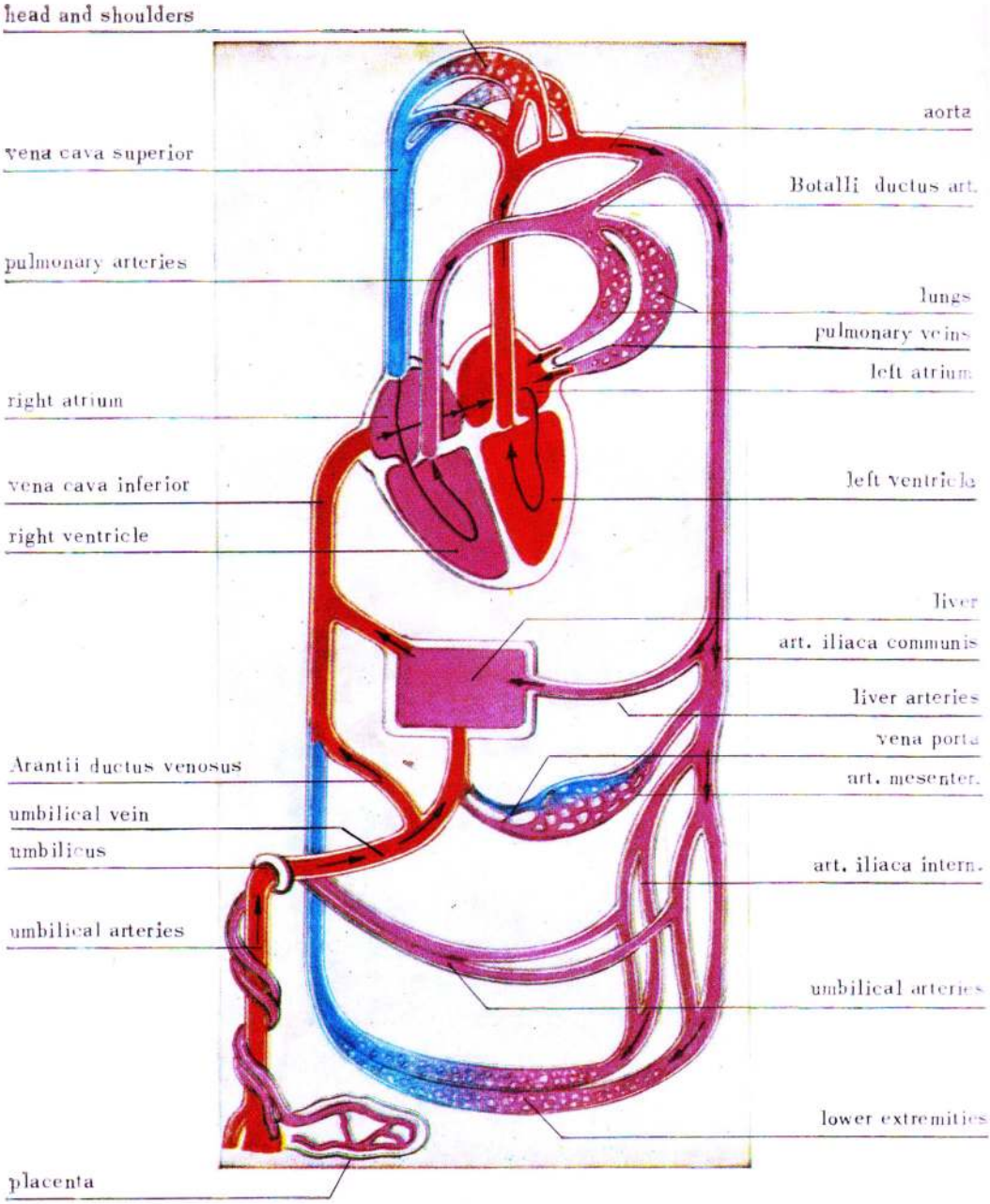

Plate 3. Foetal circulation

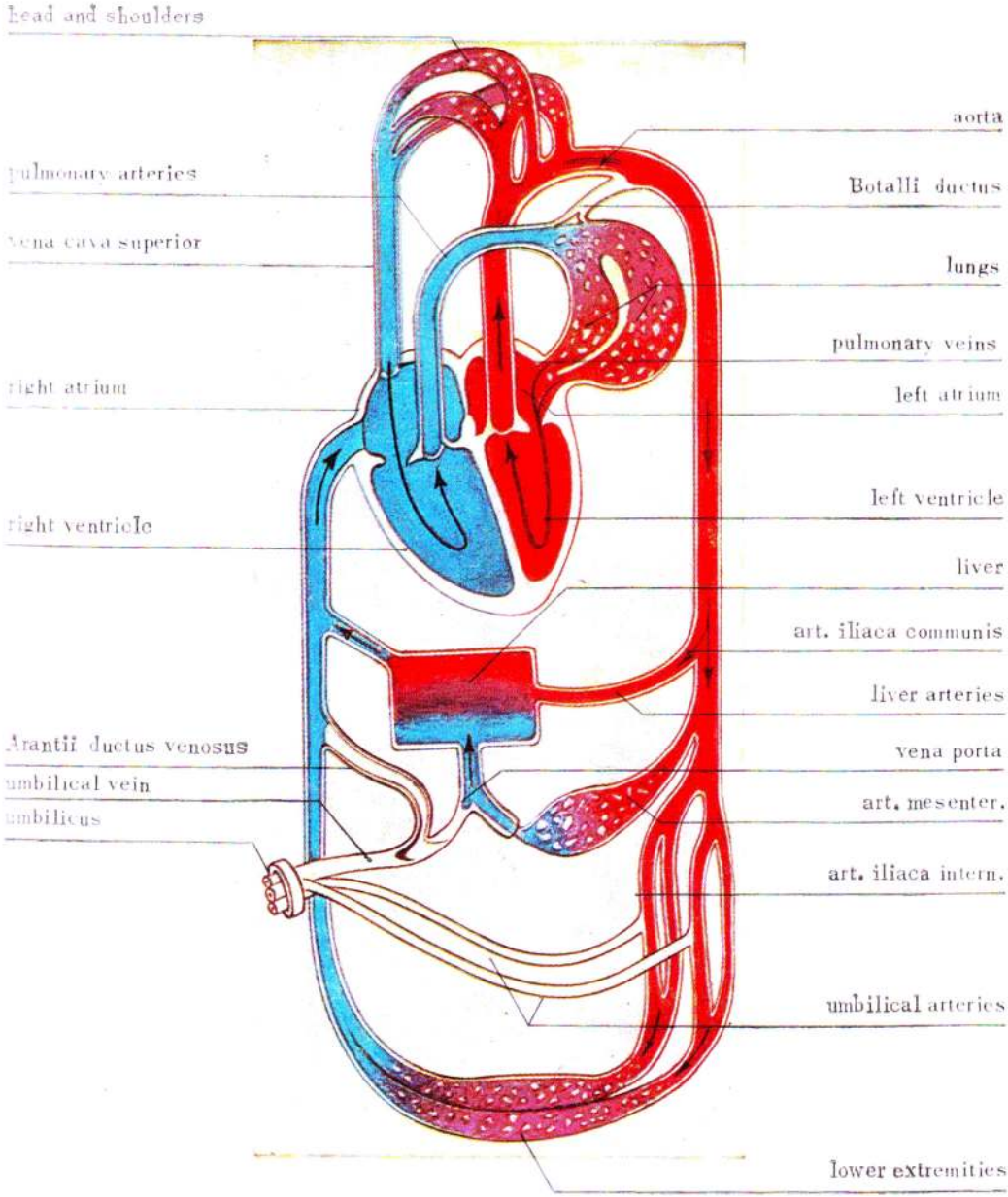

Fig. 4. Blood circulation of neonate

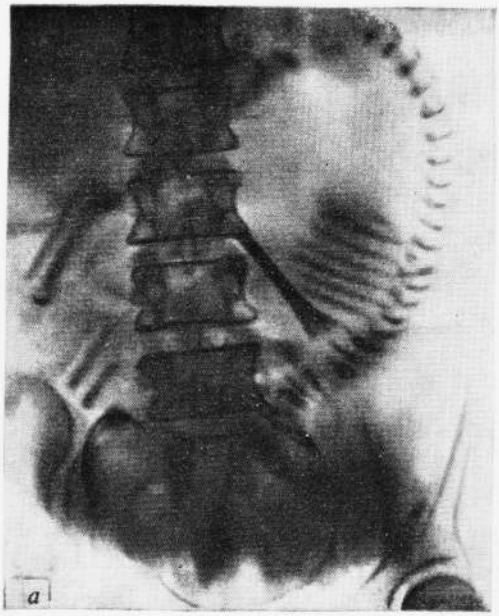

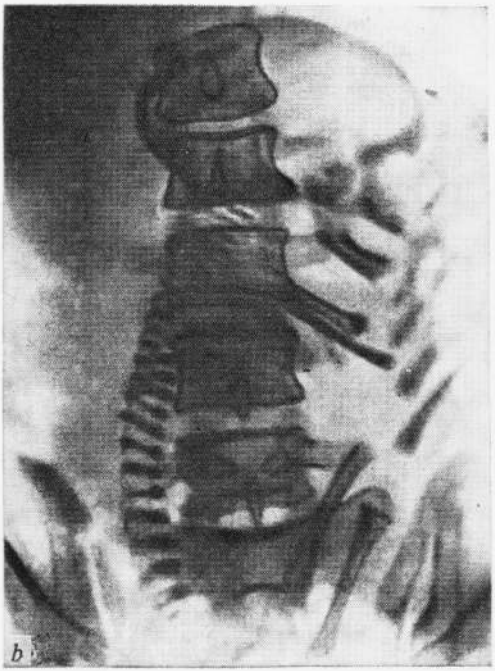

Plate 5. X-ray pattern of foetus: *a*—vertex presentation; *b*—breech presentation

vitamin. Insufficient amount of vitamin A in food retards the growth of young animals, decreases their resistance to environmental factors, causes diseases of the eyes. (xerophthalmia, night blindness), hepatic and intestinal diseases.

The liver and kidneys of animals, milk, eggs, butter, cod liver oil, carrots, and spinach contain vitamin A.

Preparation of vitamin A can be prescribed to the pregnant (dragee 2 to 4 times a day, or 1-2 drops twice a day).

Vitamin B_1 (antineuritic) takes part in the regulation of metabolism and promotes normal functioning of the nervous system. Vitamin B_1 deficiency causes grave diseases of the nervous system, muscular atrophy, and paralysis of the extremities. Vitamin B_1 is present in yeast, liver, kidneys of animals, beans, cornmeal, etc. It is also contained in brown bread. The daily requirement for vitamin B_1 is 10 to 20 mg.

Vitamin B_2 (riboflavin), the growth factor. Deficient amount of this vitamin in the body retards its growth, causes the diseases of the eyes, skin, and mucous membranes. Vitamin B_2 is present in large amounts in yeast, liver, kidneys, meat, eggs, and dairy products. The daily requirement, 2 mg.

Vitamin PP (nicotinic acid) is a constituent of the enzymatic systems involved in metabolism. Deficiency of this vitamin provokes pellagra characterized by the affection of the central and peripheral nervous systems, of the skin and mucosa, and intestinal dysfunction. Much vitamin PP is contained in yeast, liver, and wheat grains. The daily requirement, 15 mg.

Vitamin C (ascorbic acid) is involved in the oxidative processes of the body and activates the intracellular processes; vitamin C is necessary for the normal course of pregnancy. Lack of this vitamin causes the development of scurvy, and can become the cause of abortion or premature delivery. The main sources of vitamin C are vegetables, berries, fruits; especially large amounts of this vitamin are contained in the berries of sweetbrier and currants and in unripe nuts. Normally the daily requirement for vitamin C is 50 to 100 mg, but in pregnancy it increases considerably, and the pregnant should therefore take more foods containing vitamin C. Preparations containing vitamin C (dragee, tablets) or ascorbic acid preparations (Ac. ascorbinici, 0.2, Sacchari albi 0.3, three times a day) should be given to the pregnant in winter or spring.

Vitamin E is contained in the germ of the wheat and corn grains, in eggs, liver, soya bean oil, and in some animal tissues. Lack of this vitamin upsets the function of the sexual glands, affects the ovulation and conception. If the woman is pregnant, lack of vitamin E will cause abortion. This vitamin (together with other substances) is now used to treat spontaneous abortions and sterility.

Vitamin D (antirickets) is involved in the regulation of calcium and phosphorus metabolism; it precludes the development of rickets in the intrauterine foetus. Cod liver oil, flesh of fatty fishes, liver, caviar and butter are rich in vitamin D. Lack of vitamin D in the diet of the pregnant can be compensated by prescribing cod liver oil (a tablespoonful once or twice a day).

The pregnant is recommended to take food four times a day. The first breakfast should be 25-30 per cent of the daily ration, lunch 10-15%, dinner 40-50%, and supper 15-20 per cent.

The pregnant often develops the tendency to constipation. To preclude this undesirable phenomenon, the pregnant should include fresh vegetables, fruits, brown bread, and sour milk into her daily diet. Should a correct diet fail to remove constipation enema will be necessary.

Special gymnastic exercises are useful in normal pregnancy. Exercises protect the health of the pregnant and promote normal course of pregnancy, labour and postpartum period. It has been established that sportswomen and those who do exercises during pregnancy have easier labour.

Physical exercises are prescribed by a doctor and should be performed under his supervision. As soon as the woman has mastered the correct performance of her gymnastic exercises, she may continue on her own at home.

Exercises promoting respiration, blood circulation, metabolism, and the function of the nervous system are indicated to the pregnant. Exercises strengthening the abdominal and pelvic muscles are also recommended.

From the very onset of pregnancy and till its end (parturition) the woman should be under constant medical surveillance. The obstetrician and other specialists should inspect the health of the pregnant and the development of her pregnancy, give advice concerning her hygiene and diet, and take all possible measures to improve her living and working conditions. The obstetrician should take measures that the pregnant should completely use her privileges provided by the Soviet legislation. Due care of the pregnant woman helps timely reveal the initial signs of possible diseases and complications of pregnancy and take all measures to treat them correctly and in due time. Regular examinations of the woman from the early weeks of her pregnancy are very important to prevent complications of pregnancy. Health education of the female population is especially helpful in this aspect. Each pregnant should consult her doctor at least once a month during her early pregnancy and once in two weeks in the second half of pregnancy.

The pregnant should be given a thorough examination including querying, visual inspection, examination of the internal organs, obstetrical examination, etc. Their purpose is to reveal possible diseases of the cardiovascular system, kidneys, liver, and other organs, to reveal narrow pelvis, malpresentation of the foetus, haemorrhage, and other complications of pregnancy, especially those capable of provoking eclampsia (hydrops gravidarum, nephropathy, preeclampsia). It is therefore necessary that during each prenatal visit to the obstetrician the patient should be weighed, her blood pressure measured, and the urine analysed. All this is important to preclude latent oedema.

Should any signs of diseases or complications are revealed, the pregnant should immediately be examined by specialists.

Chapter Seven

ASEPSIS AND ANTISEPSIS. MEDICOPREVENTIVE OBSTETRICS

Aseptic and Antiseptic Obstetrics

After separation and delivery of the placenta, the inner surface of the uterus is a vast wound. Even if the labour is normal, the uterine cervix, the vagina and the perineum are often lacerated.

If microorganisms infect the wounded uterus, the abraded or lacerated surfaces, septic puerperal diseases may develop. The conditions which decrease the resistance of the woman (nervous overstrain, blood loss, hypovitaminosis, previous diseases, etc.) provide favourable conditions for the development of septic diseases of puerperium.

Before aseptic and antiseptic measures have been elaborated, septic diseases of puerperium (puerperal fever) were a frequent complication of labour. Outbreaks of septic puerperal diseases at lying-in hospitals were of grave epidemic character. The death rate among puerperae with septic fever was as high as 25 per cent and over. Hospitals had to close for comparatively long periods in connection with epidemic puerperal fevers.

In the middle of the past century, Ignaz P. Semmelweis, who worked at that time at an obstetric clinic in Vienna, noted that the incidence of puerperal fever and the death rate were much higher at the clinic where the students were simultaneously practicing in anatomy at the mortuary. I. P. Semmelweis suggested that the puerperal diseases might be due to the infection of the parturient women with necrotic animal tissues through insufficiently sterile tools and hands of the personnel conducting labour. The most important innovation of Semmelweis was disinfection by chlorine water of the hands of the physicians and obstetricians managing labour (1847). This simple prophylactic measure sharply reduced postpartum death rate among puerperae (to 1.5 per cent). Thus using chlorine water for disinfecting purposes has laid the foundation of antiseptic obstetrics.

Twenty years later Baron Joseph Lister disinfected dressing materials, tools, and linen which came in contact with the wound, thus becoming the father of modern aseptic surgery.

N. I. Pirogov was the first in Russia to use aseptic and antiseptic measures in surgery, and A. Ya. Krassovsky, I. F. Balandin and others in obstetrics.

Many pathogenic microbes can cause puerperal septic diseases, but staphylococci would be most common of them. Streptococcus is a less frequently occurring causative agent. Escherichia coli, Welch's bacilli, pneumococci, and other microbes can cause puerperal diseases. These pathogenic agents are found in the environment; they veg-

etate in man and do not provoke diseases in normal conditions. Septic diseases develop when these agents get on the wound surface, through which the microbes enter the body. The inner surface of the uterus, lacerations, fissures, abrasions of the cervix, vagina and the perineum become the areas of entrance of the pathogenic microbes during labour and delivery.

The sources of puerperal infections are numerous and varied. Some can reside in the body of the woman (endogenous infection). These are pyodermitis, caries, alveolar pyorrhoea, tonsillitis, and the inflammatory diseases of the urogenital system. Pathogenic microorganisms can vegetate on an intact skin of the pregnant, especially if she comes in contact with erysipelas or tonsillitis patients, and patients with purulent diseases. From its focus the infection enters the birth canal through the blood and lymph vessels, and also through the skin (from the skin into the vagina and from the vagina into the uterus).

The agents causing puerperal septic diseases often get into the body of the woman from the environment (exogenic infection). The microbes can pass into the genitals from the hands, tools, dressing materials, and other objects which may come in contact with the genitalia of the pregnant, parturient, and puerpera. Sexual intercourse in later weeks of pregnancy may also be dangerous in this respect.

The microflora of the nasopharynx (staphylococci residing here in particular) is of special importance. Minutest droplets of moisture expelled into the air from the mouth or nose during talking or by coughing and sneezing can infect the surrounding people. The droplet infection is a real danger for the parturient, and the medical personnel that contact the pregnant women must therefore wear masks.

Dust, whose particles can contain microbes, is another source of exogenous infection. When deposited, dust can infect the external genitalia with subsequent spreading into the vagina.

The main way to control puerperal septic diseases is prophylaxis, which is the main principle underlying the Soviet obstetrics. A well-substantiated system of prophylactic measures has been developed in the USSR to the effect of sharp reduction of the incidence of puerperal diseases. The fundamentals of prophylaxis of puerperal diseases are strict adherence to the rules of asepsis and antisepsis at obstetrical institutions, personal and communal hygiene, and qualified medical aid to all pregnant and parturient women.

Prophylaxis during pregnancy. The effective prevention of puerperal diseases depends on the adherence to the rules of personal hygiene described in Ch. 6. The removal of endogenous foci of infection (sanation of the mouth, treatment of pyodermitis, tonsillitis and other inflammatory diseases), isolation from contact with patients with infectious diseases, cleanliness of the skin, abstinence from sexual intercourse during later weeks of pregnancy are especially important in this aspect. Correct way of life and reasonable diet, which strengthen the health of the pregnant, are another preventive measure.

Prevention of sepsis during labour. All parturient women should be examined on admission to the lying-in hospital. All women with fever, pyodermitis, tonsillitis, influenza, gonorrhoea and other inflammatory diseases should be isolated from healthy parturient women in

a separate (the second) obstetrical ward (department). The parturient who had contact with infectious patients during the last days prior to admission, and also puerperae who had their delivery at home (where the aseptic conditions were absent) are also placed into the second obstetrical department. On admission to the hospital the parturient undergoes a special hygienic treatment: her haired areas of the body are inspected thoroughly, her nails on the fingers and toes are cut, the bladder and bowels are emptied, the hair of the perigenital and axillary areas is shaven, the external genitalia and the armpits are washed and wiped dry. The parturient is then given a shower, dressed in clean clothes, and placed in the prenatal ward. The woman delivers a baby in a special room which is as clean as the room for operation on the internal organs.

All objects that may come in contact with the parturient should be sterile. The linen, stockings, underlying napkins, dressing materials should be sterilized in an autoclave. The obstetrical tools should be sterilized in boiling water for ten minutes. To prevent rusting of the metal tools, one tablespoonful of soda (sodium carbonate) should be added per litre of water. Syringes, rubber catheters, brushes for hand washing should also be sterilized by boiling in water. The cutting tools should be sterilized with alcohol or by boiling in water (wrapped in cotton wool).

The disinfection of the hands is essentially important in obstetrical practice. The hands always carry many various microbes on them (pathogenic microbes included). The microbes are present in fat that covers the skin, in the outer portions of sebaceous glands and in the outlets of the sweat glands.

If the hands are treated properly, they can practically be sterile.

The Kochergin-Spasokukotsky and Fürbringer methods of disinfection are most effective.

Before treating hands by any known method, the nails should obligatory be cut short and dirt removed from under them by a brush.

The *Kochergin-Spasokukotsky method.* 1. Treat an enamelled basin with alcohol and then hold over a fire. Cool and place 0.5 per cent ammonia solution in it. Wash the forearms in the solution (to the elbow), and wipe them with gauze for three minutes. Pay special care to wipe dry the areas around the nails, folds on the joints, and the skin between the fingers.

2. Place a fresh portion of the 0.5 per cent ammonia solution and wash the hands again for three minutes using a napkin.

3. Wipe the hands dry using a sterile napkin.

4. Soak another sterile gauze napkin with alcohol and wipe the hands for five minutes.

The *Fürbringer method.* 1. Wash the forearms (to the elbow) for ten minutes with soap (using two brushes) in a stream of warm water.

2. Dry the hands using the napkin and wipe with alcohol for three to five minutes.

3. Apply iodine tincture (Fürbringer suggested that after treating the hands with alcohol, a 1:1000 solution of corrosive sublimate be used, but this chemical agent should be avoided in obstetrical practice since it is absorbed in the loosened mucosa of the vagina of the pregnant and parturient women).

The *Ahlfeld method.* 1. The forearms should be washed for ten minutes using soap and two sterile brushes (each

brush for five minutes) in a stream of warm water.

2. Rinse the hands and wipe dry using a sterile gauze napkin.

3. Wipe the hands for five minutes with a sterile napkin soaked in alcohol.

It is recommended that rubber gloves should be put on the treated hands.

The hands should be treated according to Kochergin-Spasokukotsky, Ahlfeld or Fürbringer before the following procedures:

(a) vagina examination of the parturient;

(b) conducting labour;

(c) obstetrical operations (manual separation of the placenta, application of forceps, suturing lacerations, etc.);

(d) manipulations with the newborn.

Obstetrical personnel should always wash their hands before they proceed to their routine duties in the delivery room, before they give external examination to the parturient and puerperal women or take care of the neonate, etc. The hands should be protected from contamination or else from injuries, which will interfere with their thorough disinfection.

During labour the external genitalia should be washed at 5-6 hour intervals. A disinfected bedpan should be placed under the sacral region of the parturient and the genitals washed with a dilute disinfectant solution (1% lysoform solution, 1:6000 to 1:8000 solution of potassium permanganate) using sterile cotton wool held in forceps.

The procedure should be performed as follows. First washed is the pubic region, then follow the inner surfaces of the thighs, the external genitalia, and finally the perineum and the anus. Wiping should be done in the same sequence, using sterile cotton wool and forceps.

Immediately before delivery, the external genitalia and the adjacent areas are washed with warm boiled water as described above, wiped dry with sterile cotton wool held in forceps, and wiped with alcohol. Finally a 5 per cent iodine tincture is applied. The parturient is dressed in sterile clothes, textile stockings, and placed on sterile linen.

Individual hygiene of lying-in hospital personnel. The medical personnel of the lying-in hospital should do their best to keep themselves free from pathogenic microbes that can cause puerperal diseases. Personnel with influenza, tonsillitis, pyodermitis or other purulent diseases, or any person who was in contact with such patients, purulent wounds and other sources of infection should not be admitted to the parturient. Persons with hands affected by eczema, abscesses, abrasions, fissures, etc., should not be employed at lying-in hospitals. The medical personnel that take care of the puerperae and neonates should be examined regularly for the timely detection of bacilli carriers. The microflora of their hands, mouth and nose should also be examined systematically. Employment of carriers of pathogenic microbes at maternity homes is prohibited.

Before beginning the shift, the medical personnel of the lying-in hospital should have a shower, change the underwear and put on a gown made of fabric that is easy to wash (linen, cotton) and an overall with a kerchief. The sleeves should be rolled up above the elbow, which is important for frequent hand washing and disinfection.

The overall should be boiled and ironed. It must cover the clothes worn underneath. To conduct labour the obstetrician should put on a sterile overall and an oil-cloth apron over it.

The kerchief should cover the hair

completely. The medical personnel should obligatory wear a mask to cover their mouth and nose when they work in the delivery and neonate rooms. The correct wearing of a mask will preclude droplet infection of the puerperae and infants, since the microbes expelled from the mouth and the nose will be held by the mask. The mask should be made of a dense white fabric (calico, linen) or of 3-4 layers of gauze. The mask soon becomes laden with microbes and its absorbing capacity thus reduced. It should therefore be renewed twice during the working shift. Used masks should be collected in a special container, washed, and disinfected by boiling or in an autoclave.

The hygienic conditions of a lying-in hospital. The building should be kept absolutely clean and repaired at least once a year. All wards, corridors, passages, lavatories and auxiliary rooms should be cleansed with a wet cloth and aired at least twice a day. The air of the delivery and the newborn rooms should be tested bacteriologically at regular intervals. The delivery room, the prenatal room and the rooms for puerperae and neonates should be given a thorough sanitary treatment once a week or ten days. The wards should be alternately freed, aired, and the windows, floors and the walls coated with oil paints, as well as the furniture and the beds should be washed with soap and water and wiped with chloramine or corrosive sublimate solution. The beds should be made with clean mattresses, linen and blankets. The walls and the furniture should be irradiated with a mercury-quartz lamp which adds to disinfection of the objects which will come in contact with the parturients, puerperae, and newborns.

The delivery bed is made with thin mattresses in oil-cloth cases and clean linen. The oil-cloth is washed after the delivery and disinfected. Sterile linen is used to make the bed during labour.

The postnatal rooms are treated as follows. As soon as a previous puerpera is discharged from the lying-in hospital the bed is washed, the mattress, the pillow and the blanket are aired for 12-24 hours, and exposed to sun rays, if possible. If the previous puerpera had fever, the mattress, the pillow and the blanket should be disinfected. The oil-cloth is washed with warm water and soap and then treated with a solution of corrosive sublimate, lysoform or chloramine.

Used linen, underwear, towels and napkins should be collected in special containers in a separate room and then laundered as soon as possible. The linen of the lying-in hospital should be laundered separately from articles belonging to other medical establishments which is especially important for prophylaxis of infection. The linen is boiled, ironed, and kept in special cabinets. Sterile articles are kept in special drums. The bed linen and underwear should be changed as often as necessary; the underlying napkins should be changed at least twice a day; the underlying oil-cloths should be renewed two or three times a day. The oil-cloths are washed with warm water, soap and a brush, rinsed, and treated with a disinfectant solution (the sublimate, lysoform, chloramine), dried and kept in a sterile bag.

Sterilization of bedpans is important in the prevention of puerperal diseases. Each parturient and puerperal woman should be given a separate bedpan for individual use. The bedpans are washed with water, boiled in a special vat

for 10-15 minutes, and kept before use in a special container or a sterile bag. After each use the bedpan is washed in a stream of water, rinsed by a disinfectant solution (chloramine, lysoform) and placed under the bed on a special support. All care of puerperae should be done with observation of rules aimed to prevent infection.

Isolation of puerperae is another important measure to preclude diseases. As soon as a puerpera develops any signs of diseases (elevated body temperature, pyodermitis, furunculosis, influenza, etc.), she is moved to the second obstetric department (ward), or (if the lying-in hospital is small) into a separate isolated room.

No relatives are admitted to the lying-in hospitals which is very important for the prophylaxis of infections.

In addition to the described prophylactic measures, it is necessary to explain to the puerperae the importance of the aseptic and antiseptic regulations for the normal course of the postpartum period and the health of the newborn.

Prophylaxis at Obstetric Institutions

The care of the pregnant, parturient, puerperae or gynaecological patients should be done with observation of the medico-prophylactic requirements.

These are a system of special measures that produce a favourable effect on the nervous system of the woman and remove undesirable psychic effects, the sense of uncertainty, etc. The medico-prophylactic conditions include confidential relationship between the woman and the medical personnel and promote the development of the firm belief that the outcome of the delivery or disease will be successful. The success of the medico-prophylactic measures depends to a great extent on the professional skill of the obstetric personnel. The appearance of the hospital, cleanliness of all rooms and the surrounding areas are also important. The medico-prophylactic measures mainly depend on the correct organization of service to women at the obstetric institutions. The service should be so organized that from her first visit to the doctor the woman should feel that proper care should be taken of her future baby and herself.

The obstetrical personnel should be tactful and considerate. The general and special examinations should be very careful and thorough. All advice concerning the personal hygiene of the woman, diet, and other aspects of her life should be given in a clear and benevolent form. The obstetrician should be very considerate when he reveals possible complications of pregnancy or gynaecological diseases. He should put his opinion in a tactful manner and explain the necessity of consulting a specialist. The obstetrician should also persuade the patient that she is out of danger, and that the outcome of her pregnancy or disease will be successful.

Out-patient examination and supervision is also very helpful.

The personnel of a lying-in hospital should be very tactful and considerate as well. The adequate treatment of the pregnant and parturient women is an important measure, on which largely depends the success of prophylaxis.

The personnel should be polite and talk with one another in a calm and benevolent manner.

The general atmosphere in the lying-in hospital should be quieting to preclude the development of any fear in the parturient for her health and the health of her baby. Silence, order, the absence of undue fuss in the work of the personnel should favourably affect the nervous system of the woman. The internal regulations of the lying-in hospital should give sufficient time for adequate sleep of the pregnant, puerperae, or gynaecological patients. In addition to nocturnal sleep, the women should be given the chance for rest during the daytime, which is especially important for nursing mothers.

The medical personnel should not converse in the presence of patients on any extraneous subjects or give their unfavourable prognosis of the course of pregnancy, labour, operation, etc.

If any operation is indicated to the patient, she should be informed in a careful and considerate manner so that she might feel confident in the successful outcome of the operation or any other intervention. The puerperae should be daily informed of the condition of their infants to preclude the development of undue fears.

Special exercises are very important for women after childbirth. These should strengthen the entire body of the woman, the nervous system included.

Health education is another important point in the prophylactic measures of a lying-in hospital. The parturients and puerperas should be given the necessary information concerning their personal and communal hygiene, recommendations for diet, nursing rules and care of their neonates.

Psychoprophylaxis and pain relief in labour and delivery is an integral part of health education of the pregnant and parturient women during their prenatal visits to the doctor and their stay in the lying-in hospital. Psychoprophylaxis is an important item of the medico-preventive measures.

The obstetrician should take proper care not only of prophylactic measures but also socio-legal welfare of the women, especially unweds and those having many children to relieve them of undue concern and anxiety.

Chapter Eight

LABOUR AND DELIVERY

Labour is the physiological process by which the foetus and the placenta are expelled from the uterus through the birth canal. Normally labour begins in 280 days (ten lunar months or 40 weeks) of pregnancy, when the foetus becomes mature and capable of extra-uterine existence.

The Cause of Labour

Many theories have been offered to explain the cause of labour. By some of them, labour begins when the placenta degenerates at the end of pregnancy and the communication between the mother and the foetus is disrupted. According to other theories, labour begins due to ultimate distension of the uterus at the end of pregnancy, the production of special substances in the maternal body which cause anaphylactic-type reactions, etc.

Many earlier advanced hypotheses were not scientifically grounded.

The causes of labour still remain unknown because of their complexity. But it has been established by now that certain changes occur in the maternal body by the end of pregnancy the combination of which provokes labour. The excitability of the cerebral cortex considerably decreases by this time, while of the spinal cord, increases. The excitability of the nervous elements and muscles of the uterus increases too. The uterus becomes very sensitive to mechanical, chemical and other stimuli of both endogenous and exogenous character. During later months of pregnancy the rate of the foetal growth exceeds the rate at which the amniotic fluid accumulates in the uterus. The foetal parts therefore become nearer the uterine walls than in the earlier months. The presenting part lowers and acts on the nerve plexus in the lower uterine segment and the periuterine connective tissue at the level of the internal os. At the end of pregnancy, the production of chemical substances stimulating the nerve elements of the uterus is intensified to increase the tone of the uterus and its contractility.

During later months of pregnancy, especially by the onset of labour, the oestrogen production increases to intensify the tone of the uterus and its sensitivity to substances provoking its contractions. At the same time the level of progesterone, which inhibits the uterine contractility, lowers by that time.

The action of oxytocin, the hormone of the posterior pituitary, becomes especially effective against the background of the increased uterine excitability, the more so that its production increases at the end of pregnancy. Oxytocin is well known as an agent intensifying contractility of the uterus.

Acetylcholine and other biologically potent substances are produced in greater amounts by the end of pregnancy to intensify and maintain con-

tractility of the uterus (like oxytocin). The motor function of the uterus is also intensified by the increased amount of calcium in the blood and the uterine muscles. The level of magnesium salts, which inhibit uterine contractility, decreases before labour. The excitability and contractility of the uterus increase by the end of pregnancy due to accumulation in the uterine musculature of the actomyosin, glycogen, phosphocreatinine, glutathione, and other substances.

To summarize, later weeks of pregnancy are characterized on the one hand by the increased excitability of the uterus, and on the other by the increased amount of mechanical and chemical stimulants (motion of the foetus, descent of its head, intensified production of pituitrin, acetylcholine, etc.), which all act on the nerve elements of the uterus.

Prostaglandins, kinins and other biologically active substances have their effect on the uterine contractility.

When the uterine excitability and the strength of stimuli attain a certain level, regular labour activity begins.

Labour is a complicated process evoked by the reflectory pathways and regulated by the nervous system. Each contraction of the uterus is accompanied by stimulation of its nervous elements, which secrete biologically active substances (acetylcholine, sympathin) to evoke a new contraction. These processes are repeated till the end of labour.

Precursors and Onset of Labour

The nearing onset of labour is manifested by certain signs known as precursors, which are as follows:

1. At the end of pregnancy (normally 2-3 weeks before labour) the uterine bottom 'drops' to release the pressure on the diaphragm. The woman now breathes easier.
2. The presenting part lowers. The head of the foetus presses against the pelvic inlet or even becomes engaged with its smaller segment (in primiparae).
3. On the eve of labour the cervix shows signs of 'maturity': it becomes positioned along the axis of the pelvis, markedly softened, and slightly shortened. If the labour is not the first, the endocervical canal passes a finger. The subsequent shortening and levelling of the cervix (effacement) and its dilation occur during labour.
4. A thick mucigenous secretion from the cervix is often discharged before the onset of labour.
5. Many women feel contractions of the uterus at the end of pregnancy. Before the onset of labour they feel dull pain in the sacral region and in the lower abdomen.
6. If the body weight is measured frequently, a slight decrease in the mass of the woman precedes the onset of labour which is due to intensified liberation of fluids from the body.

The most obvious signs of the nearing labour are irregular contractions of the uterus and the discharge of the cervical mucus from the vagina.

The *development of regular contractions of the uterine muscles, known as pains*, is the onset of labour. First pains develop at 10-15 minute intervals, then their frequency and strength increase.

The second positive sign of the nearing labour is the effacement of the cervix.

From the onset of labour till its end the woman is called a parturient.

Forces of Labour

The forces of labour include (1) the rhythmic contractions of the uterine musculature, and (2) the contractions of the mother's abdominal muscles.

The contractions of the uterine muscles are the main force of labour. They cause the cervix of the uterus to efface and dilate which is necessary to expel the foetus and the placenta from the uterus.

As soon as the cervix is effaced and dilated, the efficiency of the uterine contractions is reinforced by the contractions of the abdominal muscles. Thus, the delivery of the foetus into external environment is the result of the simultaneous and cooperative contractions of both the uterine and abdominal muscles. The contractions of the uterine muscles cause separation of the placenta from the uterine walls and its expulsion (placental stage of labour). And finally, the uterine muscles contract rhythmically for a certain period of time following the delivery (postlabour pains).

The uterine contractions are evoked spontaneously and the parturient cannot control them at her wish. They follow at regular intervals known as pause. The uterine contractions are usually painful but the subjective evaluation of pains varies greatly in women.

The contractions begin in the region of the fundus and the tube angles and extend rapidly onto the entire musculature of the uterus to its lower segment. Smooth muscles are less abundant in the lower segment and it is therefore stretched and thinned during labour.

Each labour pain develops in a certain sequence. The uterine contractions gradually increase to attain their maximum which is then followed by relaxation of the muscles and a pause. By manual examination the obstetrician can clearly feel how the uterus becomes firm and then its muscles relax.

First the contractions continue for 10-15 sec while by the end of labour they last for about a minute. During the initial stage of labour the contractions are repeated at 20-15 or 10 minute intervals but then this frequency increases and by the end of the expulsive stage they follow at 2-3 minute intervals or even more frequently.

The second component of the labour force are the contractions of the striated muscles of the prelum and the diaphragm. They develop through the reflectory mechanism due to the excitation by the presenting part of the nerve elements of the cervix, the parametrial connective tissue, and the muscles of the pelvic floor. The contractions are involuntary but the parturient can to a certain degree control them. By the request of the obstetrician conducting labour, the parturient can strengthen or lessen the contractions of the abdominal muscles.

The increased intrauterine and abdominal pressure (i.e. the contractions of the uterine and abdominal muscles) pushes the uterine contents in the direction of lower resistance, i.e. toward the small pelvis.

Stages of Labour

Three stages of labour are distinguished, namely, the stage of dilation (effacement) of the cervix, the expulsion of the foetus, and the postpartum period.

The first stage of labour begins from the onset of regular contractions of the

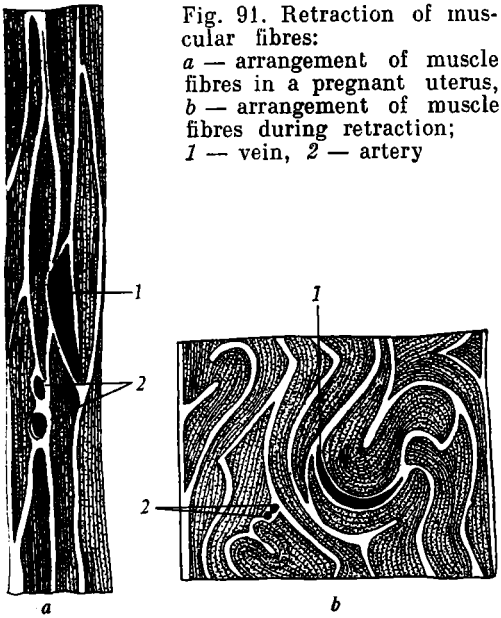

Fig. 91. Retraction of muscular fibres:
a — arrangement of muscle fibres in a pregnant uterus, *b* — arrangement of muscle fibres during retraction; *1* — vein, *2* — artery

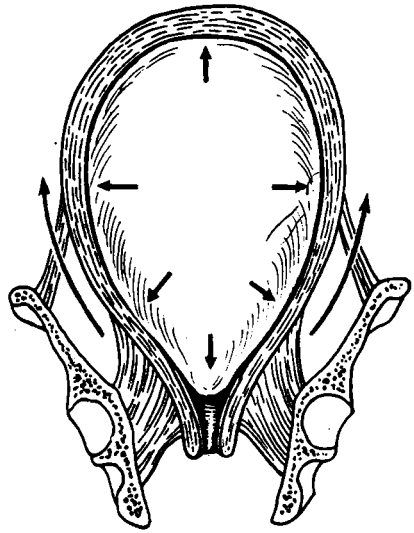

Fig. 92. By the downward thrust of the uterine contractions, the membranes containing the amniotic fluid enter the endocervical canal to act as a hydrostatic dilator

uterus and ends when the cervix is fully dilated. The second stage is the period between the attainment of dilation of the cervical os and complete expulsion of the foetus.

The third stage begins with the delivery of the foetus and ends with the delivery of the placenta.

Dilation

During the first stage of labour, the cervix of the uterus is effaced and the external os of the endocervical canal is dilated to the extent that ensures the passage of the foetus from the uterus. The cervical os is effaced and dilated by the action of the uterine contractions. The following processes occur in the uterine muscles during their contractions:

(1) contractions of the muscles proper;

(2) displacement of the contracted muscle fibres relative to one another, or retraction (Fig. 91).

Before the onset of labour, the muscle fibres are arranged one along another, but during contractions of the uterus they shorten, their arrangement becomes disordered, and they maintain their new arrangement in the intervals between contractions. Each new contraction of the uterine muscles intensifies the retraction of the muscle fibres to thicken the walls of the uterus (brachystasis), to thin its lower segment (mecystasis), to efface the cervix, and to dilate the external os. This happens because the longitudinal muscles of the uterine body pull the circular muscles laterally and superiorly (distraction of the cervix). Each next contraction of the uterus increases the degree of dilation of the endocervical canal.

The dilation of the cervix is also promoted by the pressure of the am-

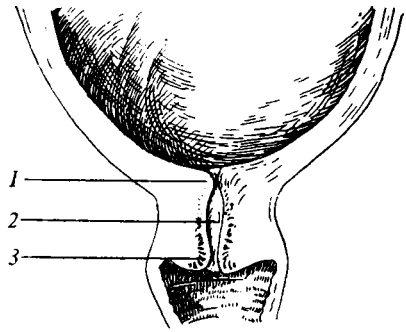

Fig. 93. The cervix of a primipara before the onset of labour:
1 — the internal os is closed, *2* — the endocervical canal, *3* — the external os is closed

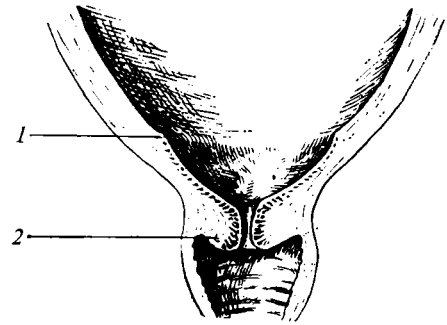

Fig. 94. The cervix of a primipara during the dilation stage; effacement:
1 — former internal os, *2* — external os is closed

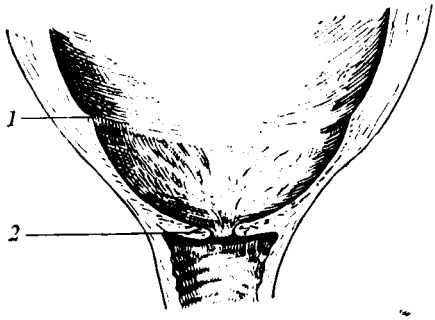

Fig. 95. The cervix of a primipara during dilation; effaced cervix: *1* — former internal os, *2* — external (obstetrical) os passes one finger

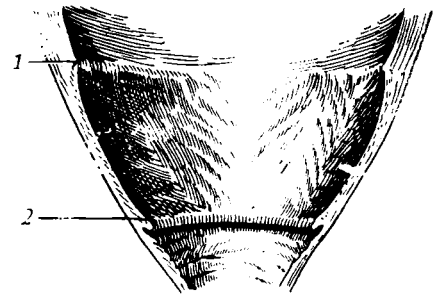

Fig. 96. The uterus of a primipara. The cervix is effaced and the external os completely dilated:
1 — former internal os, *2* — the margin of the external os (a narrow ridge-like structure)

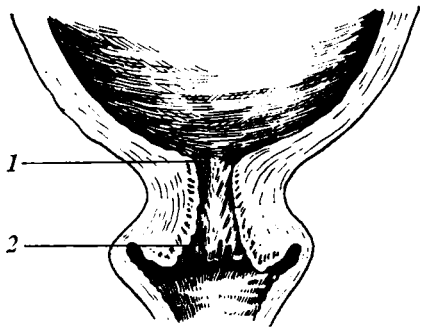

Fig. 97. The cervix of a multipara. Beginning dilation: *1* — internal os, *2* — external os, the endocervical canal passes one finger

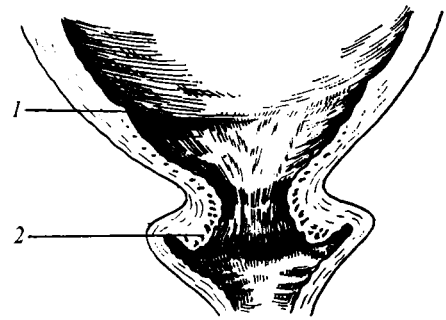

Fig. 98. The cervix of a multipara. Effacement of the upper portion of the cervix and opening of the external os:
1 — former internal os, *2* — external os (opens simultaneously with the internal os)

niotic fluid on the cervix. Each contraction of the uterine muscles exerts pressure on the conceptus and especially on the amniotic fluid. The even thrust of the uterine bottom and walls on the fluids presses them into the region of the internal os where the pressure is absent (Fig. 92). Under the pressure of the amniotic fluid, the lower pole of the conceptus separates from the uterine walls and egresses into the internal os of the endocervical canal.

Each contraction of the uterus causes the intact foetal membranes to further egress into the upper cervix.

The cervix is thus dilated by (a) the distension of the circular musculature of the uterine cervix (distraction) due to contraction of longitudinal muscles of the uterus; (b) the egress of the intact foetal membranes into the upper cervix which thus act as a hydrostatic dilator.

The main factor responsible for the dilation of the cervix is the contractility of the uterus which is also responsible for the distraction of the cervix and the elevation of the intrauterine pressure, which in turn tenses the foetal membranes and causes them enter the internal cervical os.

The retraction of the uterine muscles and their shortening causes the uterus move upwards off the conceptus, but this movement is opposed by the ligaments of the uterus. Round, uterosacral, and partly broad ligaments hold the uterus from excess upward displacement. The tense round ligaments of the parturient can be palpated through the abdominal wall. The counteraction of the ligaments adds to the expulsive force of the uterus.

The uterine retraction distends the cervix and the lower segment of the uterus. The latter consists of the isthmus and the lower portion of the uterus, has comparatively thin walls and contains smaller number of muscular elements than the upper portion of the uterus. The lower segment begins distending during pregnancy and completes its distension during labour due to retraction of the muscles of the upper uterine segment.

When the uterine contractions become very intense, a contracted area, known as the *constriction (contraction or Bandl's) ring*, is formed between the contracting upper segment and the distending lower segment of the uterus.

The constriction ring is usually formed after the rupture of the foetal membranes and the discharge of the fluids. The ring has the shape of a transverse band palpable through the abdominal wall.

Effacement and dilation of the cervix in a primipara are different from those in a multipara.

The internal os is first opened in the primipara, followed by gradual dilation of the endocervical canal which is thus transformed into a funnel narrowing downward (Figs. 93 and 94). As the endocervical canal dilates it shortens and is finally completely levelled (effaced). The margins of the external os are then thinned and dilated: the external os begins opening (Figs. 95 and 96).

In a multipara, the external os would normally slightly open at the end of pregnancy (Fig. 97) and pass a finger tip. During the dilation stage, the external os opens almost simultaneously with the internal os and with the effacement of the uterine cervix (Figs. 98 and 99).

The os opens gradually. First it passes a finger tip, then the tips of two fingers (3-4 cm), and so on. As the os continues opening its edges become thinner and by the end of the dilation

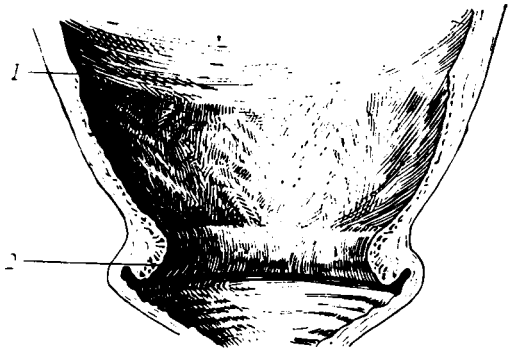

Fig. 99. The uterus of a multipara. The cervix is effaced, the external os completely dilated. The margin of the os forms a narrow ridge-like structure:
1 — former internal os, *2* — external os

period they show only as a narrow and thin ridge (see Figs. 96 and 99). The dilation period is considered to be complete when the os opens about 10-12 cm and can pass the head and the body of a mature foetus.

Each contraction of the uterus presses on the amniotic fluid to cause it move toward the lower pole of the conceptus and enter the endocervical canal. When the contraction is suspended, the fluid partly moves upwards to release the tension of the membranes. These free movements of the amniotic fluid toward the cervix and back continue till the foetus head floats above the pelvic inlet level. As soon as the head is engaged, it presses the uterine walls against the bones of the pelvic inlet by the entire perimeter to divide the fluids into two portions (Fig. 100). The main bulk of the amniotic fluid remains in the upper portion of the uterus above the line of engagement.

Fig. 100. The external os is completely open. The head is engaged:
1 — engagement line, *2* — forewaters, *3* — remaining fluid

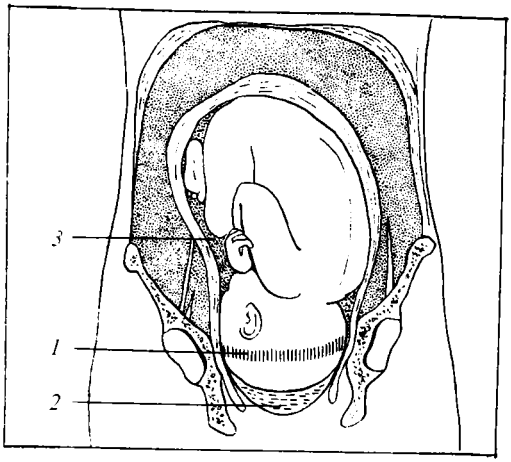

As the contractions of the uterus become more intense, the amount of forewaters increases and by the end of the first stage of labour the pressure inside the foetal membranes does not lessen between contractions; the foetal membranes are ready to rupture.

Normally the foetal membranes rupture with complete or almost complete opening of the cervix during a new contraction of the uterus (timely loss of fluid). Forewaters appear first, while the remaining fluids escape the uterus after delivery. Less frequently the membranes rupture when the cervix has not been opened completely, or even before the onset of labour.

If the membranes rupture before the cervical os has opened completely, the loss of fluid is *early*. Escape of the fluid before the onset of labour is called *premature*. Early or premature loss of the fluid adds to the risk of foetal distress.

If the membranes are very strong, they rupture after the cervical os has opened completely (delayed rupture). Sometimes, the foetal membranes do not rupture till the expulsive stage of labour and become protruded from

the pudendal cleft to precede the presenting part.

The Expulsive Stage

After complete dilation of the cervical os, the expulsive stage begins. With the loss of fluid, the contractions of the uterus become less intense; in 15-20 minutes the muscles of the uterus become adapted to the smaller volume and the contractions resume. The walls of the uterus become even thicker and their contractions stronger. The descending head presses on the nerve plexus stronger than the membranes and the length and force of the expulsive contractions therefore increase along with their increasing frequency. The uterus is strained during its contractions and becomes firm; the abdominal wall becomes protruded.

The expulsive contractions of the uterus are aided by the reflex contractions of the abdominal muscles. The parturient holds her breath and bears down to intensify voluntarily the contractions of the abdominal muscles.

The expulsive stage requires high effort on the part of the woman. It intensifies her cardiovascular function and the metabolism.

During contractions of the abdominal muscles, the face of the parturient becomes red or even bluish, the skin is covered with perspiration, the veins of the neck become tense and convulsions in the lower extremities may develop. At the intervals between contractions the parturient has a rest till the onset of next contractions.

The expulsive efforts of the uterus and the contractions of the abdominal muscles move the foetus so that its head engages with the small pelvis, passes it, and appears at the pelvic outlet. As soon as the head reaches the pelvic floor and its thrust on the floor increases, the contractions of the abdominal muscles become uncontrollable and their frequency and force increase (the intervals being as short as 2-3 min).

When the head nears the pelvic outlet, the perineum begins protruding, first only during contractions, but later it remains so in the pauses between contractions. The protrusion of the perineum is accompanied by the dilation and opening of the anus. If a cleansing enema was not administered to the parturient, involuntary defaecation occurs during labour.

As the foetal head progresses further through the birth canal, the pudendal cleft begins separating. During a contraction, a small portion of the presenting vertex shows through the opening pudendal cleft. The movement of the head discontinues with the cessation of the contraction, the head disappears and the pudendal cleft closes. During the next contraction the vertex protrusion becomes more significant and a greater portion of the head appears from the cleft. The head is said to '*crown*' (Fig. 101, *a*). As the parturient progresses with her labour, the crowning head protrudes to a greater extent and no longer moves back between contractions, while the pudendal cleft remains wide open. This stage is known as *disengagement of the head* (Fig. 101, *b*).

First the occiput is delivered, then appear the parietal tubers. The tension of the perineum is maximum at this moment. As soon as the occiput and the vertex have been delivered, the sinciput and the face of the foetus are extruded from the birth canal by strong contractions.

When the entire head is born, the contractions are suspended for a short time.

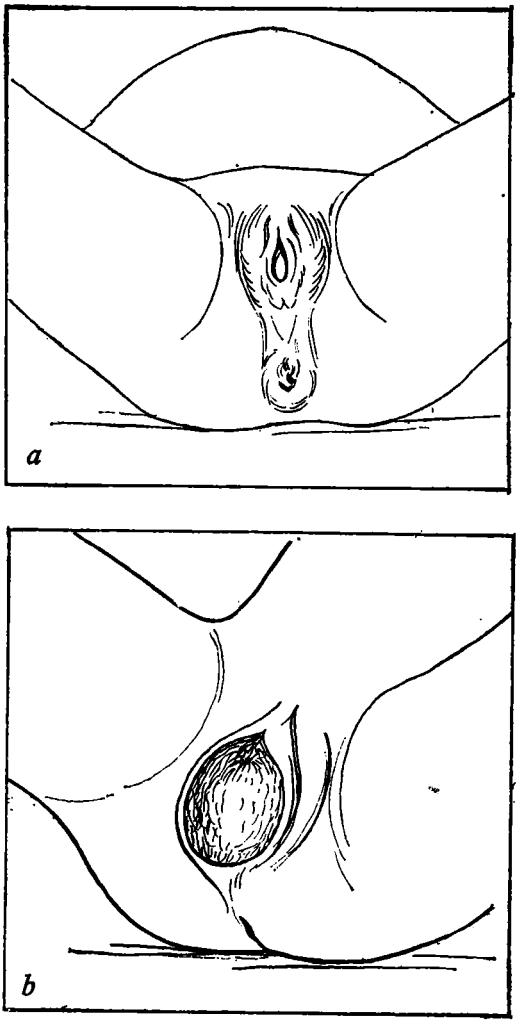

Fig. 101. Crowning and disengagement of the vertex:
a — crowning, *b* — disengagement

The delivered head normally faces posteriorly (Fig. 102, *a*); the face turns bluish and the nose and mouth liberate mucus. As the contractions are resumed, the foetal body undergoes internal rotation and its one shoulder is now directed toward the symphysis pubis and the other toward the sacrum.

The delivered head rotates together with the body and the foetus now faces the thigh of the mother (Fig. 102, *b*). It faces the right thigh in the left presentation and the left thigh, in the right presentation.

The shoulders are delivered as follows: the anterior shoulder is retained beneath the symphysis (Fig. 103, *a*) and the posterior shoulder is delivered over the perineum (Fig. 103, *b*). The entire shoulder girdle is then delivered. The rest of the body and the legs are extruded without difficulties. The delivery of the infant is followed by the escape of the remaining turbid fluids containing particles of the cheesy varnish. The fluids can sometimes contain traces of blood due to bleading from small lacerations of soft tissues in the birth canal.

The delivered baby takes its first breath, cries loudly, makes active movements with its legs, and its skin turns pink. The mother feels very tired and now has her rest. Her pulse returns to normal. Some women, after giving birth to a child, develop slight shivering due to the loss of large amounts of heat during labour.

The *mechanism of labour*. During the expulsive stage of labour, the foetus moves through the soft portions of the birth canal and the small pelvis.

The foetus passes along the pelvic axis, i.e. along a curved line connecting the centres of all anteroposterior diameters of the pelvis. The axis follows the curvature of the sacrum, and curves anteriorly towards the symphysis at the pelvic outlet (Fig. 104).

The walls of the pelvis are unequal in their length: the symphysis is much shorter than the sacrum. The shape of the small pelvis is different in its

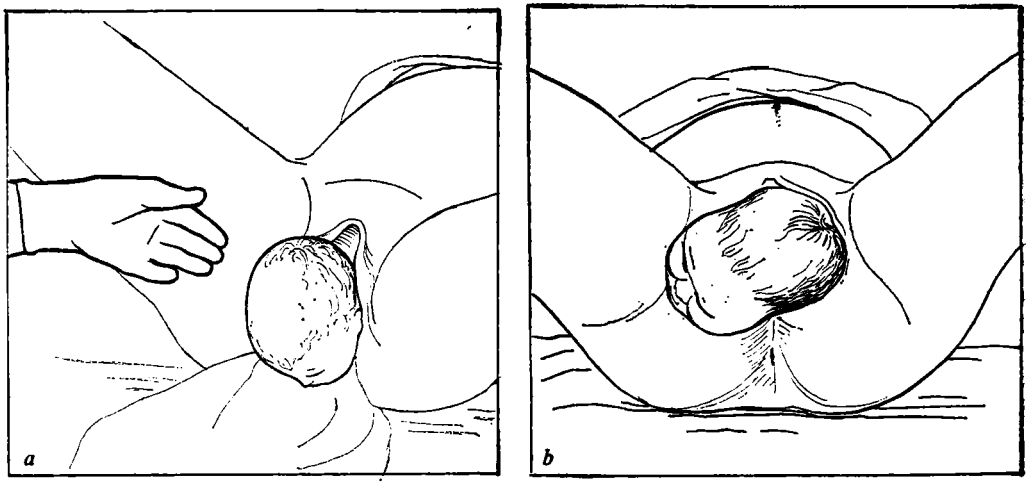

Fig. 102. Delivery of the head:
a — delivered head faces posteriorly, *b* — external restitution of the vertex

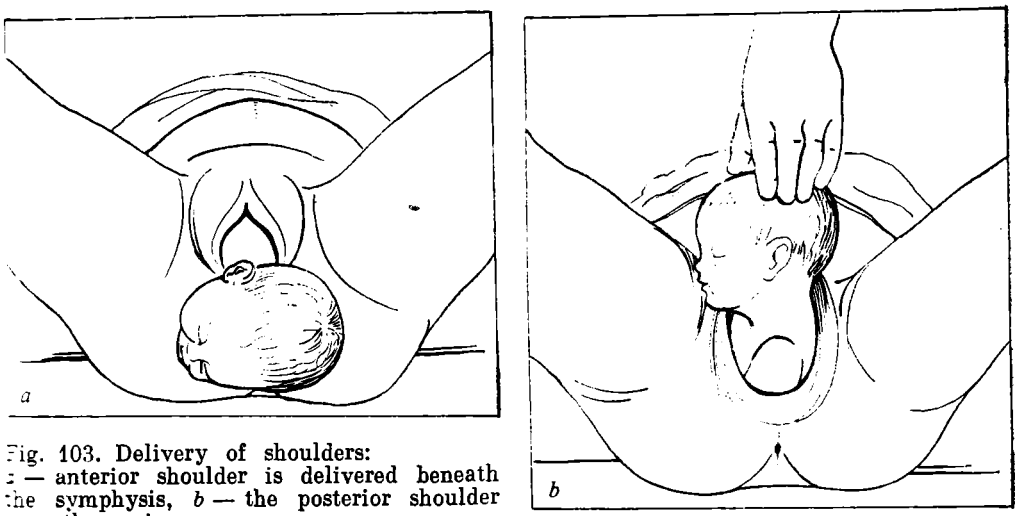

Fig. 103. Delivery of shoulders:
a — anterior shoulder is delivered beneath the symphysis, *b* — the posterior shoulder over the perineum

various planes: the shape of the pelvic inlet plane is elongated in the transverse direction, the midpelvic plane is rounded, while the plane of the pelvic outlet is elongated anteroposteriorly. The planes of the foetal head are also different, and for this reason the head cannot traverse the birth canal without rotating. As the foetus progresses along the birth canal its body, and especially the head, make certain rotations. The head rotates about its longitudinal and transverse axes as well (it is said to flex and deflex).

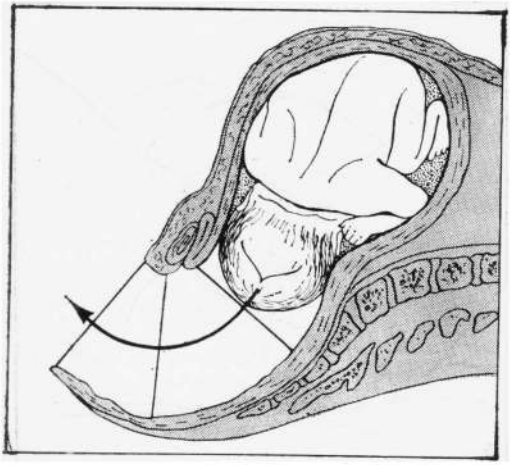

Fig. 104. Schematic diagram showing the birth canal during the expulsive stage

The *combination of movements performed by the foetus as it passes the small pelvis and the soft portions of the birth canal is called the mechanism of labour.*

The mechanism of labour is different with various types of cephalic and breech presentations. The most typical and normal is the mechanism of labour with the occiput anterior presentation which makes 95 per cent of all cases.

Mechanism of Labour in Occiput Anterior Presentation

The following major movements of the foetus during labour are distinguished:

The *first movement* is the flexion of the vertex; the head is rotated about its transverse axis.

During the dilation stage of labour, the head is engaged in the pelvic inlet, its sagittal suture being aligned with the transverse or slightly oblique diameter of the pelvis.

During the expulsive stage the downward thrust of the uterus and the prelum on the foetal spinal column is transmitted onto the foetal head. The vertebral column is joined with the cranium in the region nearer the occiput (not in the centre) and the flexion of the vertex is therefore described as a lever-like action, the long arm of the lever being represented by the sinciput and the short arm by the occiput. The intrauterine and intraabdominal pressure is transmitted through the spinal column mainly on the occiput (the shorter arm of the lever) to force it downward. The occiput descends, the chin is brought in approximation of the chest, and the posterior fontanelle is positioned below the anterior fontanelle (Fig. 105).

The posterior fontanelle is further moved along the pelvic axis and is the first to show through the open pudendal cleft. The posterior fontanelle is thus the *leading point* in the occiput anterior presentation of the foetus.

The leading point is that portion of the presenting part which is the *first to descend the pelvic inlet; it leads the way during the internal rotation and is the first to show through the pudendal cleft.*

As a result of flexion, the head engages the pelvis with its smaller diameter, i.e. suboccipitobregmatic diameter (9.5 cm) instead of the occipitofrontal diameter (12 cm) in the former position. The head leads the way through the pelvic planes and the pudendal cleft with its smallest diameter.

The *second movement* is the internal rotation of the vertex. The head further advances (descends) into the birth canal and rotates simultaneously about its longitudinal axis so that the occiput (and the posterior fontanelle) turn

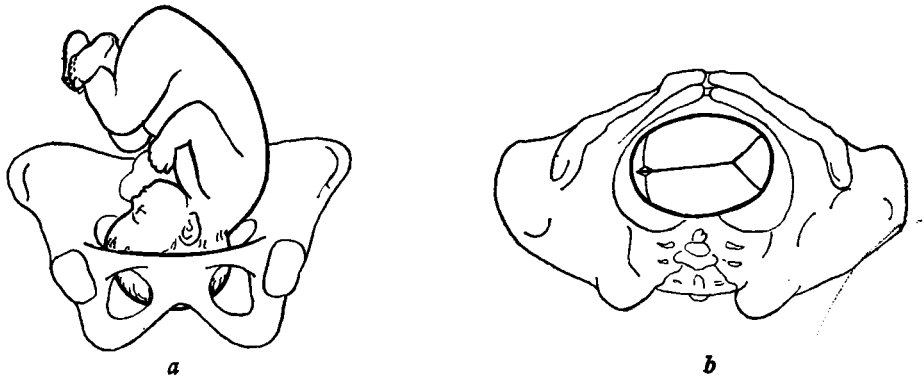

Fig. 105. *a* — the first movement of labour — flexion of the vertex, *b* — alignment of the sagittal suture with the transverse pelvic diameter

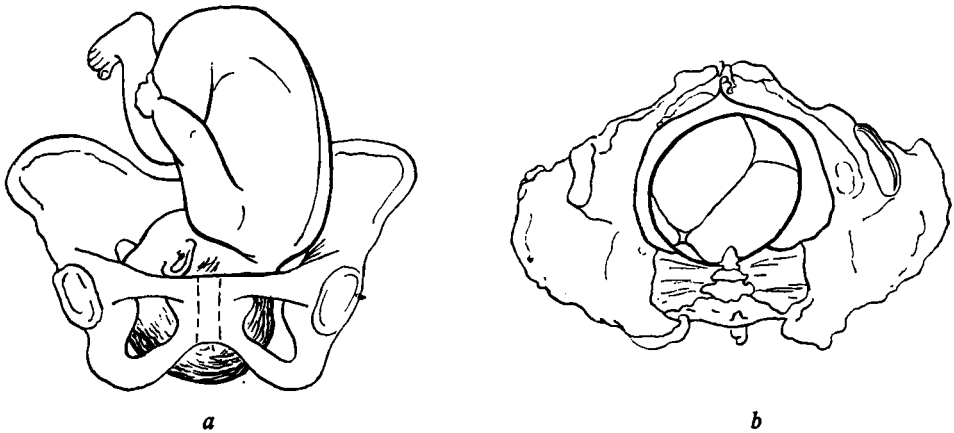

Fig. 106. *a* — the second movement of labour — internal rotation, *b* — alignment of the sagittal suture with the right oblique pelvic diameter

anteriorly, while the sinciput (and the anterior fontanelle) rotate posteriorly (Fig. 106, *a*). The sagittal suture is now in alignment with the transverse or slightly oblique diameter of the pelvis and changes its orientation gradually. As the head descends into the pelvic cavity, the sagittal suture is aligned with the oblique diameter (Fig. 106, *b*), namely the right oblique diameter in the left position and with the left oblique diameter in the right position of the foetus. At the outlet from the pelvis, the sagittal suture of the head is parallel to the anteroposterior diameter of the pelvis, the internal rotation of the head being thus completed. The posterior fontanelle now faces the symphysis (Fig. 107, *a*, *b*). As a rule, the head rotates through 90 degrees as it passes the pelvic cavity (from the inlet to the outlet). If the occiput of the foetal head was slightly turned anteriorly before the internal rotation,

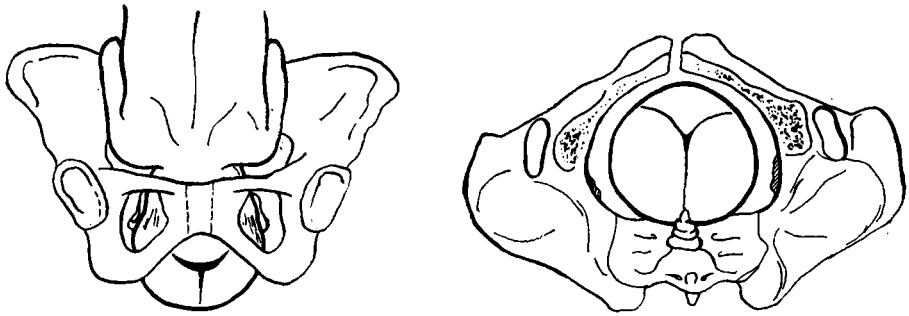

a *b*

Fig. 107. *a* — complete internal rotation, *b* — the sagittal suture is aligned with the anteroposterior pelvic diameter

the head turns through 45 degrees, and if the occiput was turned slightly posteriorly, the head rotates through 135 degrees. Thus, the sagittal suture is first aligned with the transverse diameter of the pelvic inlet plane and then changes to alignment with the oblique diameter of the midpelvic plane, and further with the anteroposterior diameter of the pelvic outlet plane.

The cause of the internal rotation has been the subject of much discussion and a number of theories have been advanced to explain it. The most probable is the theory which explains the internal rotation of the head by its accommodation to the pelvic diameters: the head passes the largest diameters of the pelvis with its suboccipitobregmatic diameter (the least diameter). The transverse diameter is the largest in the pelvic inlet plane, the oblique diameter is the largest in the midpelvic plane, and the anteroposterior diameter is the largest in the pelvic outlet plane. The head rotates accordingly from the transverse diameter to the oblique and finally to the anteroposterior diameter. V. V. Sutugin maintained that the foetal head rotates with rotation of the shoulder girdle, while P. A. Beloshapko and I. I. Yakovlev explain the rotation of the head by contractions of the pelvic floor muscles.

The *third movement* is the extension of the vertex. When a strongly flexed head reaches the pelvic outlet, it meets the resistance of the pelvic floor muscles. Contractions of the uterine and prelum muscles push the foetus in the direction of the sacral tip and the coccyx. The muscles of the pelvic floor oppose that thrust of the foetal head in this direction and thus deflect its movement anteriorly toward the pudendal cleft. The resultant force causes the head to deflex when the posterior cranial fossa passes beyond the inferior margin of the symphysis (Fig. 108, *a*) which acts as a fulcrum. As the head deflexes (Fig. 108, *b*), the sinciput, the face and chin emerge, that is the head is delivered. In the occiput anterior presentation, the head emerges through the vulva by its smallest plane which passes over the subocci-

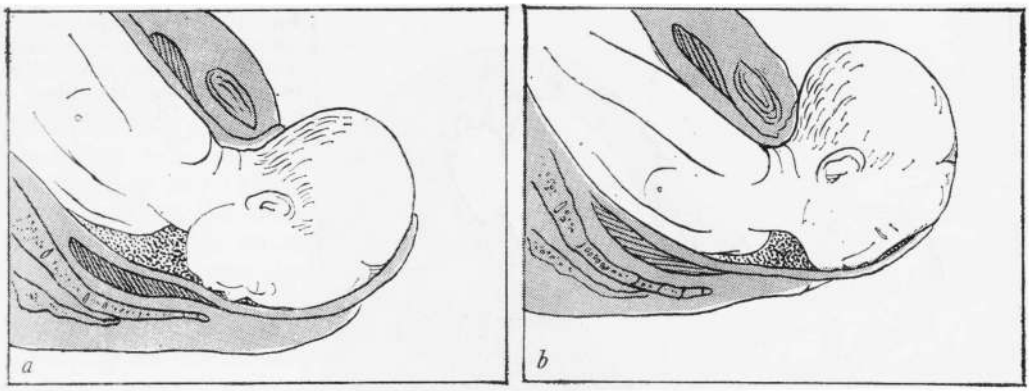

Fig. 108. The third movement of labour:
a — beginning extension (coincident with crowning), *b* — complete extension (disengagement)

pitobregmatic diameter (the girth, 32 cm).

The *fourth movement* is the external restitution of the vertex.

As soon as the head has been born, the face of the foetus turns toward the left or right thigh of the mother (depending on the position of the foetus): in the left occiput presentation the foetus faces the right thigh and in the right presentation, the left thigh of the mother. The external restitution of the head depends on the position of the shoulders. The shoulders begin their descent into the pelvis in alignment with the transverse (or slightly oblique) diameter of the pelvic inlet.

The shoulders begin rotating in the midpelvic plane to align with the oblique diameter. The internal rotation of the shoulders is completed at the pelvic bottom and they pass the pelvic outlet in alignment with its anteroposterior diameter, one shoulder being directed toward the symphysis and the other toward the sacrum (Fig. 109). The rotation of the shoulders is transmitted to the head and as the shoulders pass the anteroposterior diameter of the pelvic outlet plane the face of the foetus turns toward the thigh of the mother.*

Mechanism of Labour in Persistent Occiput Posterior Presentation

In the occiput anterior position of the foetus, the internal rotation of its vertex occurs so that the occiput turns anteriorly (toward the symphysis) while the face posteriorly (toward the sacrum). The occiput turns anteriorly also in all posterior presentations, i.e. in all cases where the back and the occiput of the foetus were directed posteriorly before the expulsive stage of labour. As labour progresses,

* A. Ya. Krassovsky differentiated five movements in the mechanism of labour. In the occiput anterior presentation these movements are as follows: (1) flexion of the head, i.e. shortening of the diameter of the presenting part; (2) descent of the head; (3) internal rotation of the vertex; (4) extension of the vertex with birth; (5) internal rotation of the shoulders and external restitution of the vertex.

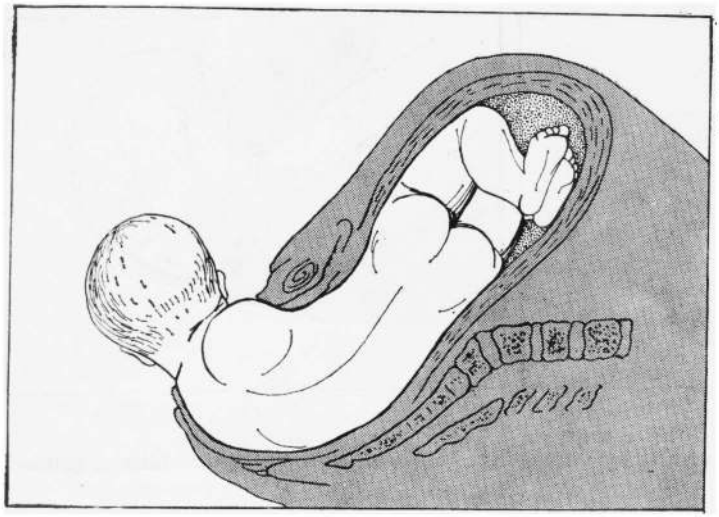

Fig. 109. The fourth movement of labour — external restitution. The internal rotation of the shoulders is completed. Disengagement of the shoulders

the posterior position of the foetus normally changes to the anterior one and it is only in rare cases (1 per cent of all occiput presentations) that during the internal rotation the vertex turns with its occiput toward the sacrum and labour continues with the posterior position of the foetus. The mechanism of labour in persistent occiput posterior presentation is as follows.

The *first movement*—flexion of the vertex. The posterior fontanelle is the leading point of the head.*

The *second movement*—internal rotation of the vertex. The flexed head descends into the pelvis and rotates posteriorly with its occiput (Fig. 110, *a*) so that the sagittal suture aligns with the oblique diameter of the pelvic inlet plane and then with the anteroposterior diameter of the pelvic outlet plane. When the rotation has been completed, the posterior fontanelle (occiput) faces the sacrum while the anterior fontanelle, the symphysis.

The *third movement*. During extension (a) the head is first flexed to a greater degree and then (b) deflexed. The border of the haired sinciput impinges the symphysis and the head is strongly flexed against this fulcrum (Fig. 110, *b*). As the head undergoes this additional flexion the parietal and the occipital tubers show outside. The head then rests by its posterior cranial fossa against the sacrococcygeal joint and deflexes. The sinciput, the face and the chin are now disengaged from the pubic arch and the head is delivered by its suboccipitofrontal diameter (girth, 33 cm).

The *fourth movement*—external restitution of the vertex and the internal rotation of the shoulders. The movement occurs in the same way as in the occiput anterior position.

In persistent occiput posterior presentation, the head meets considerable resistance as it traverses the birth ca-

* First the posterior fontanelle is the leading point in the occiput posterior presentation, but by the end of the internal rotation, the area found midway between the anterior and posterior fontanelles becomes the leadign point.

nal and the expulsive stage of labour usually lasts longer than in the occiput anterior presentation.

Effect of the Mechanism of Labour on the Shape of Foetal Head. The head of the foetus can change its shape to adjust itself to the shape and size of the birth canal in the course of labour. This ability depends on the degree to which the bones of the skull can overlap each other in the region of the fontanelles and sutures and change their shapes as the vertex traverses the small pelvis.

When the walls of the birth canal press the skull of the foetus, its bones overlap each other in the region of the sutures and the fontanelles. One parietal bone overlaps the other, and the occipital and frontal bones can slide beneath the parietal bones. The skull bones flatten or, on the contrary, become more convex. As a result, the head of the foetus changes its shape and becomes adapted to the shape and size of the birth canal. This adjustment of the foetal head during its passage through the birth canal is called moulding. The degree of moulding depends on the skull architecture and the features of the birth canal. The wider the sutures and the softer the bones of the foetal head, the greater the degree of moulding. Moulding can be especially significant when the head meets high resistance to its progress through the birth canal (contracted pelvis). The degree of moulding also depends on the mechanism of labour. In an occiput (especially posterior) presentation, the head is elongated in the direction of the occiput to assume the shapes of a dolichocephalic head (Fig. 111). In the occiput anterior presentation the head is elongated in the direction of the vertex, and in the frontal presentation, in the direction of the sinciput, etc. If labour is normal, the moulding is not marked and has no effect on the development of the infant. The normal shape of the head is soon restored after birth.

a

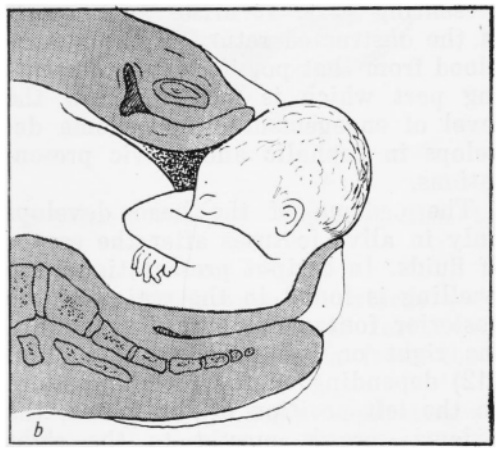

b

Fig. 110. Labour in persistent occiput posterior presentation: *a* — internal rotation of the vertex with the occiput pointed posteriorly (the second movement of labour), *b* — additional flexion of the vertex (the third movement of labour)

During the expulsive stage of labour,

Fig. 111. Moulding of foetal skull in occiput presentation

in addition to moulding, the head of the foetus can develop a *swelling* or *oedema* at the lowermost point of the presenting part. It arises as a result of the obstructed return of the venous blood from that portion of the presenting part which is located below the level of engagement. The oedema develops in cephalic and pelvic presentations.

The oedema of the head develops only in alive foetuses after the escape of fluids. In occiput presentations, the swelling is found in the region of the posterior fontanelle, spreading toward the right or left parietal bone (Fig. 112) depending on the foetal position. In the left position of the foetus, the oedema spreads mostly to the right and in the right position, to the left parietal bone. The swelling is formed on the face in face presentations and on the buttocks in breech presentations. Normally the swelling is not significant and disappears spontaneously in a few days after birth. If the expulsive stage is prolonged for example with contracted pelvis, the tumour on the head can be large; the skin of the tumour becomes dark red. On the contrary, if the labour is very fast and the head of the foetus is small, the tumour is insignificant or absent altogether.

If the passage through the birth canal is difficult, or in surgical delivery, a cephalhaematoma may develop on the head due to haemorrhage beneath the pericranium of either (in rare cases of both) parietal bone. Cephalhaematoma is a soft swelling of irregular shape found within the confines of one bone only. In contrast to the oedema of the head, which has no distinct boundaries, the cephalhaematoma never extends beyond the sutures or the fontanelles.

The Placental Stage

After the foetus has been delivered, the third stage of labour, viz., the placental stage begins, which is characterised by the following: (1) the placenta and the membranes are separated from the uterine walls, (2) the separated placenta and the membranes are expelled from the uterus.

The main force responsible for the expulsion of the placenta is the contraction of the uterus; the prelum is also involved in this process.

After the child is born the uterus contracts and changes to a globular shape;

Fig. 112. Parietal swelling of the foetal head

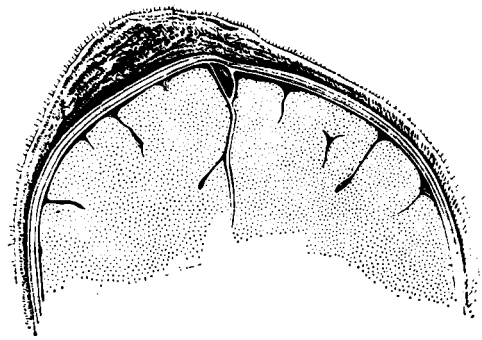

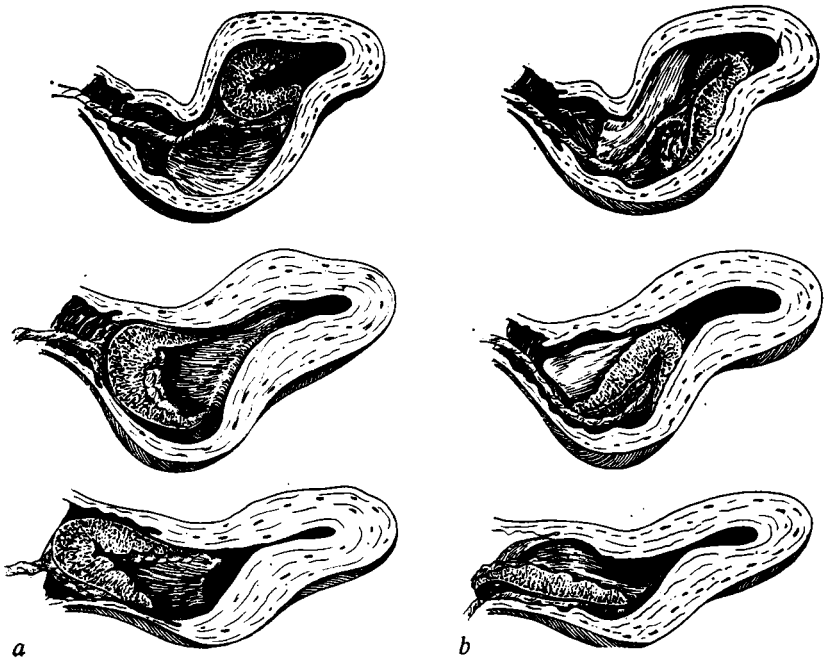

Fig. 113. Mechanism of placental separation:
a — the separation begins from the centre (Schultze method), *b* — the separation begins from the margin (Duncan method)

its fundus is now at the level of the navel. The contractions of the uterus are resumed in a few minutes following the delivery.

All muscles of the uterus are involved in the expulsion of the placenta, the muscles of the placental site included. The placenta cannot contract and the site of its attachment therefore decreases with each contraction of the uterus. The placenta folds, sags into the uterine cavity, and is finally separated from the uterine walls.

The breakdown of connections between the placenta and the uterine walls is associated with the rupture of the uteroplacental vessels in the region of the separated placenta. The blood of the ruptured vessels is accumulated in the space between the uterus and the placenta and promotes further separation of the placenta from the site of its attachment.

The placenta begins separating either from the centre or the margins.

By the first mechanism (Schultze method, Fig. 113, *a*), the central part of the placenta is separated first. An accumulation of blood, or retroplacental haematoma, is formed between the separated portion of the placenta and the uterine wall. This promotes further separation of the placenta. When the placenta is completely separated, it is expelled from the uterus together with the foetal membranes. The placenta appears from the uterus with its foetal surface outside; the

membranes are also delivered with their inner surfaces turned outside (with the amnion overlying the decidual membrane). The inverted membranes are found on the maternal surface of placenta.

According to the other method (Duncan, Fig. 113, *b*) the placental separation begins from its margins, normally from its lower margin. The blood released from the disintegrated vessels does not form retroplacental haematoma but flows down between the uterine wall and the membranes. Each new contraction of the uterus causes further separation of the overlying portions of the placenta. After complete separation, the placenta slides away from the uterus and pulls the membranes which are also separated from the uterus. The placenta appears with its inferior margin forward. The delivered membranes preserve their intrauterine arrangement (the amnion is inside the decidual membrane).

The second mechanism occurs less frequently.

The placental stage of labour is marked by bleeding from the placental vessels that are ruptured during separation of the placenta. Normally about 250 ml (from 150 to 300 ml) of blood are shed. This is a physiological loss of blood and it has no adverse effect on the puerperal woman.

After the placenta has been expelled, the uterus undergoes a period of long contraction. The contracted muscle fibres and bundles narrow the lumen of the myometrial blood vessels to establish haemostasis.

With the completion of labour, the woman is called a *puerpera*.

Duration of Labour

The duration of labour depends mainly on the character of labour forces, and also on some other factors. The more intense the uterine and abdominal contractions, the shorter the labour. Various factors, such as the size of the foetus, type of presentation, pelvic diameters, the time of escape of the amniotic fluid, etc., affect the duration of labour.

Labour in the primipara is usually longer than in the multipara. Elderly primiparas (over 30) and aged primiparas often have prolonged labour. Labour is also prolonged in underdeveloped women (infantilism), in obese or asthenic patients.

Normally labour continues for 15-24 hours in the primipara, and 10-12 hours in the multipara. The longest is the first stage of labour: in primiparous women it continues for 13-18 hours, and in multiparous for 6-9 hours.

The expulsive stage continues for 2-3 hours in primiparas, and 30-60 min in multiparas. The placental stage averages 30 (from 15 to 60) min in both primi- and multiparas.

At the present time labour of shorter duration is observed not infrequently with healthy young (20-25 years of age) women, which can be explained by the general improvement of welfare, skilled medical aid, and other factors favourably influencing the health of women.

Chapter Nine

CONDUCT OF LABOUR

Admission of the Patient

The maternity patient delivered to the lying-in hospital should take off her street clothes and be examined for the absence of infectious diseases. All women suspicious in this respect should be separated from healthy parturients.

The nurse examines the patient, reveals her possible contacts with infectious patients prior to admission, and gives the woman an external examination paying special attention to the status of the skin (pyodermitis, furunculosis, etc.), the nasopharynx (redness, patches), and the genitalia (purulent discharge, condylomas, etc.). The temperature and pulse of the parturient are taken.

After the preliminary examination, healthy parturients are admitted to another examination room of the first obstetrical department (for healthy women).

Patients with fever, purulent diseases of the skin, influenza, tonsillitis or other infectious diseases should be admitted to a special (second) department.

Should the hospital be small and have no special department, the patients with signs of infectious diseases or elevated temperature should be sent to another hospital provided with the facilities to accommodate infectious parturients.

The parturient should undergo special treatment on admission. The examination room intended for the purpose should be equipped with the following:

(1) inspection table (couch), (2) table, (3) stand for an Esmarch's irrigator, (4) balance, (5) height meter, (6) thermometers, (7) stethoscope, obstetrical or normal, (8) pelvimeter, (9) measuring tape, (10) Esmarch's irrigator for enema with a set of endpieces, (11) an Esmarch's irrigator for washing genitalia, with a set of endpieces, (12) a razor, (13) sterile brushes for hand washing, (14) sterile sponges for washing of the parturients, (15) sterile forceps for dressing materials; (16) a spatula, (17) a sphygmomanometer, (18) a sterile syringe and a set of needles for subcutaneous injections, (19) scissors, (20) standard sera and other materials necessary for determining the blood group, (21) sterile materials, such as cotton wool, balls, napkins, (22) soap, (23) alcohol, iodine tincture, disinfectants (lysoform, chloramine), (24) oil-cloths, linen, towels, (25) a bedpan.

The examination and treatment of the parturient consists in the following:

1. History taking. The patient is identified and her anamnestic data are entered into the admission record.

2. The woman is given a thorough examination: her visible mucosa, the

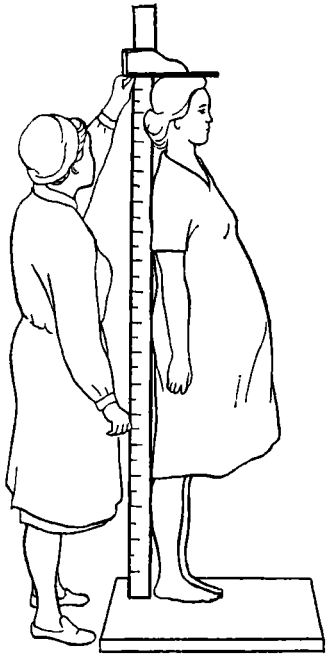

a

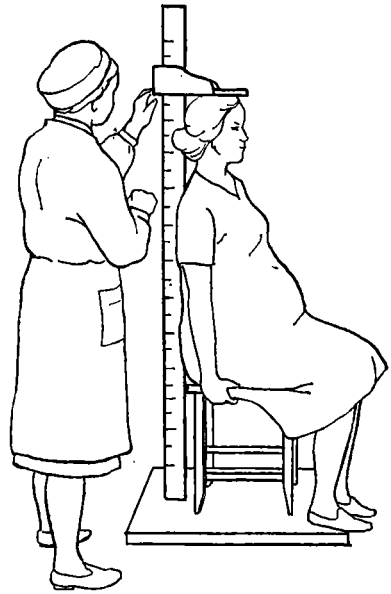

b

Fig. 114. Measuring height of the parturient:
a — standing; *b* — sitting

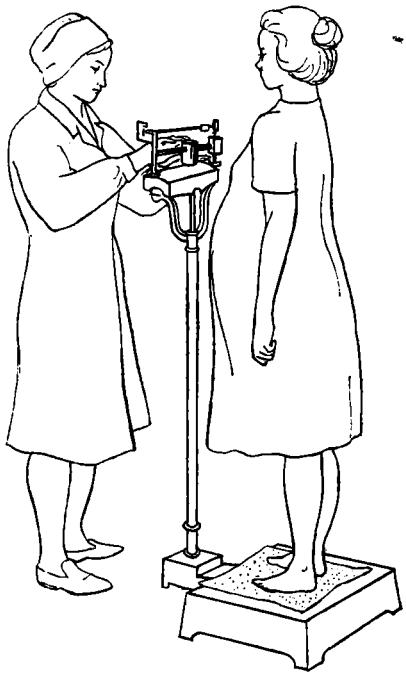

Fig. 115. Weighing the pregnant

abdomen and the pelvic region are inspected, the lungs, the heart and other organs are examined by percussion and auscultation. The height of the woman is measured (Fig. 114) and the weight determined (Fig. 115). The arterial pressure of each parturient should obligatory be measured.

3. The patient is placed on the inspection table (couch) over a clean linen and given an external obstetrical examination (palpation, auscultation, measuring the abdomen, determining the uterine level, measuring the pelvic diameters) and examination of the external genitalia. The vaginal examination should be given to the parturient in the labour room.

All data of the objective examination

of the parturient should be put into her case record.

4. The hair is removed from the perigenital area by a razor. All razors should always be kept in alcohol. Before shaving the parturient, the nurse washes her hands and wipes with alcohol. Using a piece of sterile cotton wool or a brush, the hair on the external genitalia is covered with soap foam and then shaved. All hair should be removed from the mons pubis, the labia majora and the perineum.

5. After shaving, the external genitalia should be washed with a weak disinfectant solution (1 per cent lysoform, 0.5 per cent chloramine, or 1:6000 solution of potassium permanganate). The genitalia are then dried up with sterile gauze held in forceps. Syringing is only done for special indications.

If there is no pathological discharge from the vagina, the parturient is offered to urinate into a clean dry bedpan. An 8-10 ml portion of the urine is taken for examination.

If pus or sanies is discharged from the vagina, the urine sample is taken by a sterile catheter. Before catheterization, the nurse should wash her hands and wipe them with alcohol. The vulva should be treated with a disinfectant solution.

The *urine of the parturient should obligatory be tested* for protein by boiling with acetic acid (or the Exton test).

The further examination of the urine should be done at the laboratory.

Acetic acid test. Take an 8-10 ml sample of the urine, place it in a test tube and boil over an alcohol burner. The urine containing protein or large amount of salts becomes cloudy on boiling. Add a few drops of a weak (3-5 per cent) acetic acid solution and boil again. If cloudiness does not disappear, the urine contains protein. If the urine becomes clear it indicates that the turbidity depended on the presence of salts that dissolved on the addition of the acid.

Exton's test. Place 4-5 ml of filtered urine into a test tube and add 8-10 drops of a 20 per cent solution of sulphosalicylic acid. The presence of albumin is manifested by turbidity or precipitation of flakes.

6. A cleansing enema should be administered to the parturient except in cases where the woman has been admitted to the hospital in the second stage of labour.

The enema should be made with 3-4 glasses of boiled water at room temperature with the patient lying on her left side. The end-piece should be sterile. Used end-pieces should be washed, boiled, and kept before use in a lysoform solution.

The parturient should not be left alone in the lavatory because the contractions of the abdominal muscles may evoke the expulsive labour forces.

7. After the administration of the cleansing enema, the patient should have her nails on the fingers and toes cut, and her hair on the head inspected and washed with soap.

8. The parturient takes a shower. Baths are prohibited to prevent the entrance of pathological microbes into the vagina from water. If shower is not available a nurse may pour water over the woman from a suitable vessel. After taking shower, the parturient is wiped dry with a towel, and dressed in clean underwear and a gown. The hair is covered with a kerchief. If the abdominal muscles contract, the parturient is brought straight to the delivery room.

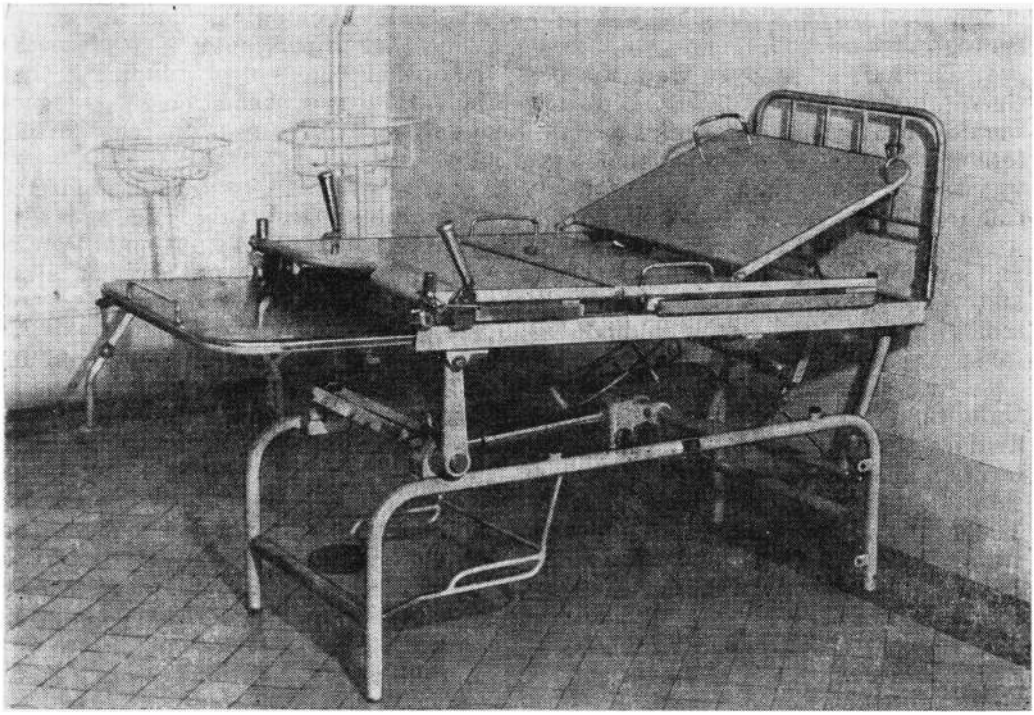

Fig. 116. Rakhmanov's collapsible bed

Labour and Delivery Rooms

The parturient is kept in the labour room during the first stage of labour. As the second (expulsive) stage begins, the parturient is moved to the delivery room. If the hospital is very small it may have no labour room, and the parturient is placed in the delivery room directly on admission.

The labour and delivery rooms should be kept absolutely clean. Only tools and equipment that are necessary to conduct labour are allowed to be present in these rooms to minimize the danger of contamination.

The labour room should be equipped with beds, cabinets for medicines (anaesthetics, cardiac, haemostatic, disinfectants, etc.), and tools, little bedside cabinets, a table for writing the admission and labour record, a table for sterile materials, and a wash stand (with water, soap, brushes, etc.).

The delivery room should be equipped with beds, wheeled tables for sterile materials and tools, a table for giving the first care to the neonate, a balance for weighing the neonate, a height meter, a table for writing the delivery record, supports for sterilizing boxes, and containers with disinfectant solutions. Should the hospital have no labour room, the delivery room will be equipped with cabinets for medicines and tools.

The set of medicines at the delivery room should always contain cardiac

Fig. 117. Rakhmanov's bed prepared for a parturient

drugs (caffeine, camphor, cardiazole, etc.), haemostatics (ergometrine, pituitrin, oxytocin, etc.), anaesthetics (should be kept in a special cabinet), a freshly prepared 2 per cent solution of silver nitrate for prophylaxis of ophthalmoblennorrhoea of neonates, alcohol, iodine tincture, and disinfectants. Sterile scissors for cutting off the umbilical cord, ligature for tying the umbilical stump, sterile materials, syringes, physiological saline solution, the Bobrov apparatus, resuscitation means to render the aid to a neonate born in asphyxia (basins, cold and hot water, a rubber syringe for aspiration of mucus from the upper airways, etc.) should always be at hand.

Many Soviet obstetrical establishments make use of a labour bed designed by A. N. Rakhmanov. It differs from an ordinary bed in that (1) it is higher (to facilitate obstetrical manipulations in the second and third stages of labour); (2) it consists of two collapsible parts (Figs. 116 and 117); the tail end of the bed can be moved beneath the main part of the bed so that the pelvis of the parturient be at the edge of the bed ('transverse' bed). Since the legs of the parturient are flexed, her genitalia are readily accessible for obstetric manipulations.

The head end is adjustable in height. The mattress consists of two parts, and one of them can be removed from

the tail end of the bed in normal labour or when it is necessary to make a 'transverse' bed.

Labour beds of improved design are now available.

The First Stage

When the parturient is placed in the labour room, the obstetrician takes her history and gives an additional external inspection (body-built, shape of the abdomen, Michaelis' rhomboid, etc.) and a detailed obstetrical examination. All findings are put into the labour record.

The parturient is now placed in bed from which she is allowed to get up only on condition that the membranes are intact, the contractions are not frequent or strong, and the foetus is in the vertex presentation. If these conditions are not fulfilled, the parturient should not leave her bed and should lie on her back, side, or in other position comfortable for her.

The obstetrician should take constant care of the parturient during the first stage of labour (fatigue, vertigo, headache, deranged vision, etc.); the progress of labour should be carefully followed and the foetal heart tone and the mother's pulse regularly checked. The pulse rate may slightly accelerate in normal labour but it remains full and rhythmic. The body temperature of the parturient should be taken two or three times a day.

The character of labour should be observed during the entire first stage. The obstetrician should assess the strength of contractions and their length and frequency. The number of contractions is recommended to be counted.

The parturient should be given *regular external examinations* during the dilation stage of labour. Special attention should be paid to the foetal presentation and its level above the pelvic inlet (floated, fixed against the pelvic inlet, engaged with the smaller segment), the consistency of the uterus during its contractions and in the pauses between them, the level of the uterine bottom, and the condition of the contraction ring. The strength and duration of contractions should be determined by hand positioned over the uterine bottom. The relaxation of the uterus is assessed by palpation. At large lying-in hospitals the uterine contractions are studied hysterographically. The uterus relaxes well after contractions in physiological labour. The contraction ring in normal labour is a transverse ridge-like structure. As the external os gradually opens, the ring moves upwards and by the end of the first stage of labour it is found a palm-breadth above the symphysis. The uterine level rises as well. At the onset of labour the uterine bottom would normally be found midway between the xiphoid and the navel, while by the end of the first stage it rises to the costal arch.

The *foetal heart tone should be listened to* at 15-20 minute intervals during the first stage of labour (with the intact membranes) and at 5-10 minute intervals after the escape of the amniotic fluid. The accelerated heart rate (to 160 and over) and also deceleration to 110 and below are the signs of threatening asphyxia.

The *rupture of the membranes and the loss of the fluid* are important events in labour and require special attention on the part of the obstetrician. Normally the amniotic fluid escapes when the cervix is completely, or almost completely, open; the fluid is clear. The presence of meconium would usually in-

dicate the beginning asphyxia. If blood is present, it may indicate laceration of the cervical os margins, placental separation or other pathological processes. If the head is not engaged by the moment of fluid loss the umbilical cord or the arm of the foetus can be delivered together with the gush of fluids. The delivery of the umbilical cord will cause asphyxia, while the delivered arm will interfere with normal expulsion of the entire foetus.

The *vaginal examination* is given to the parturient on her admission and after the loss of the amniotic fluid. Later vaginal examinations should only be done for special indications: prolonged expulsive stage, unknown presentation of the foetus, bleeding from the birth canal, asphyxia of the foetus, etc.

The vaginal examination should reveal the state of the vagina (its lumen, possible stenosis, partitions), the cervix (short, effaced), the degree of dilation and the state of the cervical os (thin, thick, distended, rigid), the status of the membranes (ruptured, intact, tense, flaccid), the presenting part and its orientation toward the pelvic planes (floated, engaged with the smaller or larger segment, inside the pelvic cavity, at the pelvic outlet); the landmarks of the presenting part are palpated; if possible, the internal surfaces of the pelvic bones are palpated and the diagonal conjugate measured, provided the promontorium is palpable.

The discharge from the birth canal is carefully studied during the entire labour. Before the amniotic fluid escapes the uterus, a clear viscous mucus is discharged from the cervical canal.

The function of the *bladder and the intestine* should be inspected. Full bladder or rectum interferes with normal



Fig. 118. A female catheter

course of labour (dilation of the cervix and expulsion of the foetus and the placenta).

The bladder may be full because of its atony when the woman does not feel the urge to urinate. Another cause of full bladder can be the obstruction of the urethra when it is pressed by the foetal head against the symphysis. In order to preclude overfilling of the bladder the parturient should be offered to urinate at 2-3 hour intervals.

Fig. 119. Catheterization of the bladder

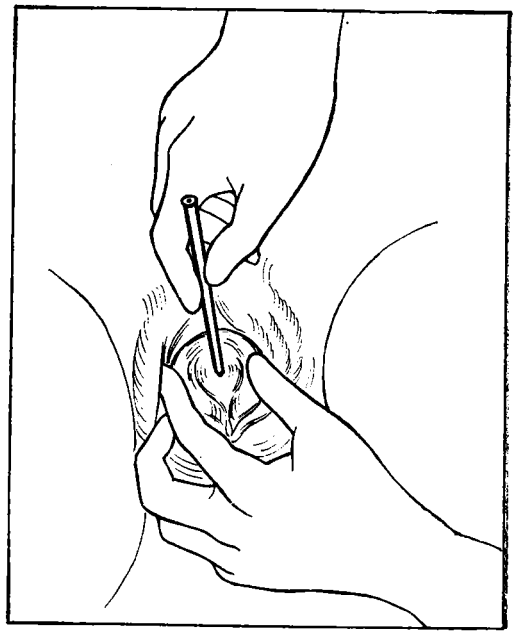

If she fails to urinate spontaneously, she should be catheterized.

Catheterization should be done as follows. The external genitalia should be washed with a weak disinfectant solution. The nurse should wash her hands with soap and water using a sterilized brush. The hands are then wiped with alcohol. The lips are separated by the forefinger and the thumb of a less adept hand to expose the meatus of the urethra. The meatus is washed with a weak disinfectant solution (lysoform, potassium permanganate) and a catheter (Fig. 118) carefully introduced into the bladder through the urethra (Fig. 119). The urine is inspected to see if it contains any traces of blood or turbidity. The urine is tested whenever necessary. The rectum should also be emptied in due time. If the first stage of labour continues over 12-15 hours a cleansing enema should be administered.

The external genitalia of the parturient should be washed at least at 5-6 hour intervals during the first stage, and also after each urination or defaecation.

Labour is associated with expenditure of much energy and the parturient should therefore take food. Readily assimilable food (such as broths, dairy products, sweet tea, etc.) should be given in small portions. Sometimes the parturient would not feel hunger and the nurse should offer food in due time bearing in mind the adverse effect of hunger on the parturient.

Measures to relieve pain are taken during the first stage of labour.

The expulsive stage begins after complete dilation of the cervical os. The membranes would normally rupture about this time (sometimes slightly before the complete dilation is attained). The rupture is manifested by the discharge of forewaters. If the foetal membranes remain intact and show from the pudendal cleft with the onset of abdominal contractions, they should be punctured by a finger or any surgical instrument.

The Second Stage of Labour

The parturient is strained considerably during the second (expulsive) stage of labour. Her cardiovascular and muscular systems, the respiratory and other organs function intensely, and patients with cardiovascular diseases, diseases of the lungs and other organs can therefore develop cardiac and metabolic disorders during the second stage of labour.

Prolonged expulsive period, strong and frequent uterine and abdominal contractions can interfere with normal uteroplacental circulation and asphyxia may develop. *Special attention should therefore be paid to the status of the parturient and the intrauterine foetus during the second stage of labour.*

The obstetrician should systematically supervise the general condition of the parturient, observe the colour of her skin and visible mucosa, take the pulse and measure blood pressure, ask questions concerning the subjective condition of the patient (headache, deranged vision, etc.). The character of labour (strength, duration and frequency of contractions), and the status of uterus should be assessed. The degree of uterine contraction and relaxation, tension of the ligaments, and the height of the contraction ring should be determined by palpation. The status of the lower uterine segment (the absence of abnormal thinning or painfulness) should be observed.

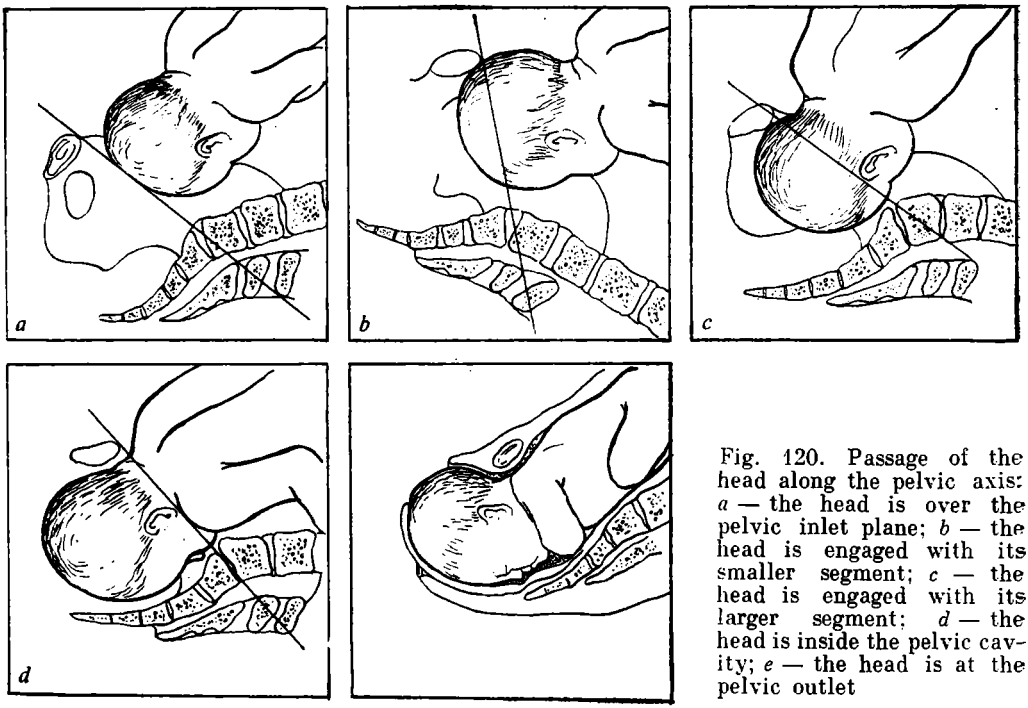

Fig. 120. Passage of the head along the pelvic axis: *a* — the head is over the pelvic inlet plane; *b* — the head is engaged with its smaller segment; *c* — the head is engaged with its larger segment; *d* — the head is inside the pelvic cavity; *e* — the head is at the pelvic outlet

The progress of the presenting part through the birth canal is established during the expulsive stage of labour by repeated obstetrical examinations. The position of the foetal head relative to the various planes of the small pelvis is determined using the third and the fourth manoeuvres but the vaginal examination gives more dependable information. The foetal head position is defined in the following terms:

1. The *head is floated above the pelvic inlet plane* (Fig. 120, *a*). The entire head is above the pelvic inlet. It easily moves (is ballotable) or is fixed against the pelvic inlet. The vaginal examination shows that the pelvic cavity is unoccupied, the head is floated high, it does not interfere with the palpation of the iliopectineal line or the promontory (provided it can be reached by the finger); the sagittal suture aligns with the transverse diameter, and the anterior and posterior fontanelles are at one level (in the occiput presentation).

2. The *head is engaged with its smaller segment* (Fig. 120, *b*). The head is immobile, its greater part is above the inlet plane, and a small portion of the head has descended below the inlet plane. The vaginal examination shows that the sacral cavity is unoccupied. A flexed finger can reach the promontory (if it can in general be reached). The internal surface of the symphysis is free to examination, the sagittal suture aligns with the transverse or slightly oblique diameter.

3. The *head is engaged with its larger segment* (Fig. 120, *c*). The external

examination shows that the head has wedged below the inlet plane with its larger segment (the head has descended into the pelvic cavity). The vaginal examination shows that the head covers the upper third of the symphysis and the sacrum, the promontory is inaccessible, the ischial spines are easily palpable. The head is flexed, the posterior fontanelle is below the anterior one, the sagittal suture is aligned with the transverse or slightly oblique diameter.

4. The *head is in the wide part of the pelvic cavity.* Only a small part of the head (sinciput) can be palpated through the abdomen. The vaginal examination shows that the head has passed by its wider part through the wide part of the pelvic cavity, and two thirds of the inner surface of the symphysis and the upper part of the sacral cavity are occupied by the head. The fourth and the fifth sacral vertebrae and the ischial spines can easily be palpated. The sagittal suture aligns with one of the oblique diameters.

5. The *head is in the narrow part of the pelvis* (Fig. 120, *d*) and is not palpable. The vaginal examination shows that two upper thirds of the sacral cavity and the entire inner surface of the symphysis are occupied by the head. The ischial spines can be reached with difficulty. The head is close to the pelvic floor. The internal rotation is not complete, the sagittal suture aligns with an oblique diameter, close to the anteroposterior diameter.

6. The *head is at the pelvic outlet* (Fig. 120, *e*) and is impalpable through the abdominal wall. The sacral cavity is completely occupied by the head, the ischial spines are impalpable either, and the sagittal suture aligns with the anteroposterior diameter.

During normal labour, the head steadily progresses through the pelvis and it does not rest for a long time in any of the pelvic planes. If the head stops progressing for a long time, it indicates the atony of labour or that the foetus has met an obstacle in its way.

The *foetal heart tones* should be listened to *after each expulsive effort* during the second stage of labour. The danger of foetal asphyxia is much greater during this period than in the first stage (before the loss of the amniotic fluid). Special attention should be paid during auscultation to the cardiac rhythm, frequency, and the tones of the foetal heart. Therefore, in order to better assess the cardiac function of the foetus, its heart tones should not only be *listened to* at 10-15 minute intervals but *counted* as well. The findings should be entered into the delivery record.

Electrophonocardiography, ultrasound, or monitoring should be used only for special indications.

The condition of the external genitalia and the character of the vaginal discharge are very important. Developing oedema of the external genitalia indicates compression of the soft tissues of the birth canal between the foetal head and the bony pelvis. Traces of blood may indicate premature separation of the placenta or laceration of the soft tissues. The presence of meconium in the amniotic fluid (in vertex presentation) is the sign of asphyxia. Purulent discharge from the vagina indicates infection.

During the expulsive stage of labour the parturient lies on the Rakhmanov bed in a comfortable position on her back. By the end of the second stage of labour the parturient lies on her back with the legs and the thighs flexed (Fig. 121). The head end of the bed is slightly raised since the elevated position

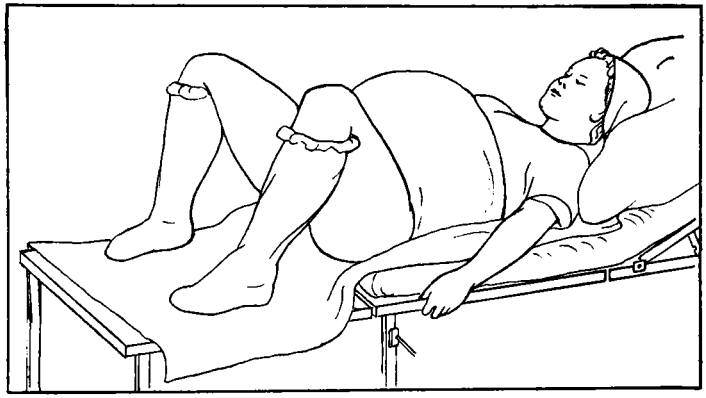

Fig. 121. The parturient position during the expulsive stage

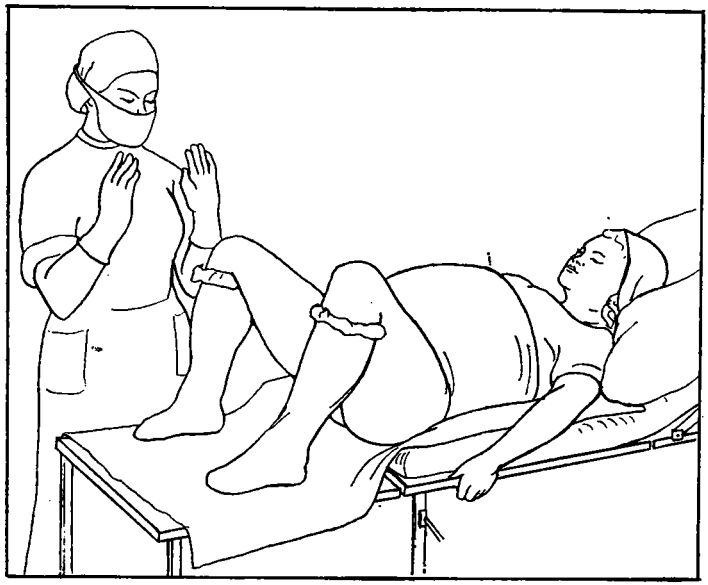

Fig. 122. Crowning of the head. The obstetrician is ready to assist the parturient

of the body facilitates the passage of the presenting part through the birth canal. The mattress is removed from the tail end of the bed to make observation of the external genitalia and the conduct of labour easier.

Should a parturient lie on a common bed, another pillow should be used to raise her head and shoulders. During contractions the parturient should rest with her legs against the bed and grasp the edges of the bed. The parturient can also take hold of two towels tied up to the tail end of the bed (reins) and pull them during contractions.

The obstetrician should be prepared for delivery. The hands should be washed and prepared as for an operation. The external genitalia of the parturient, the inner thighs, the ischial

and anal areas should then be washed with a weak potassium permanganate solution, dried up with a sterile gauze and treated with a 5 per cent iodine solution. The anal region is covered with a sterile gauze or a napkin.* A sterile linen is put beneath the sacral region of the parturient. If the parturient lies upon a conventional bed a pad should be put under the sacrum to facilitate the obstetrical access to the genitalia.

As soon as the obstetrician hands are ready, they are wiped with alcohol. The obstetrician then puts on a sterile gown, overalls, and gloves.

As crowning continues, the obstetrician can limit his care to simple surveillance of the general condition of the parturient, the progress of labour, and the movement of the foetal head (Fig. 122). As soon as the head *has been disengaged* (it does not retract in the intervals between contractions), the obstetrician *commences the conduct of labour*.

The aid of the obstetrician is quite necessary during this stage since the foetal head strongly presses against the pelvic floor to distend it. At the same time the head experiences external pressure from the walls of the birth canal. In this connection, the perineum can be lacerated and the foetal cerebral circulation can be disordered.

The obstetrician conducting labour should therefore (a) protect the perineum from lacerations, (b) aid the foetal progress through the birth canal to protect the foetus from any possible danger.

* S. D. Astrinsky proposed to cover the anal region with sterile cotton wool, and a sterile gauze whose margins should be attached to the perineum and the inner surfaces of the thighs.

The following conditions should be fulfilled:

1. The crowning head should progress through the birth canal steadily and slowly. The gradual movement of the head ensures normal distension of the perineal tissues (without lacerations).

2. The head should crown with its smallest (for a given presentation) diameter. The lesser the girth of the crowning head, the smaller the degree of the perineal distension.

Furthermore, if the head crowns with its smallest diameter, it undergoes lesser deformation due to compression.

In the anterior occiput presentation, the suboccipitobregmatic diameter is the smallest (9.5 cm, girth 32 cm). This diameter should pass the vulvar ring.

The obstetrician should assume the position on the right side of the parturient to aid her from the very beginning of disengagement of the head (during crowning all manipulations are unnecessary).

The aid consists (a) in *precluding too fast progress of the head* to promote its gradual disengagement; and (b) in *preventing premature deflexion of the vertex*. This promotes disengagement of the head in the flexed position in which it passes with its smallest diameter (girth 32 cm). If the head is deflexed, it passes with its occipitofrontal diameter (girth 34 cm) and the soft tissues undergo greater distension.

The manipulations should be fulfilled as follows:

1. *Control of the head progress.* Three fingers of the right hand are placed on the disengaging head. As the contractions are resumed, the obstetrician, holding his fingers against the head with their soft pads slows down the rapid progress of the head and thus prevents premature deflexion of the head

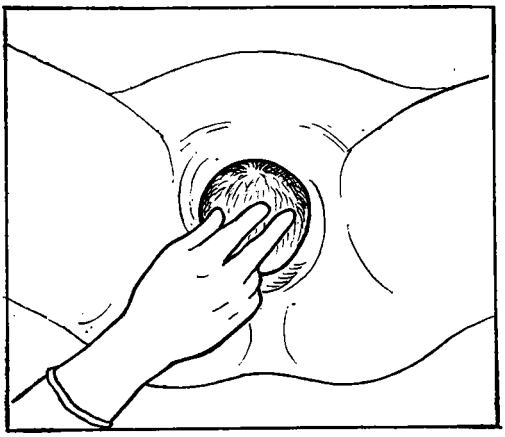

Fig. 123. The obstetrician slows down the rapid expulsion of the head and prevents its premature deflexion (prophylaxis of perineal lacerations)

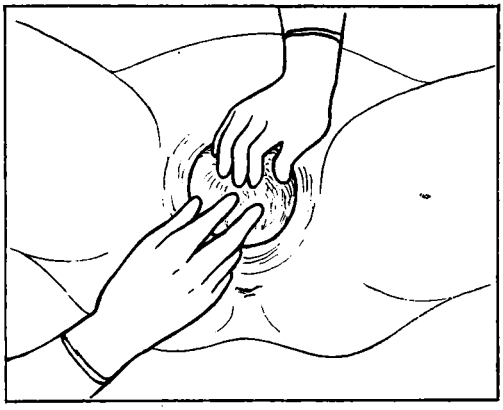

Fig. 124. If the expulsive effort is strong, the left hand of the obstetrician flexes the head toward the perineum (prophylaxis of perineal lacerations)

(Fig. 123). If the force of one hand is insufficient to control the outward movement of the head, the other hand should be used as well. The left hand should then rest on the pubic region, the palmar surfaces of the fingers pressing gently on the emerging head *to flex it toward the perineum* thus controlling its rapid movement (Fig. 124).

Some obstetricians would place the right hand on the perineum to support it, but this should better be avoided since additional pressure on the perineum would interfere with the blood circulation and thus provoke possible lacerations.

The fingers of the left hand should remain in their position on the foetal head in the pauses between contractions, while the right hand should relieve the lateral and the posterior portions of the vulvar ring from distension. The obstetrician resorts to what is known a 'tissue loan'. In the intervals between contractions, the tissues of the clitoris and the labia minora are pulled down from the emerging occiput. Less stretched tissues of the anterior portion of the vulvar ring are moved toward the perineum to preclude excess contraction. The progress of the head and premature deflexion of the head are then controlled again.

2. *Disengagement of the head.* When the occiput has been delivered and the posterior cranial fossa rested against the inferior margin of the symphysis, the *parturient is prohibited to induce new contractions voluntarily.* Beginning from this moment till the entire head is delivered, the parturient should breathe with the open mouth, with the arms flexed on the chest. Rhythmical and deep (without restraint) breath with the mouth open helps the parturient to overcome the contraction. The parturient should preliminarily be informed of the danger of contractions during this period so that she should consciously cooperate with the obstetrician.

As soon as the occipital tuber has been disengaged, the parietal tubers should be released by carefully pulling

off the margins of the vulvar ring. This done, the head is taken by the left hand and deflexed gradually and carefully. During this manipulation, the right hand pulls off the perineal tissues off the head (Fig. 125). During the gradual deflexion, the sinciput is first delivered over the perineum, then follow the face and the chin.

When the head is delivered, the obstetrician checks to see that the umbilical cord does not turn around the neck. If this is the case, the loop of the cord is carefully loosened and put off the head. If the obstetrician fails to do so, the umbilical cord should be cut between two clamps.

3. *Delivery of the shoulders.* The born head turns with its face toward the right or left inner thigh of the mother (depending on the position). If the external rotation of the head is delayed, the parturient is offered to make an expulsive effort. During the induced contraction, the shoulders complete their inner rotation while the delivered head completes its restitution. The shoulders now align with anteroposterior diameter of the pelvis and can be palpated through the vulvar ring. The delivery of the shoulders requires special attention on the part of the obstetrician since the soft tissues of the birth canal undergo significant distension and the perineum can lacerate.

Fig. 125. Delivery of the head: the left hand deflects the head slowly while the right hand pulls down the perineal tissue from the head (prophylaxis of perineal lacerations)

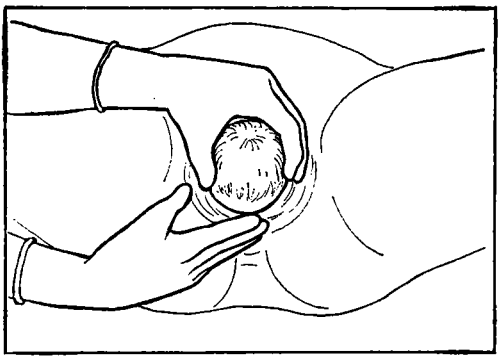

The following obstetrical aid is given to the parturient during delivery of the shoulders. A spontaneously delivered anterior shoulder is pressed against the pubic arch and the perineum is carefully pulled off the posterior shoulder.

If spontaneous delivery of the shoulder girdle is delayed, the following manipulation is allowed: the head is taken by both hands so that the palms rest against the ears (the finger tips should not touch the neck of the foetus to preclude the danger of compression of the vessels or nerves). The head is now pulled carefully downwards until the anterior shoulder is over the pubic arch (Fig. 126, *a*). The head is then slightly raised anteriorly until the posterior shoulder is delivered over the perineum (Fig. 126, *b*). The posterior shoulder can also be delivered as follows: the head is held in the left hand and raised upwards, while the perineal tissues are removed from the shoulder by the right hand (Fig. 127). If these manipulations fail to deliver the shoulders, the forefinger should be inserted into the armpit of the anterior shoulder from the side of the foetal back and the parturient is offered to bear down. The shoulder is pulled gently until it is delivered beneath the pubic arch. The posterior shoulder is then released.

4. As soon as the shoulder girdle is delivered, the chest of the foetus is taken by both hands (Fig. 128) and pulled upwards: the lower part of the foetal body is delivered without difficulties.

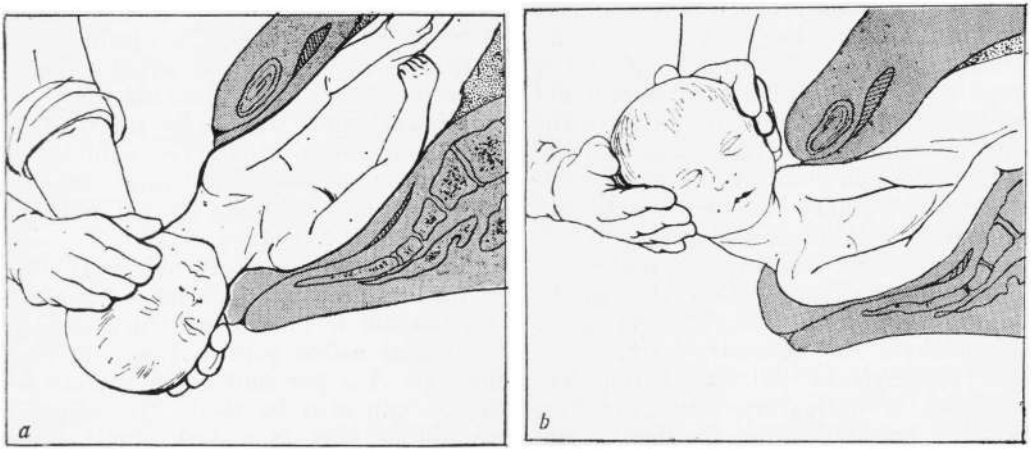

Fig. 126. Delivery of the shoulders:
a — manual assistance in delivery of the anterior shoulder; the delivered head is pulled posteriorly; the anterior shoulder is brought over the pubic arch; *b* — manual assistance in delivery of the posterior shoulder; the head is pulled anteriorly; the posterior shoulder is delivered over the perineum

The postpartum period begins with the delivery of the foetus. It requires a great deal of attention on the part of the obstetrician. The puerpera remains under incessant control, while her *infant is given the first treatment*, which comprises the following:

1. The neonate is wiped with sterile gauze. Using cotton wool, the nose and the mouth of the newborn should be

Fig. 127. Delivery of the posterior shoulder

Fig. 128. Delivery of the body

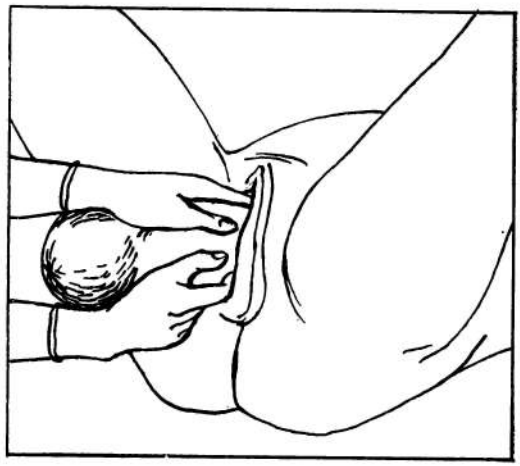

relieved of mucus. The infant is placed between the mother's flexed and abducted legs on a warmed up sterile napkin. The umbilical cord should not be stretched. The obstetrician gives the first examination to the infant and observes its behaviour. A full-term healthy neonate takes the first breath immediately, yields a loud cry, actively moves its legs, and soon urinates.

The obstetrician washes the hands, wipes them with alcohol, and gives the neonate the necessary care.

2. Prophylaxis of ophthalmoblennorrhoea is obligatory since the eyes may be infected when the foetus traverses the birth canal. Gonorrhoeal infection of the eyes evokes grave sequelae, blindness included.

A 30 per cent solution of sulphacetamide is now used to prevent gonoblennorrhoea. Using a dry sterile cotton ball, the cheesy varnish and mucus are removed from the eyelids immediately after birth (moving the ball from the outer canthus to the inner and using a separate piece of cotton wool for each eye). The lower eyelid is then pulled slightly down and a drop of sulphacetamide is administered into the conjunctival sac using a sterile pipette (Fig. 129). Another drop of sulphacetamide should be instilled in two hours after birth. The solution is kept in small vials, and once the vial is opened its contents should only be used within 24 hours.

Fig. 129. Prophylaxis of ophthalmoblennorrhoea. A drop or two of a 30 per cent solution of sulphacetamide is instilled into the conjunctiva

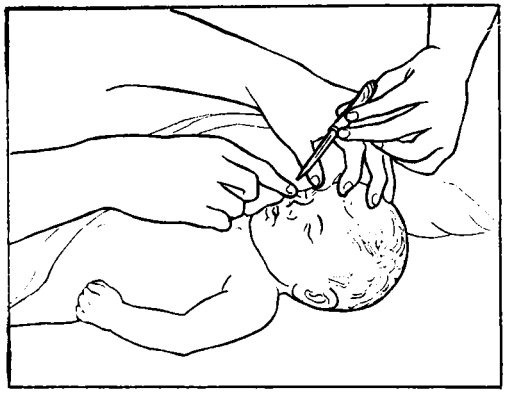

If sulphacetamide is not available, a freshly prepared solution of penicillin (25 000 U in one millilitre of physiological saline solution) can be used instead. A 2 per cent silver nitrate solution can also be used. The solution should be kept in a dark bottle fitted with a ground-in stopper. The solution should be prepared each day and the container should be provided with a label reading the chemical agent in legible characters.

After removal of the cheesy varnish and mucus from the eyelids using dry cotton wool (separate ball for each eye), the lower lid is pulled down and a drop of silver nitrate applied to the conjunctiva.

The eyes should not be washed after instillation of sulphacetamide.

3. The umbilical cord should be tied up after its vessels stop pulsating, which occurs in 2-3 min following the delivery of the infant. In the course of a few minutes that the umbilical cord pulsates, from 50 to 100 ml of the blood is delivered into the vascular system of the foetus from the placenta. As soon as the pulsation discontinues, the cord should be cut off and tied up in aseptic conditions.

The umbilical cord is wiped with a sterile cotton wool ball soaked in alcohol and clamped by Kocher's forceps. One forceps is applied 8-10 cm from the umbilical ring and the other slightly above this point. The cord is cut in between them using dressing

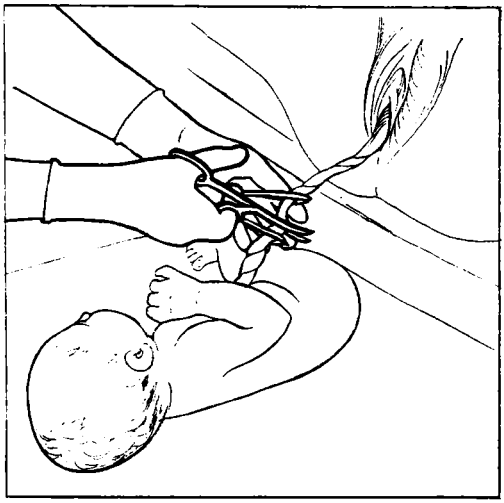

Fig. 130. Cutting the umbilical cord between two clamps

scissors (Fig. 130). The maternal end of the cord is tied up by a silk thread at the pudendal cleft and wrapped in a gauze napkin.

In order to prevent chill, the end of the umbilical cord should be treated on the infant lying on a warm table (irradiated by an electrical heater or by some other means).

The umbilical stump is wiped with alcohol and tied with a sterile tape or a thick silk thread, 1.5-2 cm from the umbilical ring. The ligature is tied once on one side of the umbilical cord and the other time on the opposite side. The second knot should be easy to undo so that it could be tied up tighter if the cord withers or the first knot loosens. The end of the umbilical stump is then cut off 2-3 cm above the knot and the cut surface treated with a 10 per cent iodine tincture. The stump is wrapped in a dry sterile napkin and its ends are tied up at the umbilical ring (Fig. 131). The stump wrapped in the napkin can be placed on the abdomen and pulled tightly to it using a sterile bandage.

Metal staples are now applied to the umbilical stump: as soon as the cord stops pulsating, two staples are applied onto the cord; one staple 10 cm from the umbilical ring and the other 2 cm anteriorly of the former one. The cord between the staples is treated with a 5 per cent alcoholic solution of iodine and cut. The infant is then brought onto the table. The obstetrician washes the hands again, treats them with alcohol, wipes the umbilical stump with a sterile napkin, and presses it between the thumb and the forefinger. A metal (Rogovin's) staple is then loaded into special tongs and the umbilical cord is clamped by at a distance of 0.5-0.7 cm from the lower margin of the umbilical ring. The umbilical stump remains open for daily treatment with a 2 per

Fig. 131. Bandaging the umbilical stump: *a* — the first movement; *b* — the second movement

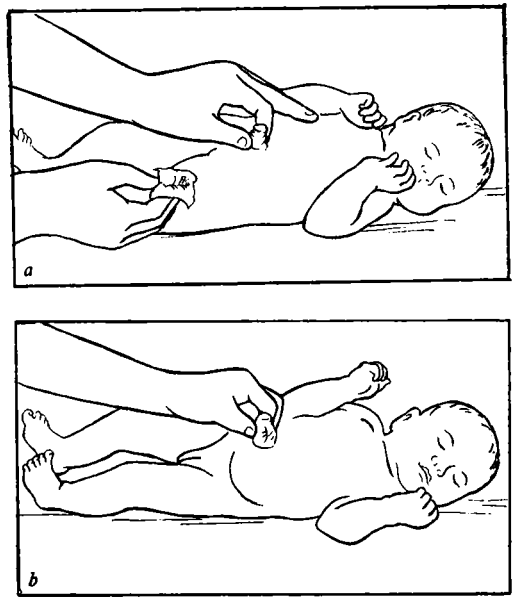

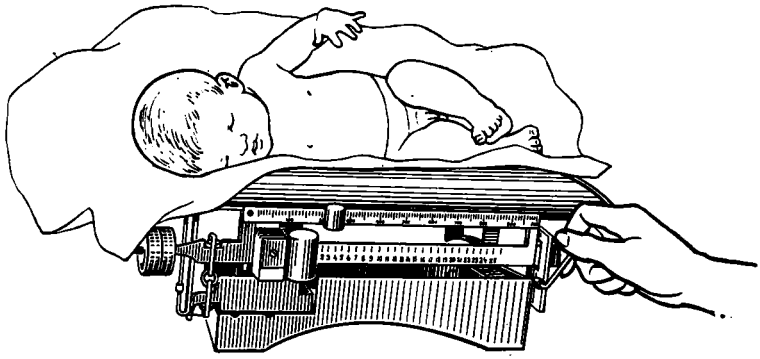

Fig. 132. Weighing the neonate

cent alcoholic solution of boric acid.

As soon as the first treatment is given to the infant, it is weighed (Fig. 132), the length from the vertex to the heels (Fig. 133) and the size of the head and shoulders are measured, and a wrist tag (sterile oilcloth) is fixed on the arm. The identification tag reads the name of the mother, the delivery record number, the infant sex, weight, length, and the date of birth. The infant is then wrapped in a warm vest, a sterile napkin and a blanket, and kept on the warmed table for two hours before moving to the neonate room.

Conduct of Puerperium

During the third stage of labour the placenta is separated and expelled from the uterus.

As has already been said, the separation of the placenta is accompanied by loss of a small amount of blood which is considered physiological. But the loss of blood can be considerable and even dangerous if placental separation and its delivery are abnormal. Bleeding during the third stage of labour may depend on the rupture of soft tissues of the birth canal, and the

Fig. 133. Measuring the neonate length

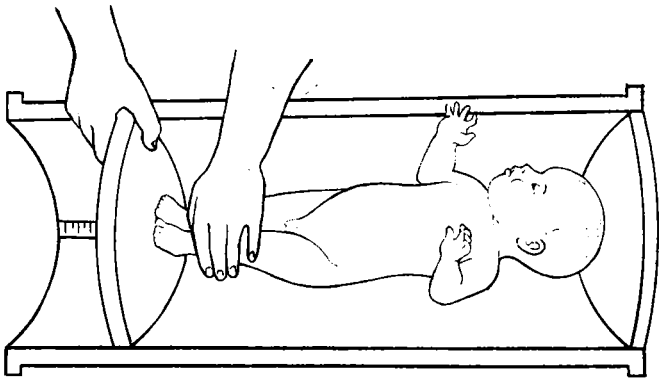

puerpera should therefore be carefully watched by the obstetrician during this period. The general status of the puerpera, the colour of the skin and visible mucosa should regularly be inspected, and the pulse and arterial pressure measured.

If the puerperium is normal, the condition of the woman is good, the pulse is full, rhythmic, and the arterial pressure normal. Indisposition (asthenia, vertigo), pallor of the skin and the mucosa, accelerated pulse rate, the fall in the arterial pressure usually indicate excessive loss of blood and require special measures to be taken.

The amount of the blood shed by the woman during labour should be measured. To that end, a wide enamelled dish or a sterile bedpan should be put beneath the pelvic region. It should be remembered that the amount of the collected blood is not a dependable information on the total amount of blood lost by the woman in labour, since large amount of blood can be retained between the placenta and the uterine wall. The shape of the uterus and the height of its fundus give information concerning the placental separation and the development of the retroplacental haematoma.

If the bladder is full it may inhibit the uterine contractions and thus interfere with normal separation and expulsion of the placenta. Special care should therefore be taken during this period that the bladder is emptied timely.

The placental stage requires *special attention.* All attempts to accelerate the separation and expulsion of the placenta (such as massage of the uterus, pulling on the umbilical cord, etc.) will upset the normal course of separation, interfere with the normal rhythm of uterine contractions and can cause bleeding.

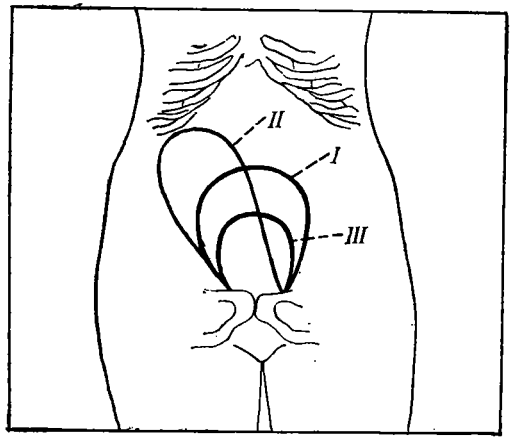

Fig. 134. The uterine level and the shape of the uterus in the puerperium:
I — after the delivery of the foetus; II — after separation of the placenta; III — after the delivery of the placenta

If the condition of the puerpera is normal and bleeding is absent, the obstetrician should wait until the placenta is separated and delivered spontaneously within the lapse of two hours. Should the blood loss exceed 250-300 ml and the status of the puerpera worsen, or else the placental delivery be delayed over two hours, active measures should be taken and the placenta removed manually (either by external manipulations or by introducing the hand inside the uterus).

It is important to know signs of placental separation from the uterine walls and its descent to the lower uterine segment and the vagina.

Important signs of placental separation:

1. The *changes in the uterine shapes and the level of its fundus* (Schröeder's sign). Immediately after the delivery of the foetus, the uterus assumes a rounded shape. The fundus is at the level of the navel. After separation of

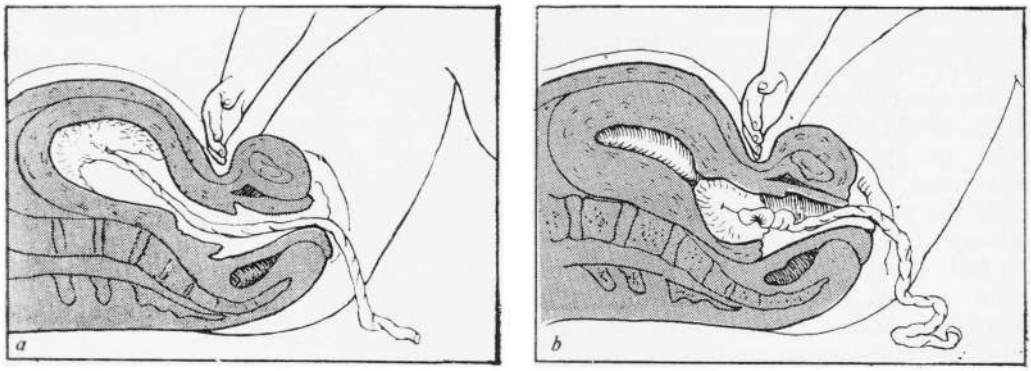

Fig. 135. Küstner-Chukalov sign:
a — the placenta has not separated: the umbilical cord creeps back into the vagina; *b* — the placenta has separated: the umbilical cord remains outside the vagina

the placenta, the uterus flattens, becomes narrower, and its bottom rises (over the separated placenta) above the navel (sometimes to the costal arch). The uterus often deflects to the right (Fig. 134).

2. The *external portion of the umbilical cord becomes longer* (Ahlfeld's sign). The separated placenta descends to the lower uterine segment or to the vagina. The ligature on the umbilical cord (made at the level of the pudendal cleft) lowers 10-12 cm.

3. *Bulging over the symphysis.* When the placenta has separated and descended to the thin-walled lower uterine segment the anterior wall of the segment and the abdomen wall form a protuberance over the symphysis.

4. *Küstner-Chukalov's sign.* If the suprapubic region of the abdomen is impressed by the edge of the palm (Fig. 135), the umbilical cord will be pulled into the vagina with the non-separated placenta and remain outside the vagina with the separated placenta.

The degree of placental separation cannot be assessed only by one of these signs but by a combination of all the signs described. The placenta is normally expelled from the uterus spontaneously within 30 minutes following the foetal delivery. In less frequent cases the placenta and the membranes are separated and expelled in 30-60 minutes, and in rare cases later than in 60 minutes after the delivery of the foetus.

If the placenta is not delivered in thirty minutes, the obstetrician should check the presence of the signs of placental separation. If the placenta has not separated, but the condition of the patient is good and bleeding is absent, the woman is allowed to lie for two hours. Should the placenta be not delivered spontaneously during this period, it shall be removed operatively.

If the signs of placental separation are positive, measures to remove it should be taken immediately.

The bladder is emptied and the puerpera is asked to bear down. The placenta is thus often expelled by the abdominal contractions. If this simple method turns ineffective the following should be done.

1. *Abuladze's method.* As soon as the bladder has been emptied, the uterus should be given a careful massage to

contract it. The abdominal wall is then taken by both hands to form a longitudinal fold (Fig. 136) and the woman is asked to bear down. The separated placenta would normally slide out without difficulty.

2. *Genter's method.* The bladder is emptied and the uterine bottom is brought to the median line. The obstetrician stands on the side of the patient facing her legs. The main phalanges of the clenched fists are placed on the uterine bottom (at the insertion of the fallopian tubes) and a pressure is applied to the uterus in the downward and medial direction (Fig. 137). The woman should not bear down during this procedure.

3. *Credé-Lazarevich's method.* This is a less sparing technique compared with the Abuladze and Genter methods, and it is therefore only used when one of the former two methods fails to give the desirable results. The method consists in the following: (a) the bladder is emptied; (b) the bottom of the uterus is brought in the median position; (c) the uterus is gently rubbed to induce its contraction; (d) the obstetrician stands by the left side of the puerpera, facing her legs, takes hold of the uterine bottom by the right hand so that the thumb is upon the anterior wall of the uterus, the palm is on the bottom, and the four fingers on the posterior surface of the uterus (Fig. 138); (e) the placenta is expressed from the uterus in the anteroposterior direction with simultaneously pressing the uterine bottom in the downward direction and anteriorly along the pelvic axis. The separated placenta is thus easily expressed from the uterus.

As a rule, the placenta and the membranes are delivered simultaneously but sometimes the placenta is delivered first while the membranes still remain in the uterus. The delivered placenta is then taken by the hands and rotated slowly in one direction. The membranes are thus twisted, separated gradually from the uterine walls, and withdrawn

Fig. 136. Delivery of the placenta according to Abuladze

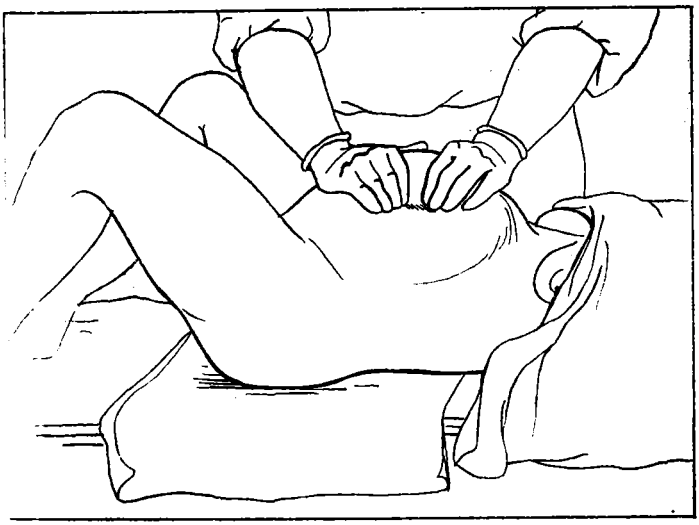

Fig. 137. Genter's method

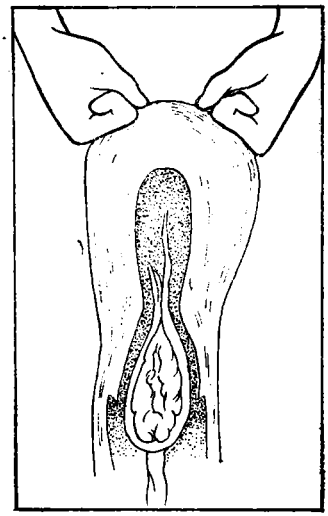

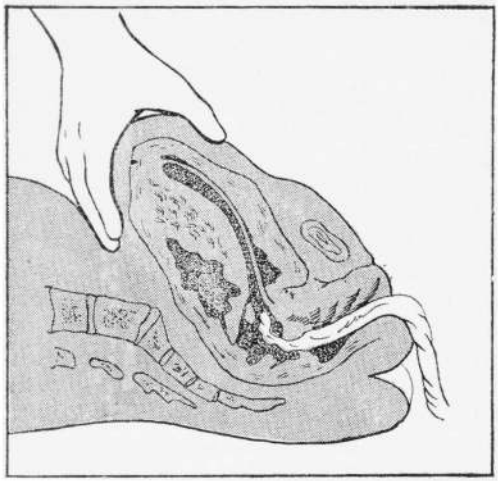

Fig. 138. Credé-Lazarevich method

from the uterus without rupture (Fig. 139, *a*).

Another method to remove the membranes (according to Genter) is known. As soon as the placenta has been delivered, the puerpera is asked to lift the pelvis: the placenta hangs freely from the vagina and thus promotes separation of the membranes by its gravity (Fig. 139, *b*).

The born placenta and the membranes are thoroughly inspected to make sure that whole placenta and membranes have been separated.

The placenta is spread over a flat dish or on the palms with the maternal surface up (Fig. 140) and one portion of the placenta is thoroughly examined after another. The margins of the placenta should be examined with special care: they should be smooth, without remnants of the ruptured vessels.

The membranes should then be examined. To that end the placenta is turned over with the maternal surface down and the foetal side up (Fig. 141, *a*) The membranes are held by the fingers by the edges of the ruptured site and spread in an attempt to restore their ovoid shape (Fig. 141, *b*). The condition of the amnion and the chorion should be examined with special care,

Fig. 139. Delivery of the membranes:
a — twisting into a cord; *b* — Genter's method. The parturient lifts the pelvis, the placenta hangs down and pulls the membranes

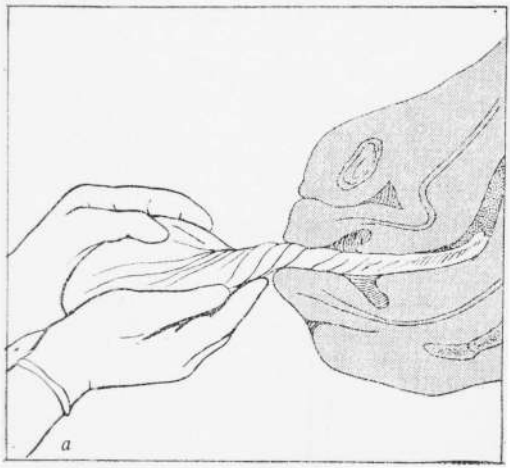

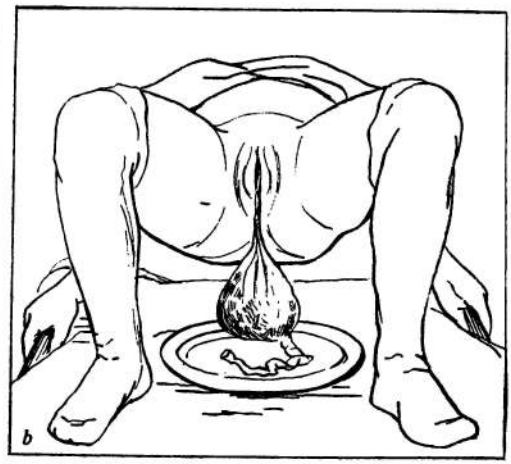

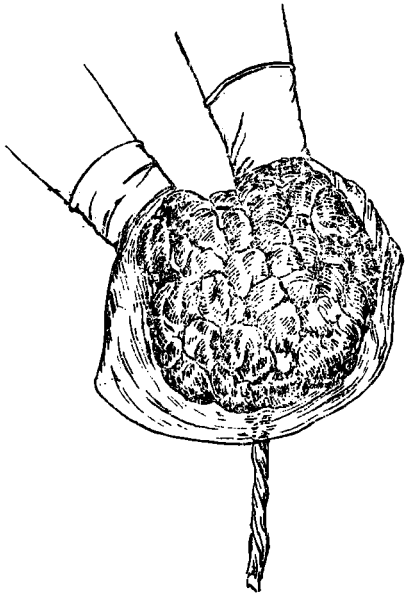

Fig. 140. Examination of the maternal surface of the placenta

seeing to it that there are no ruptured vessels (leading from the placental edge) in between them. The presence of such vessels (Fig. 142) indicates that a portion of the placenta still remains in the uterus. The inspection of the membranes and the site of their rupture gives additional information concerning the site of the placental attachment to the uterine wall. The closer the site of the ruptured membranes to the placental margin, the lower the site of the former placental attachment to the uterine wall.

The obstetrician must be sure that the entire placenta has been delivered since the presence of its separate parts in the uterus is fraught with danger of bleeding in the puerperium. The bleeding may become profuse and present danger to the life of the puerpera. The retained parts of the placenta may also become the cause of puerperal sepsis.

Fig. 141. Examination of the membranes

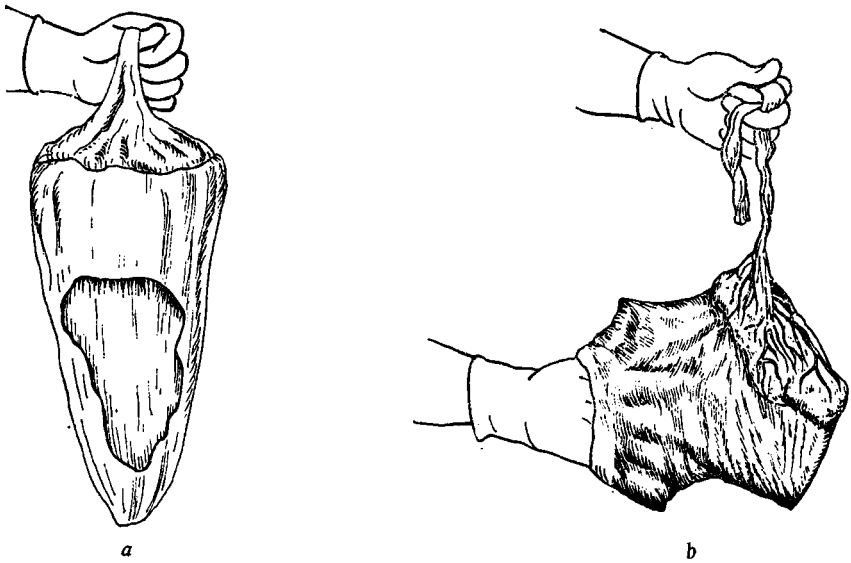

a *b*

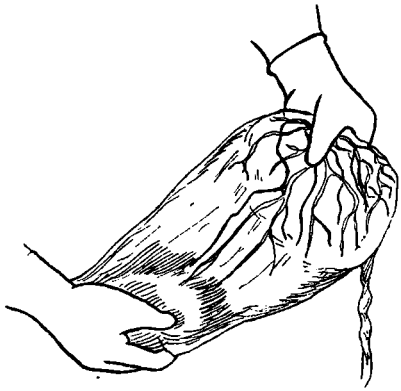

Fig. 142. Ruptured vessels indicate that a placental lobe has remained in the uterus

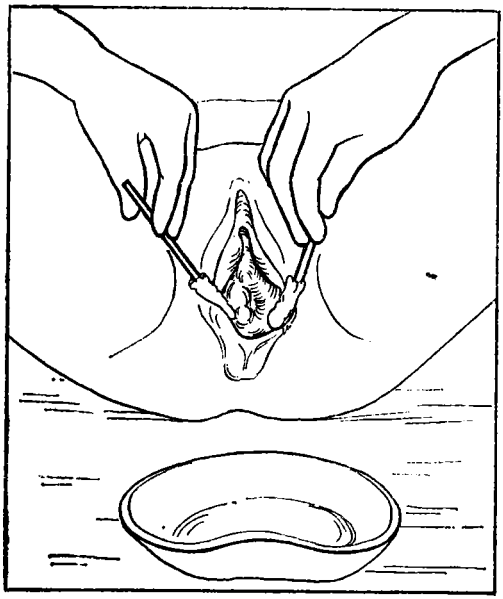

Fig. 143. Examination of the perineum and the vestibule of the vagina after the delivery of the placenta

If parts of the placenta remain in the uterus, they should immediately be removed manually after the obstetrician discovers any defect in the placenta. If parts of the membranes remain in the uterus, they do not require manual removal since they will be expelled spontaneously together with the uterine discharge.

The placenta should be measured and weighed, and the findings put into the delivery record. (After examination the placenta should be burned or otherwise discarded in accordance with special sanitary regulations.) The total amount of the blood lost during the delivery of the placenta and immediately after the delivery is then measured.

As soon as the placenta has been delivered, the external genitalia, the perineal area, and the inner surfaces of the thighs are washed with warm disinfectant solution, dried up with a sterile napkin, and inspected. The external genitalia and the perineum are inspected first, then the lips are separated by sterile pads and the vestibule is inspected (Fig. 143). The cervix should be inspected with specula, especially in the primipara and after operative interventions.

All open lacerations of soft tissues in the birth canal are the site of possible ingress of infection. The lacerations of perineum also provoke ptosis and prolapse of the sexual organs. Laceration of the cervix causes its inversion, chronic endocervicitis and erosion. All these pathological processes can provide conditions for the development of the cervical cancer. All lacerations of the perineum, vaginal walls, and the cervix should therefore be thoroughly remedied immediately after delivery. Suturing lacerated tissues in the birth canal is the prophylaxis of puerperal infections, ptosis of the genitalia and other gynaecological diseases.

After the examination is over, the puerpera is dressed in a clean gown, the linen is changed, the woman is

covered with a blanket and watched at the delivery room. The surveillance comprises the assessment of the general condition of the puerpera, her pulse is counted, and subjective condition inquired. The uterus is palpated from time to time and the absence of vaginal bleeding is checked. It should be noted that bleeding often occurs during the first hours following the delivery which is mainly due to the decreased uterine tone.

If the puerpera is in good condition, has no complaints, her pulse is full and of normal rate, the uterus is firm, and the bleeding is only scarce, the puerpera is brought to the recovery room in 2-3 hours. The delivery record should be brought to the recovery department together with the puerpera.

Chapter Ten

PAIN RELIEF IN LABOUR

Most women feel pain during labour and delivery, but the degree of painful sensations varies widely. Many women feel strongest pain, especially during the first and the second stages of labour.

The desire to relieve or remove painful sensations appeared among obstetricians of ancient times, but it was only during the first half of the past century that scientifically grounded methods to relieve pain were developed with the discovery of the anaesthetizing effect of ether and other substances.

Ether was first used in obstetrical practice by N. I. Pirogov for application of forceps (1847) and by J. Simpson for the rotation of the foetus (1847). Ether and chloroform were later used for pain relief in labour.

In the 60's of the past century, N. A. Sochava suggested the use of a mixture of chloroform and alcohol for anaesthetic purposes. Many other substances, such as nitrous oxide (Klikovich, 1881), chloral hydrate (Svyatlovskaya, 1873), morphine and other anaesthetics, barbiturates, magnesium sulphate in combination with pantopon, procaine hydrochloride solution, etc., were later tried to relieve pain in labour. Prominent obstetricians, such as A. Ya. Krassovsky, I. P. Lazarevich, V. M. Florinsky, and others studied the problems of pain relief in labour, but it was only after the Great October Socialist Revolution that it has become possible to give a new impetus to the study of this problem and to incorporate the anaesthetic methods in the obstetrical practice.

In 1936 A. Yu. Lurié put forward an idea of mass-scale pain relief in labour, and at the present time the parturients are relieved from labour pain not only in large cities but also at small rural obstetrical institutions.

The wide spread of pain relief was promoted by the study of the role played by pain in labour. It has been established that pain is not necessary in the normal course of labour. Normal labour and delivery are sometimes associated with little pain or are painless altogether. Furthermore, observation of the parturients has shown that strong and prolonged pain exhausts the nervous system and is harmful to the woman. Severe pain may interfere with normal course of labour causing uterine atony, and irregular uterine and abdominal contractions. It has also been established that anaesthesia favours the course of labour. The removal of labour pain often restores the disordered labour activity and promotes successful outcome of labour.

Along with the wide incorporation of pain relief methods into obstetrical practice in this country, an intense research of new effective methods of anaesthesia is being carried out. *Psychoprophylactic method* of preparing the pregnant for labour developed by

I. Z. Velvovsky, the pupil of K. I. Platonov, is now widely used. The method is advantageous over the drug anaesthesia and is recommended for use in all obstetric institutions. Drug anaesthesia is now only used in cases where psychoprophylaxis is not available or proves ineffective.

Psychoprophylaxis of Labour Pain

The method is based on the study of causes of labour pain. The object of psychoprophylaxis is to remove pain by the action on the central nervous system of the woman.

The nerve endings (interoceptors), nerve fibres and plexus of the uterus and other parts of the birth canal are excited during labour. The uterine interoceptors are excited due to contractions of the uterine muscles and distension of the lower uterine segment and the cervix. The painful sensations mainly depend on the excitation of the nerve endings in the dilating cervix. As the head of the foetus descends it excites the nerve plexus in the pericervical region; the distension of the uterine and peritoneal ligaments, and the compression of the blood vessels whose walls are innervated with highly sensitive nerve elements, also provoke pain. An additional source of pain during the second stage of labour is the excitation of nerve elements in the perineum and external genitalia.

The excitation of the uterine nerves is transmitted through the nerve trunks to the central nervous system and the pain is reflected in the lower abdomen, the sacrolumbar region, in the groins, and the upper parts of the thighs.

Emotional upsets, the conviction that labour pain is inevitable, the anticipation and fear of pain, the fear of labour outcome and of her future baby, etc., are another (psychogenic) component of labour pain. These emotions inhibit the cerebral cortex and interfere with normal relationship between the cortex and lower departments of the central nervous system. As a result of summation of all these components, the excitation of the nerve endings in the uterus is perceived by the woman as very strong pain.

The nerve elements of the uterus and other parts of the reproductive system are always excited during labour, but painfulness of the subjective feelings is different in women and depends on the functional characteristics of the nervous system. Clinical observations show that labour in some women is associated with little pain or is painless altogether. Many women experience moderate pain and withstand it with patience and without fear. Their behaviour is readily controlled by the medical personnel. This reaction to pain usually occurs in even-tempered women with balanced nervous system.

Women with unbalanced character are susceptible to attacks of fear and other adverse emotions. The pain threshold is low in them and the excitation of nervous elements associated with uterine and abdominal contractions is sensed as strong pain by them. Such parturients are restless, their behaviour is difficult to control and this interferes with normal conduct of labour.

Hence, the response of the parturient to excitation of the nervous system of the reproductive tract by equal stimuli may be different. The feeling of pain depends on the features of activity of the higher regions of the central nervous system, the cerebral cortex.

The Soviet obstetrical science has long studied the dependence of subjective perception of labour pain and the behaviour of the parturient on the condition of her nervous system, and tried to remove pain by acting on the psyche of the woman. During the past decade the method known as psychoprophylaxis has been successfully used to control labour pain. This is attained by the appropriate action on the higher nervous system of the parturient. The object of psychoprophylaxis is to remove psychogenic component of labour pain by persuading the woman that pain is not inevitable, to relieve her of the pressing fear, and to give the woman a new concept of labour as a physiological process which is not necessarily associated with pain. Psychoprophylaxis thus relieves or even completely removes pain during labour and delivery.

The woman must be informed that her labour may be painless provided she fulfils all requirements of the obstetrician. During psychoprophylactic treatment the woman is taught how to behave correctly during labour. She is given the necessary information concerning physiology of labour and its clinical course, and is also acquainted with the feelings that she may experience in various stages of labour, with a special emphasis on the fact that pain is not inevitable.

Psychoprophylaxis is a system of measures that should be undertaken from the very beginning of pregnancy, and especially four weeks preceding labour (as well as during labour).

During pregnancy the woman is given a thorough examination (the study of the anamnestic data, the general and obstetrical examination). The obstetrician reveals the attitude of the patient to pregnancy, future labour and delivery. He tries to remove fear of labour and to persuade the patient that her labour will be painless and successful. The psyche of the pregnant should be steadily and favourably acted upon during each prenatal visit to the doctor.

Beginning with the 35 or 36th week of pregnancy, the pregnant should be given the necessary information concerning the nearing labour and be taught how to behave during labour so that it may be accomplished without pain.

A special room should be available for the purpose. It must be equipped with all visual aids that might be necessary. If however this may be impossible for some reason, the pregnant can be taught in an ordinary room.

Normally four lessons (4 or 5 weeks before labour) would be enough for successful preparation of the patient for labour provided all requirements of such lessons are fulfilled (undue fears are removed and the pregnant becomes convicted in successful outcome of her labour). In compliance with the recommendations of the Ministry of Health of the USSR (1954), the prenatal training should include the following.

The *first lesson*. The pregnant is acquainted with the anatomy of the female genitalia and the changes that occur in her body. Labour and delivery are described as a normal physiological process. Three stages of labour are described: characteristics of the first stage of labour, subjective feelings of the parturient, uterine contractions, their length and frequency; changes occurring in the female genitalia during the first stage of labour, their physiological character (dilation of the cervix); the role of the membranes and the amniotic fluid. Attention is drawn to the fact that the parturient spends much energy during labour and that the woman should spare her efforts for the main stage of labour, expulsion of the foetus; she should assume

a comfortable position, take food regularly and follow all instructions of the medical personnel.

The *second lesson.* The woman is instructed how to behave during regular contractions and during the entire first stage of labour. The pregnant is trained physically to perform exercises which promote normal course of labour and reduce painful sensations.

1. Lying quiet.
2. Deep and rhythmic breathing during uterine contractions.
3. Inspiration and expiration of air with simultaneously rubbing the lower part of the abdomen by finger tips of both hands, from the median line over the pubis lateralward and upward.
4. Rubbing the skin of the sacrolumbar region simultaneously with regular breathing.
5. Pressing the skin to the inner surface of the iliac crests at both anterior superior spines and the outer angles of the Michaelis rhomboid. The skin at the anterior superior spines is pressed by the tips of the thumbs, the palms at the thighs, while at the anterior angles of the Michaelis rhomboid, by the clenched fists put beneath the rhomboid.
6. Counting uterine contractions.
7. Resting in the pauses between contractions and dozing if possible.

The exercises should be well mastered by the pregnant and performed in the order suggested by the obstetrician.

At the end of the lesson the pregnant is acquainted with the causes that may intensify pain during labour (undue fears, restlessness, full bladder, etc.). The pregnant is explained that these causes of pain may be timely and fully removed by correct behaviour during labour.

The *third lesson.* The pregnant is acquainted with the second and third stages of labour: subjective feelings of the parturient woman during this period, recommended positions at the beginning and at the end of the expulsive period of labour. The pregnant is taught how to hold her breath during abdominal contractions. She is explained that in order to intensify the efficiency of abdominal contractions, it is necessary to hold breath for 10-15 sec after taking a deep breath. This intensifies the muscular tension. The procedure should be repeated two or three times during each next contraction. The pregnant is taught how to breathe and relax her muscles in order to reduce the expulsive effort during disengagement of the head. The placental stage, its duration and the character of contractions during this stage are then described.

The *fourth lesson.* During this lesson all the previous material is revised in short and the knowledge acquired by the pregnant during the three lessons is checked.

Four lessons will be sufficient provided the pregnant has been given psychoprophylaxis during earlier prenatal visits to the doctor. Otherwise five or six lessons are required to be taught. In order to complete the prenatal training of the pregnant, she is recommended to repeat the exercises at home on her own. The woman is acquainted with the regulations of the lying-in hospital. She is informed of the manipulations that may be performed on her during labour (external and vaginal examinations, intravenous administrations of glucose, breathing with oxygen, etc.). The pregnant is warned that she should strictly follow instructions of the medical personnel. The necessity of taking food regularly is explained as well.

During visits of the nurse to the pregnant's home, she should revive the information that the pregnant acquired during her prenatal visits to the doctor.

The efficiency of psychoprophylaxis depends largely on the organization of health education at a given lying-in hospital and the skill of the personnel. Their attitude to the pregnant should be quiet and benevolent. The personnel is prohibited to discuss possible complications of labour in the presence of parturient women. Inadequate behaviour of the medical personnel, inconsiderate conversations, lack of care in their attitude to the parturient will reduce the effect of psychoprophylactic preparation of the woman for her labour.

The obstetrician conducting labour takes a constant watch on the parturient, encourages her, reminds her of the methods how to lessen and remove labour pain and tries to convince her that the outcome of labour will be successful. All the examinations of the parturient, the conduct of labour, and

other manipulations should be done calmly, without undue fuss.

At the end of labour, the obstetrician evaluates the efficacy of psychoprophylaxis by taking into account (1) the conduct of the woman during labour, (b) the report of the parturient on her subjective condition and sensations. The efficacy of psychoprophylaxis is thus assessed in the following terms: 'complete effect', 'partial effect', 'no effect'.

If a pregnant was not given instructions during her prenatal visits, she should be prepared for labour on admission to the lying-in hospital. The preparation consists in revealing the fears of the pregnant and persuading her in the successful outcome of labour. The efficiency of pre-labour talks is much lower than prolonged psychoprophylactic treatment.

At many obstetric establishments psychoprophylaxis is effectively combined with the complex of hygienic exercises for the pregnant (physioprophylactic preparation for labour).

Drug Anaesthesia

Drug anaesthesia of labour is indicated (a) in the absence of psychoprophylactic effect, and (b) if the pregnant was not given prenatal psychoprophylactic treatment.

Drugs used for pain relief in labour should effectively remove pain, and be harmless to the mother and the foetus. Anaesthetics should not weaken labour.

Anaesthetics are given to the parturient at the first stage of labour, when regular contractions begin and the endocervical canal opens 4-6 cm. Only healthy women with normal labour are allowed to take anaesthetics. The condition of the parturient requires thorough observation after giving her anaesthetics; the foetal heart tones and the character of labour should be carefully watched as well.

The experience with relieving pain in labour shows the expediency of combining psychoprophylaxis (if its effect is incomplete) with drug anaesthesia, which produces sedative and analgesic effect and relieves labour.

Experienced obstetricians give anaesthetics to parturients with various diseases by skilfully choosing a suitable drug and carefully watching the condition of the patient and the foetus. The administration of anaesthetics is immediately suspended if the obstetrician reveals any sign of disorder that may arise in the mother or the foetus, and if any deviation from the normal course of labour develops.

Many drugs and methods to relieve pain in labour are used now. Some of them are less effective or adversely affect the course of labour or the foetus and their practical use is thus limited. For example, chloroform, scopolamine, chloral hydrate, paraldehyde and some other substances, which were popular in the past are now seldom used, or not used at all.

Anaesthesia is given to patients by a skilled anaesthesiologist or (in simple cases) by a nurse.

A suppository (belladonna extract 0.015 g, pantopon 0.02 g, antipyrine 0.5 g and butter cacao 1.5 g) can be given during the first stage of labour. Antipyrine can be replaced by an equal dose of acetylsalicylic acid, or amidopyrine.

The suppository is inserted into the rectum by a rubber gloved finger. If necessary, another (only one!) suppository can be given not earlier than in two hours following the first administration.

A liquor of the following composition is given during the second stage: papaverine hydrochloride 0.02 g, belladonna extract 0.02 g, ethyl alcohol 15.0 g, sugar sirup 20.0 g (for one intake).

Another liquor can be given as well: antipyrine 0.5 g, ethyl alcohol 15.0 g, sugar sirup 15.0 g.

A menthol pencil can be given during the expulsive stage (menthol 20 per cent, paraffin 80 per cent). The pencil is rubbed into the skin of the lower abdomen and the sacrolumbar region for 3 minutes (the Michaelis rhomboid).

In addition to suppositories and liquors, there must be available substances for subcutaneous, intramuscular and inhalation administration.

A method of anaesthesia with pantopon and magnesium sulphate (pantopon solution 2 per cent, 1.0 ml, magnesium sulphate solution 20 per cent, 5.0 ml) is very simple. The solution is given intramuscularly (into the upper outer quadrant of the buttock) in a single injection.

Thecodin, promedole, aprophen, etc., are used for pain relief in labour.

Thecodin is given as a 1 per cent solution, 1.5 ml subcutaneously. The anaesthetic effect lasts two or three hours. Thecodin can be given together with magnesium sulphate (1 ml of 1 per cent solution subcutaneously and 4 ml of 25 per cent solution intramuscularly). Thecodin has a marked analgesic effect (even when half a dose is given) against the background of premedication with white streptocide (streptocidum album), 1.5-2 g (after A. P. Nikolaev).

Promedole has an analgesic and spasmolytic effect (facilitates opening of the cervical canal). Promedole is given subcutaneously as a 1 per cent solution (1-2 ml). The effect of this preparation shows in 10-20 minutes following the administration and lasts 2-4 hours. It can be given together with thecodin (2 ml of a 1 per cent promedole solution and 0.5 ml of 1 per cent thecodin solution subcutaneously).

Aprophen is a strong analgesic and spasmolytic. It is given subcutaneously or intramuscularly (1 ml of 1 per cent solution). It is given also in combination with isopromedole (intensifies the anaesthetic effect and accelerates opening of the cervix).

Nitrous oxide, ether, trilene and other substances are also used as narcotics.

Nitrous oxide is inhaled together with oxygen (80 per cent of nitrous oxide and 20 per cent of oxygen). It is given only during the first and the second stages of labour using a special mask.

The parturient is acquainted with the method of operating the gas mask and later uses it independently during uterine contractions. The mask is removed in the pauses. The analgesic effect of nitrous oxide develops quickly and disappears immediately when the use of the mask is suspended.

A mixture of nitrous oxide and oxygen is an effective anaesthetic means which has no adverse effect on the mother or the foetus.

Trilene (together with oxygen) produces the same effect as nitrous oxide (inhaled during contractions). It is an effective analgesic.

Ether has long been used to relieve pain during labour. First it was given in drops (using a mask), and mainly in the second stage of labour. Ether was inhaled during abdominal contractions and its inhalation was suspended in the pauses. At the present time ether is given together with oxygen using a

special apparatus. The first effect of ether (analgesia, bewilderment) is only used. This is attained by intermittent inhalation of ether and oxygen.

Conduction anaesthesia can be given at the beginning of the expulsive stage. It is used to block all rami of the pudendal nerve by procaine hydrochloride solution.

The study of new methods of anaesthesia is being continued. Electroanalgesia, combination of analgesics and spasmolytics, sedatives (seduxen and others) and analgesics (promedole and others) are being tried. Buscopan, viadril, neuroplegics and other preparations are used at obstetrical institutions under the supervision of an anaesthesiologist in cases of complicated labour and for special indications.

Chapter Eleven

NORMAL PUERPERIUM

The puerperium begins with the delivery of the placenta and continues for six to eight weeks. Almost all changes that occurred in the female body during pregnancy and labour subside by this time. The reproductive tract almost completely recovers. If the woman does not feed her infant with the breasts, her menstrual function is restored. In nursing mothers the menstrual function is restored later, often only after the suspension of breast-feeding. In rare cases the menstrual function is restored in nursing mothers in six to eight weeks after delivery.

Changes in the Puerpera

Involution (back development) of the genitalia. After delivery of the placenta the uterus contracts to a globular shape. Its consistency is firm and mobility is high (due to distension of the ligaments). The fundus of the uterus is at the level of 1-2 finger-breadths below the navel immediately after childbirth. This is due to the increased tone of the vagina and the muscles of the pelvic floor. The uterus can easily be displaced upwards and to either side. When the bladder is full, the bottom of the uterus can rise to the costal arch. Immediately after delivery, the uterine cervix is a thin-walled bag, the endocervical canal easily passes a hand, the margins of the open external os are folded in the vagina. The inner surface of the uterus is a wound formed after separation of the placenta and the membranes. The average length of the uterus immediately after delivery is 15 cm (from 13 to 16 cm). Its width at the level of tubes insertion is 12-13 cm. The uterus weighs 1000 g.

The vagina is flabby and wide, the external genitalia are oedematous, the pudendal cleft is open. The external genitalia and the vaginal walls are often lacerated or eraded.

The uterus decreases in size after delivery, the cervix recovers its shape, and the internal surface of the uterus is healed.

The volume of the uterus diminishes due to contractions of the musculature (postnatal contractions), which cause anaemization and fat dystrophy of the part of muscular fibres.

The *degree of uterine contraction can be assessed by the level of its fundus.* During the first ten or twelve days following the delivery, the uterine bottom lowers one finger-breadth daily. In one or two days after childbirth, the uterine bottom is at the level of the navel (provided the bladder is empty); by the third day it is one or two finger-breadths below the navel; by the fourth day, two or three finger-breadths below the navel; by the fifth day it is midway between the navel and the superior margin of the symphysis; by the sixth

day it is one finger-breadth below the fifth day level; in seven days the fundus is three finger-breadths above the symphysis, in eight days it is two finger-breadths above the symphysis, and by the tenth or twelfth day the fundus of the uterus lowers below the superior margin of the symphysis.

The back development of the uterus is determined by measuring the level of its bottom using a tape (with the bladder emptied). The width and the weight of the uterus decrease along with its diminishing length.

The recovery of the cervix begins from its distal portions; the internal os closes first and the external os does so later. In three days following the delivery, the internal os passes a finger and by the seventh or the tenth day it closes. The external os closes by the third week after delivery.

The endometrium is recovered along with shrinkage of the uterus. It is recovered through the proliferation of glandular epithelium and the stroma of the basal layer of the endometrium. The recovery of the mucosa is actually the healing of the wound surface of the uterus. A leukocyte (granulation) torus is formed during healing of the wound surface of the uterus which prevents infection of the uterine walls and other parts of the reproductive tract.

Epithelization of the inner (wound) surface of the uterus is completed by the tenth day and the endometrium is completely recovered by the twentieth day after delivery.

The rate of back development of the uterus depends on the following: the general condition of the puerpera, her age, the character of past labour, breast-feeding, etc. The involution of the uterus is retarded in asthenic patients and in multiparas, in aged primipara, and in cases with complicated labour, etc. The uterus is recovered much faster if the woman nurses her baby.

The tone of the vagina is restored after labour, its volume diminishes, oedema and hyperaemia subside, lacerations and erosions of the external genitalia, the vagina and the cervix are healed.

The uterine ligaments gradually shorten, the uterine tubes and the ovaries assume their former position and status. The abdominal wall shrinks gradually as well, and the customary tone of the pelvic floor muscles is restored. In some women the former resilience of the abdominal wall is not recovered completely. The scars of pregnancy (striae) become white, the pigmentation of the white line disappears or strongly diminishes.

Lochia. As the endometrium is being recovered, postnatal discharge from the vagina, known as lochia, occurs. Lochia is discharged from the healing wound inside the uterus and is thus the wound secretion. Lochia consists of blood serum, remnants of the falling off decidua, and leukocytes. During the first days following the delivery, lochia contains much blood.

During the first three or four days the lochia is bloody (lochia rubra). Later lochia becomes paler and resembles serous fluid containing a small amount of blood (lochia serosa). By the tenth day lochia contains no blood (lochia alba). The amount of the vaginal discharge after delivery decreases gradually. By the third week it is scant and it discontinues by the fifth or sixth week after delivery. If the involution of the uterus is slow, the vaginal discharge persists for longer time and it contains blood. If the internal os is obstructed in a flexed uterus, the lochia can accumulate in the uterine cavity (lochiometra).

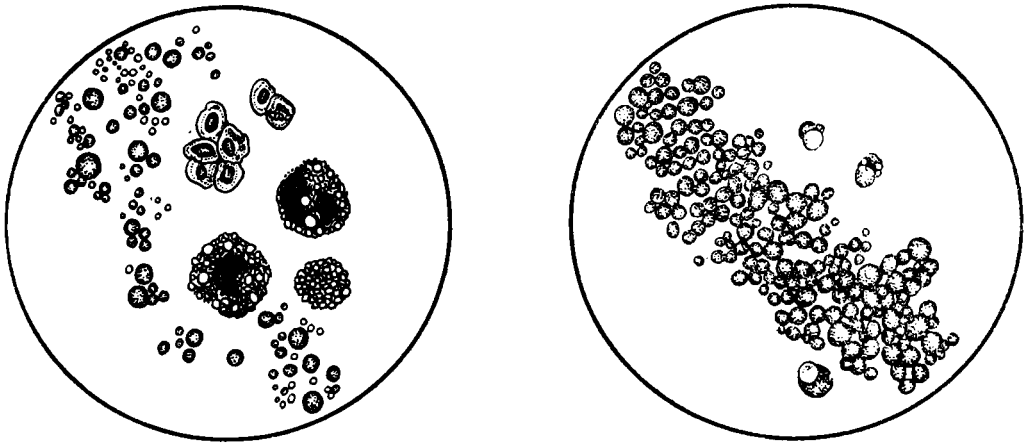

a b

Fig. 144. Microscopic picture of milk and colostrum
a — colostrum; fat droplets and colostrum corpuscles can be seen; *b* — milk; fat droplets alone are seen

The *mammary glands*. Certain changes occur in the breasts during pregnancy. They are prepared for future lactation, the secretion of milk. A drop of this secretion (colostrum) can be expressed from the nipple during pregnancy. Colostrum reacts alkaline, and contains proteins, fats, epithelial cells (of the glandular vesicles and the lactiferous ducts) and leucocytes containing fat droplets (Fig. 144, *a*).

Breast milk appears in two or three days after delivery. The breasts become engorged, and tender. The puerpera complains of pain in the breasts which irradiates into the armpit, where sensitive nodes can be palpated.

The milk is secreted through complicated reflectory and hormonal effects and is controlled by the nervous system and the lactogenic hormone of the pituitary gland.

The mammary glands possibly secrete substances that intensify contractility of the uterus and promote its involution in the puerperium. The uterus also contracts due to stimulation of the nerve elements of the nipple during nursing. The reflex contractions of the uterus are often felt by the feeding mothers as sensible contractions.

Breast milk is a white fluid (emulsion) in which minutest droplets of fat are suspended in serum (Fig. 144, *b*). The milk reacts alkaline and does not coagulate on boiling. Its composition is 87-88 per cent water, 1.5-2 per cent proteins (casein and albumin), 3.5-4 per cent fats, 6.6-7.5 per cent sugar and 0.18-0.2 per cent salts.

The *general condition and the internal organs*. If the puerperium is normal, the general condition of the patient is good. During the first days of puerperium the woman sometimes feels intermittent pains in the external genitalia and the perineum. Sometimes she complains of painful contractions of the uterus, especially during breastfeeding. Her breath is even and deep, 14-16 respirations per min. The pulse is full and rhythmical, 70-75 beats per

min and sometimes slightly decelerated (physiological bradycardia). The arterial pressure is within normal limits or slightly lowered during the first days of the puerperium. The body temperature is normal during physiological puerperium. The course of the puerperium would be usually characterized by the body temperature and the pulse rate. Accelerated pulse (90 beats and over) and occasional elevation of body temperature over 37°C indicate complications, usually puerperal infections.

The puerperas tend to excess perspiration, especially if they drink much.

The metabolism of the woman during the first weeks of her puerperium is intensified but later it normalizes. The body weight decreases during the first days but later it is regained, usually due to deposition of fats.

Urination. The renal function is normal during the puerperium but voiding is often difficult due to disordered function of the urinary bladder. It is often manifested by the absence of the desire to void even with the full bladder. Sometimes urination is associated with pain and this interferes with normal function, though the woman may feel the desire to void. The disordered urination may depend on the atony of the bladder or on the oedema of its mucosa caused by compression of the bladder by the foetal head. Painful urination is often due to irritation of the damaged or eraded surfaces of the external genitalia and the perineum by the urine.

Urine retention in some women is often due to their inability to void in the supine position.

Intestinal function. Constipation is a frequent complication of the puerperium which mainly depends on the intestinal atony. The relaxation of the prelum and the resting posture in bed are the main causes of the intestinal atony.

Haemorrhoids often develop in the puerpera but they do not cause much discomfort. When incarcerated, the haemorrhoids become larger and painful, especially during defaecation.

Conduct of the Puerperium

If the puerperium is normal the woman can be considered healthy. But she requires special care which would facilitate normal involution of her reproductive organs, healing of the wound surfaces, and normalizing of the bodily functions.

Observation of aseptic and antiseptic regulations is the prime requisite in organization of proper care of the puerpera. The wound surface of the uterus, minor fissures, and lacerations of soft tissues may become the site of entrance of infection. Infection of the birth canal is fraught with a real danger of the development of puerperal sepsis. Infection of fissures on the nipples is also dangerous: mastitis is another possible complication of the puerperium.

Cleanliness of the recovery room, its furniture and the linen is therefore a very important condition of the puerperium. All tools, materials and other objects that might be used by the puerpera or come in contact with her genitalia or breasts must be sterile. The personnel taking care of the puerpera should obligatory wash and disinfect their hands and put on masks before giving the necessary care to the puerpera. The personnel should adhere to all requirements of personal hygiene.

The normal course of the puerperium depends on the resting conditions of the puerpera. She should be given all possibility for normal sleep, guarded

against undue concern or emotional upsets. Adequate nutrition is also very important. Regulation of the renal and intestinal function, and activation of movements are important for normal recovery of the woman.

Recovery room. The ward where the puerpera is kept after childbirth should be light and spacious. (Fig. 145, *a*). A floor area of at least 7.5 square metres should be allotted to each puerpera. The room should be washed at least twice a day and aired at regular intervals. In 7-10 days after the discharge of the patients the room should be cleaned thoroughly (the walls, the floor and the furniture should be thoroughly washed and disinfected). The bed and oil-cloths should be washed and disinfected as well, while the mattresses, pillows and blankets should be exposed to the sunrays and aired for at least 24 hours. All linen and other bed articles should be disinfected after discharge of patients with puerperal fever.

From the delivery room the puerpera is moved to the recovery room and placed into a clean bed. The bed is made as follows: the mattress is covered with a linen and an oil-cloth is placed above it to cover the middle third of the bed. Another linen (1×1 m) is placed on top the oil-cloth (it is to be renewed at least two times a day). Other bed articles and underwear should be changed whenever necessary. Used bed linen should be boiled thoroughly and pressed with a hot iron.

A separate (sterile) bedpan should be given to each puerpera. After use, the bedpan should be washed with water and disinfected with chloramine or lysoform.

The puerpera should be given a thorough care: (a) her subjective condition should be checked (appetite, disposition, sleep); (b) pulse and temperature should be taken at least two times a day; (c) the degree of engorgement of the breasts should be checked and the nipples inspected for the absence of fissures, painfulness, etc.; (d) consistency of the uterus and the level of its fundus are determined, and the absence of painfulness in palpation checked; (e) the external genitalia are inspected and the character and amount of lochia determined; (f) the function of the bladder and the intestine is checked. All findings should be put into the delivery and bedside record.

If painful postpartum contractions are felt by the woman, the following drugs are prescribed: pyramidon, acetylsalicylic acid, antipyrine, phenacetin (0.3-0.5 g). If the pain is strong, sedative suppository can be given (with pantopon, belladonna extract, etc.).

In physiological course of the puerperium and regular breast-feeding, the involution of the uterus is normal and no special medicines are required to stimulate its contraction. If the involution of the uterus is slow (subinvolution) the following medicines are prescribed: pregnantol, 0.02 g 2-3 times a day, ergotal, 0.001 g 2-3 times a day, ergometrine 0.0002 g 2-3 times a day, cotarnine chloride (stypticin), 0.05 g 2-3 times a day, and pituitrin injections, 1 ml, 1-2 times a day.

Timely evacuation of the bladder and the bowels promotes normal involution of the uterus.

If urination is difficult, a preliminarily warmed up bedpan is placed beneath the pelvis of the puerpera. A hot water-bag can be placed on the urinary bladder for 15-20 minutes. To facilitate urination of the patient, a reflex method can be used: a jet of water should be poured down from the tap or a bottle. Pituitrin (1 ml, 1-2

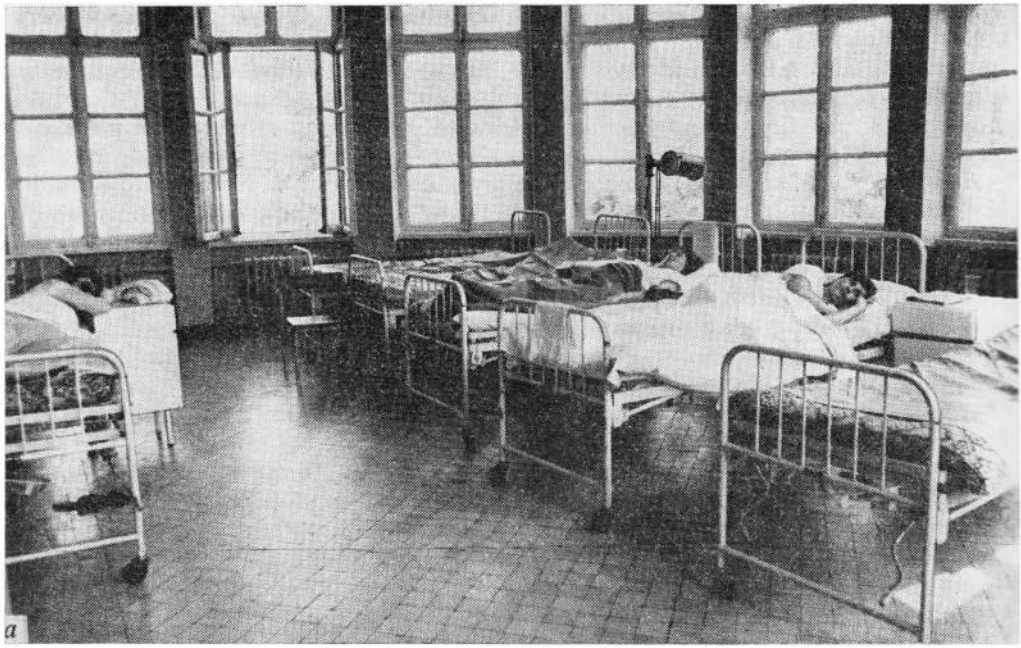

Fig. 145. *a* — a puerperal ward; *b* — a wheeled table for the puerperal toilet



times a day) and magnesium sulphate injections (5-6 ml of a 25% solution, intramuscularly) are effective for the purpose.

If these means do not help, the bladder should be catheterized with observation of the aseptic and antiseptic rules (sterilization of the catheter by boiling, washing hands and treatment of the periurethral area by a weak disinfectant solution). After emptying the bladder by catheterization, hexamethylenetetramine (0.5 g, three times a day) or common mullein decoction (Dec. foliorum Uvae ursi, 10.0:200.0, one tablespoonful, four or five times a day) should be prescribed.

A cleansing enema or a cathartic (sodium sulphate or magnesium sulphate, 10-20 g) should be given to the puerpera if the bowels are not evacuated for more than three days after delivery.

If large and painful haemorrhoids develop, an ice bag should be placed on the perineal region (the bag should be wrapped in a sterile napkin), or suppositories with belladonna or pantopon given. If this does not help, the haemorrhoids should be repositioned by a gloved finger coated with vaseline.

If the puerperium is normal and the perineum is not lacerated, the puerpera is allowed to sit on the second day and to walk on the third day after delivery. If the perineum is lacerated, the woman can turn to her sides and move in the bed. She is allowed to walk only after the ligatures have been removed (on the sixth day), and the healing process is in the stage of primary intension.

At many obstetrical establishments they recommend that the puerpera should rise from her bed on the second day after childbirth.

Nutrition. The normal puerpera needs no special diet. High-calory and readily assimilable food, such as bread, pastry, cream, semolina, sweet tea and coffee, etc. should be given in early puerperium. Beginning with the third day, the diet should be normal. Fresh berries, fruits, vegetables and other food products rich in vitamins should be given. Vitamins C, B, D, A are recommended. In the winter time (in areas where fresh fruits and vegetables are not available) they could be given as preparations. The puerpera should abstain from piquant and canned food, smoked sausages and fatty meat, peas, etc. Alcoholic drinks are prohibited.

The medical personnel should check the quality of food cooked at the lying-in hospital and also the food brought to the puerpera by her relatives. The puerpera should abstain from overeating.

Postpartum Care. The main object of postpartum care of the puerpera is to protect her from infection and to provide conditions for the normal functioning of the female body. Cleanliness is an especially important factor. The puerpera should obligatory cleanse her teeth and wash her face with warm water and soap at least two times a day, comb her hair, cover it with a kerchief and change her underwear. She should wash her hands also before breast-feeding and taking food.

Special care should be taken of the external genitalia. Lochia discharged from the vagina soils the external genitalia and the perineum, and provides conditions for the multiplication of bacteria. The external genitalia of the woman should therefore be washed at least two times a day with observation of the aseptic and antiseptic regulations.

The *genitalia should be washed as follows*: first the forceps should be

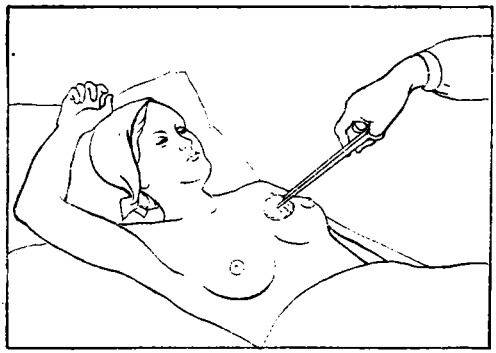

Fig. 146. Toilet of the breasts

sterilized. (Each puerpera should be treated with separate tools, and they should therefore be available in the necessary quantity.) Next a warm weak disinfectant solution is prepared (1:4000 -1:6000 solution of potassium permanganate or 0.25-0.5 per cent lysol solution).

Sterile tools, cotton wool, alcohol and iodine tincture are kept on a wheeled table (Fig. 145, *b*). The obstetrician washes her hands, puts on a mask, sterile gloves and then washes the genitalia of the puerpera. The nurse moves the wheeled table from one puerpera to another, handles the bedpans, pours the disinfectant solution over the genitalia from a jar or an Esmarch's irrigator. *Cotton wool* should be used to aid washing. A bedpan should be put beneath the pelvis of the puerpera and the latter suggested to abduct her legs. A jet of the disinfectant solution is poured from the vessel and the genitals are washed (first the genitalia proper, then the perineum, and finally the inner thighs and the anus are washed). The washed surfaces are then dried up by sterile cotton wool or gauze. The overlying bed-sheet should be renewed after each wash.

The genitals should be washed in the same way after defaecation.

If the perineum is lacerated, the genitals should be washed very carefully, without touching the sutures which should be kept dry. To that end the sutures should be covered by sterile pads which should be renewed at least 4-5 times a day. The ligatures should be removed in six days after delivery.

Vaginal irrigations are contraindicated in the puerperium.

The puerpera with elevated temperature, catarrh of the upper respiratory ways, pyodermitis and other signs of infection should be isolated from healthy puerpera in the second department or in a special ward, if the obstetrical institution is small. Hygienic treatment to these women should only be given after healthy puerperas are given the necessary care.

Timely isolation of infected puerpera is very important for the prevention of morbidity among other puerperas and their infants.

The *breasts of the puerpera* require special care as well. They should be kept clean. It is recommended to wash them with a 0.5 per cent solution of ammonia or warm water and soap in the morning and in the evening (after feeding). The nipple is washed first, and then the rest of the breast. Sterile cotton wool or gauze should be used to dry up the breasts (Fig. 146). In order to prevent excessive engorgement of the breasts, the women are recommended to wear a well fitted bra. If engorgement is significant, the intake of liquid should be limited and a purgative (20-30 g of magnesium sulphate) should be prescribed. If the breasts are not emptied from milk during nursing the remaining milk should be abstracted from the breasts by hands or using a breast pump.

Exercises in Early Puerperium

Special exercises aimed to increase the general tone of the body, to improve the circulation of blood, respiration, metabolism, and the function of the urinary bladder and the intestine are prescribed to healthy puerperas beginning with the second day post partum. The exercises accelerate the involution of the reproductive organs, and strengthen the muscles of the prelum and the pelvic floor. If the perineum is lacerated, respiratory exercises are mainly prescribed.

The exercises are prescribed by a physician or an obstetrician and the puerperas perform them under observation of the obstetrician or the nurse. Before performing each exercise, the obstetrician explains how to do it. It is necessary that each exercise be coordinated with respiration. The condition of the puerpera should be carefully watched during exercises: her pulse and respiration rate should be controlled. If the accelerated pulse persists or dyspnoea develops, the exercises should be suspended. If the puerpera feels tired, the number of exercises should be reduced, and easier exercises should be substituted for heavier ones. If the bodily temperature rises, the exercises should be stopped.

The exercises should be done in the morning before routine medical examination, not earlier than thirty minutes after breakfast. The room where the puerperas will perform their exercises should first be aired well. During warm seasons, the exercises should be done with the windows open.

The exercises should be done in bed. The puerpera should take off her underwear (except the bra), while the genitalia and the pelvis should be covered with a small sheet (to simulate shorts). If the prelum is markedly flaccid, the abdomen should be bandaged before the exercises. If the puerpera is allowed to leave her bed, she should have a warm sponge bath after the exercises with subsequent drying up the body thoroughly with a towel.

Exercises* (Fig. 147)

The 1st Set of Exercises (the 2nd day after delivery)

Exercise 1. The *initial positions*: supine.** *Performance*: *** 1-2—raise the arms slightly and move them aside (inspiration); 3-4—return to the initial position (expiration).

Exercise 2. The *initial position*: supine. *Performance*: 1—set the arms aside to the level of the shoulders and simultaneously separate the fingers (inspiration); 2—flex the fingers into fists and bring the arms on the chest (expiration).

Exercise 3. The *initial position*: supine. *Performance*: take a breath; 1—extend the right hand to reach the opposite side of the bed (expiration) (turn the upper part of the body slightly during this exercise): 2—return to the initial position (inspiration); 3—extend the left hand (and turn the body slightly) to reach the opposite side of the bed (expiration); 4—return to the initial position (inspiration).

Exercise 4. The *initial position*: supine. *Performance*: 1—separate the fingers and diverge the feet simultaneously: 2—clinch the fists and converge the feet simultaneously. Breathe evenly.

Exercise 5. The initial position: supine. *Performance*: 1-2—turn to the side; 3-4—rest in this position; 5-6—return to the initial position. Breathe evenly.

---

* The exercises have been suggested by A. V. Bartels and N. E. Granat (The Institute of Obstetrics and Gynaecology, USSR).

** The initial (supine) position; the woman lies on her back with the arms at her sides, the palms down; the legs are extended as well, the feet held together; the head is held straight.

*** The figures are actually counts for various movements in the exercises.

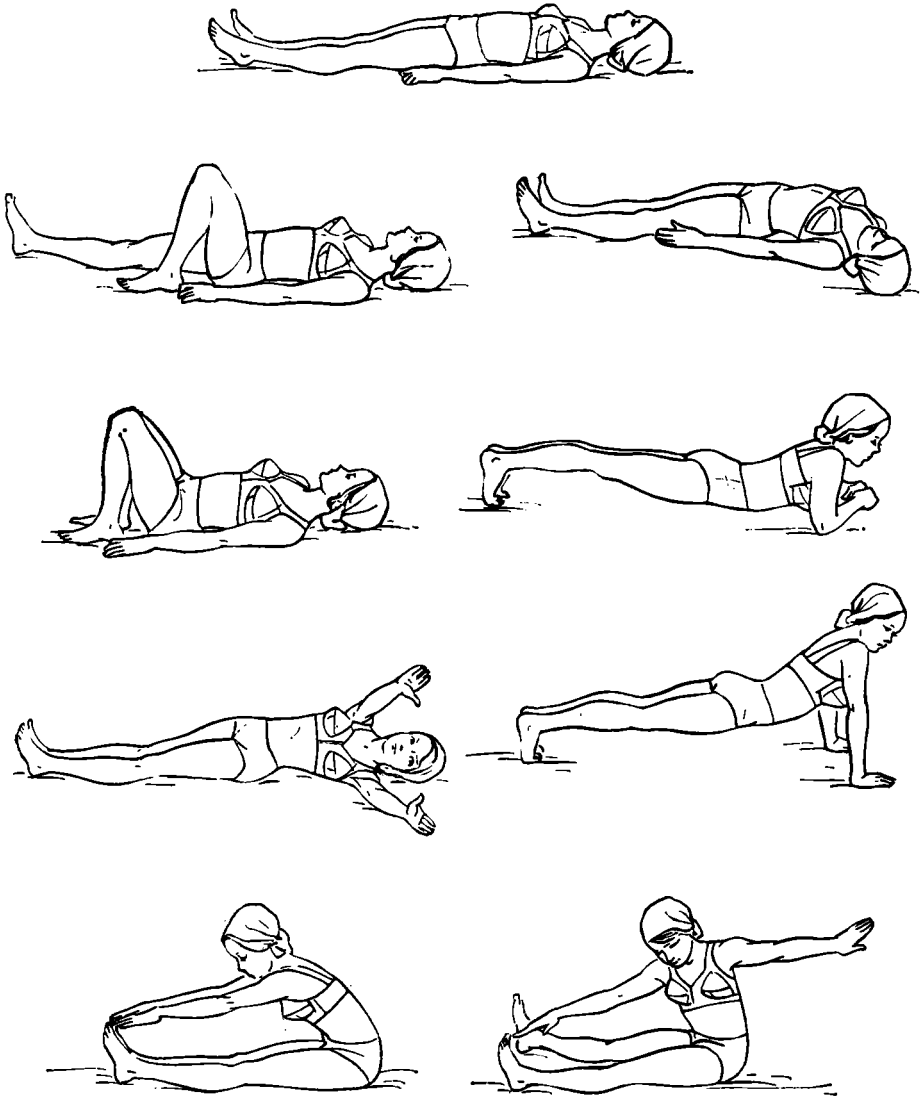

Fig. 147. Postpartum exercises:
1 — initial position; *2* — Set 1, exercise 7; *3* — Set 2, exercise 2; *4* — Set 2, exercise 7; *5* — Set 3, exercise 4; *6* — Set 4, exercise 2; *7* — Set 5, exercise 4; *8* — Set 6, exercise 5; *9* — Set 7, exercise 8

Exercise 6. The *initial position*: supine. *Performance*: 1—pull the anus in and contract the sphincter (inspiration); 2—relax the anus (expiration).

Exercise 7. The *initial position*: supine. *Performance*: 1-2—flex the left leg without raising the foot from the bed (inspiration); 3-4—deflex the leg (expiration); 5-6—flex

the right leg (inspiration); 7-8—deflex the leg (expiration).

Exercise 8. Perform exercise 1.

Notes: 1. Exercises 1, 2, 4 and 6 should be done 3-4 times; exercise 3 should be done 2-3 times and exercise 5 only once.

2. Women operated for lacerated perineum should perform exercises 1,2, 3 and 4.

The 2nd Set of Exercises (the 3rd day after delivery)

Exercise 1. Repeat exercise 2 of Set 1.

Exercise 2. The *initial position*: supine, with the hands at the sides. *Performance*: 1—bend the body to the left side and raise the right arm, the palm sliding along the side to the armpit; lower the left hand, sliding along the leg: bend the head to the left (inspiration); 2—return to the initial position (expiration); 3—bend the body to the right, with the left hand sliding to the armpit and the right hand down the leg; bend the head to the right (inspiration); 4—return to the initial position (expiration).

Exercise 3. Repeat exercise 4, Set 1.

Exercise 4. The *initial position*: supine. *Performance*: 1-2—turn onto the abdomen; 3-4—lie in the prone position (on the abdomen); 5-6—return to the initial position; breathe evenly.

Exercise 5. The *initial position*: supine, with the legs flexed, the arms at the sides, the palms down. *Performance*: 1—raise the pelvis, resting on the feet and the arms (inspiration); 2—return to the initial position (expiration).

Exercise 6. Repeat exercise 6 of Set 1.

Exercise 7. The *initial position*: supine. *Performance*: 1—flex the legs without lifting the feet from the bed (inspiration); 2—deflex the legs (expiration).

Exercise 8. Do exercise 1 of this Set.

Notes: 1. Do exercises 1, 3, 5, 6, 7 and 8 from 3 to 4 times.

2. Do exercise 2 2-3 times, and exercise 4 only once.

3. Women operated for lacerated perineum should do exercises 1, 2, 3, and also exercise 5 of Set 1.

The 3rd Set of Exercises (the 4th day)

Exercise 1. Repeat exercise 2 of Set 1.

Exercise 2. Repeat exercise 2 of Set 2.

Exercise 3. The *initial position*: supine. *Performance*: 1—diverge the feet and separate the fingers (inspiration); 2—put the feet together and clench the fingers into fists (expiration).

Exercise 4. The *initial position*: prone, with the arms flexed and raised to the shoulder level, one hand upon the other, the chin resting upon the hands. *Performance*: 1—resting against the elbows and the toes, raise the body and the head, slightly bending the back (inspiration); 2—return to the initial position (expiration).

Exercise 5. The *initial position*: supine, with the legs flexed, the arms at the sides, the palms down. *Performance*: 1—raise the pelvis resting against the feet and the arms. Tense simultaneously the anus muscles (inspiration); 2—lower the pelvis, and relax the anus muscles (expiration).

Exercise 6. The *initial position*: supine. *Performance*: 1—move the right hand aside and turn the head to the left (inspiration); 2—return to the initial position (expiration); 3—move the left hand aside and turn the head to the right (inspiration); 4—return to the initial position (expiration).

Exercise 7. The *initial position*: supine. *Performance*: 1—flex the left leg, the foot sliding by the inner surface of the right leg (inspiration); 2—deflex the left leg, the foot sliding back (expiration); 3—flex the right leg, the foot sliding by the inner surface of the left leg (inspiration); 4—deflex the right leg, the foot sliding back by the left leg (expiration).

Exercise 8. The *initial position*: sitting in bed with the hands joined at the occiput. *Performance*: 1—turn the upper part of the body to the right; 2—return to the initial position; 3—turn the upper part of the body to the left; 4—return to the initial position.

Exercise 9. Repeat exercise 1 of Set 3.

Notes: 1. Exercises 1, 3, 4, 5, 8 and 9 should be done 3-4 times; exercises 2, 6, and 7, 2-3 times.

2. Women operated for lacerated perineum should perform exercises 1, 2, 3 and 5 of Set 1.

The 4th Set of Exercises (the 5th day)

Exercise 1. The *initial position*: supine. *Performance*: 1—raise the arms up, join them above the head (inspiration); 2—lower the arms and return to the initial position (expiration).

Exercise 2. The *initial position*: supine, with the arms set apart, the palms upward.

Performance: take a breath before the exercise; 1—touch the palm of the right hand with the palm of the left hand, turning the upper part of the body to the left (expiration); 2—return to the initial position (inspiration); 3—touch the palm of the left hand with the palm of the right hand, turning the body to the right (expiration); 4—return to the initial position (inspiration).

Exercise 3. Repeat exercise 3 of Set 3.

Exercise 4. Repeat exercise 4 of Set 3.

Exercise 5. Repeat exercise 5 of Set 3.

Exercise 6. The *initial position*: supine, the arms at the sides; the legs extended. *Performance*: 1—abduct the legs and simultaneously move the arms aside to the level of the shoulders (inspiration); 2—return to the initial position (expiration).

Exercise 7. The *initial position*: supine. *Performance*: 1—raise an extended left leg; 2—lower it. Breathe evenly.

Exercise 8. The *initial position*: sitting in bed, with the legs hanging to the floor; the hands are joined at the occiput. *Performance*: take a breath; 1—bend forward (expiration); 2—unbend (inspiration).

Exercise 9. Repeat exercise 1 of Set 4.

Notes: 1. Exercises 1, 3, 4, 5, 6, 8 and 9 should be done 3-4 times; exercises 2 and 7 should be done 2 or 3 times.

2. Women operated for lacerated perineum should perform exercises 1, 2 and 3, and exercise 10 described below.

Exercise 10. The *initial position*: supine. *Performance*: 1—lift the pelvis (inspiration); 2—return to the initial position (expiration).

The 5th Set of Exercises (the 6th day)

Exercise 1. Repeat exercise 1 of Set 4.

Exercise 2. The *initial position*: supine. *Performance*: 1—turn the palms, separate the fingers, set the feet apart and flex them (inspiration); 2—return to the initial position (expiration).

Exercise 3. The *initial position*: prone; the arms flexed at the elbows, the palms down, the legs extended. *Performance*: 1—raise the head and the body, resting against the palms and toes (inspiration); 2—return to the initial position (expiration).

Exercise 4. Repeat exercise 5 of Set 3.

Exercise 5. Repeat exercise 6 of Set 4.

Exercise 6. The *initial position*: supine. *Performance*: 1—sit up and move the arms aside (inspiration); 2—bend to reach the toes with the fingers (expiration); 3—straighten the body and set the arms aside (inspiration); 4—return to the initial position (expiration).

Exercise 7. Do exercise 1 of Set 5.

Notes: 1. Exercises 1, 3, 4, 5, 6 should be done 3-4 times, and exercise 2—2-3 times.

2. Women operated for lacerated perineum should perform exercises 1, 2, 3 of Set 5 and exercise 10 of Set 4.

The 6th Set of Exercises (the 7th day)

Exercise 1. The *initial position*: supine. *Performance*: 1—move the arms aside and join them at the occiput (inspiration); 2—return to the initial position (expiration).

Exercise 2. The *initial position*: supine. *Performance*: take a breath; 1—reach the knee of the extended left leg by the right hand, resting against the left elbow, slightly raising and turning the upper part of the body (expiration); 2—return to the initial position (inspiration); 3—reach the knee of the extended right leg with the left hand, resting against the right elbow (expiration); 4—return to the initial position (inspiration).

Exercise 3. Repeat exercise 3 of Set 5.

Exercise 4. Repeat exercise 4 of Set 5.

Exercise 5. Repeat exercise 5 of Set 3.

Exercise 6. The *initial position*: supine. *Performance*: 1—flex the legs and raise the arms (inspiration); 2—return to the initial position (expiration).

Exercise 7. The *initial position*: supine. *Performance*: 1—raise the stretched legs slightly; 2—set the legs apart; 3—join the legs; 4—lower the legs. Breathe evenly.

Exercise 8. Repeat exercise 8 of Set 5.

Exercise 9. Repeat exercise 1 of Set 6.

Notes: 1. Exercises 1, 3, 4, 5, 6 and 9 should be done 3-4 times; exercises 2, 7, 8, 2-3 times.

2. Women operated for lacerated perineum should do exercises 1, 2, 3, 5 of this Set and exercise 4 of Set 3.

The 7th Set of Exercises (the 8th day)

Exercise 1. Repeat exercise 1 of Set 6.

Exercise 2. Repeat exercise 2 of Set 6.

Exercise 3. Repeat exercise 3 of Set 5.

Exercise 4. Repeat exercise 4 of Set 5.

Exercise 5. Repeat exercise 5 of Set 3,

Exercise 6. The *initial position*: supine, the arms at the sides. *Performance*: 1—flex the legs and set them apart, set the arms apart simultaneously (with the palms up) to the level of the shoulders (inspiration); 2—return to the initial position (expiration).

Exercise 7. The *initial position*: supine.

Performance: 1—flex the left leg on the thigh and the thigh on the abdomen, the right leg remaining extended; 2—now bend the right leg in both joints, and extend the left leg simultaneously. Breathe evenly.

Exercise 8. The *initial position*: sitting in bed, move the arms aside and raise them to the level of the shoulders, with the palms down. *Performance*: take a breath; 1—reach the toes of the left leg by the fingers of the right hand, bending slightly the body and turning to the left, with the left hand remaining at the level of the shoulder (expiration); 2—return to the initial position (inspiration); 3—reach the toes of the right foot by the fingers of the left hand, bending the body and turning it to the right, the right arm remaining at the level of the shoulders (expiration).

Exercise 9. Perform exercise 1 of this Set.

Notes: Exercises 1, 3, 4, 5, 6, 7 and 9 should be done 3-4 times; exercise 2 and 8, 2-3 times.

2. Women operated for lacerated perineum should do exercises 1, 2, 3, 4 and 5.

This Set of exercises can be performed on the 9th day after delivery.

Recommended schedule

6 a.m. waking up.
6-6.40 a.m. washing, taking temperature, airing rooms.
6.40-7 a.m. breast-feeding.
7-8.30 a.m. morning toilet, airing rooms, prescribed procedures.
8.30-9 a.m. breakfast.
9-9.30 a.m. preparing for feeding neonates.
9.30-10 a.m. feeding neonates.
10 a.m.-1 p.m. routine medical examination; medical exercises, and procedures.
1-1.30 p.m. feeding neonates.
1.30-2.30 p.m. dinner; airing rooms.
2.30-4 p.m. afternoon sleep.
4-4.30 p.m. preparing for feeding.
4.30-5 p.m. feeding infants.
5-6.30 p.m. taking temperature, washing before night, airing rooms, prescribed procedures.
6.30-7 p.m. supper.
7-8 p.m. medical examination, preparing for feeding.
8-9 p.m. feeding infants and rest.
9-11 p.m. evening sleep.
11-11.30 p.m. preparing for feeding.
11.30-12 p.m. feeding infants.
12 p.m. night sleep.

If the puerperium is normal the woman is discharged from the lying-in hospital on the 7-8th day after delivery. Before discharging, the puerpera is given instructions how to take care of her infant and herself during the postpartum period. A warm shower is permitted to take on the day of discharge, and a bath 3-4 weeks post partum. Sexual intercourse is permitted only in 6-8 weeks after delivery.

The puerpera is given her bedside chart containing the labour, delivery, and puerperium records. The chart is to be given to her doctor at the district obstetric clinic. The information concerning the neonate is sent to the district paediatrist.

When the puerpera is discharged from the lying-in hospital she is given an official certificate for the legislative formalities.

All women are given a postpartum leave.

Chapter Twelve

CARE OF THE NEONATE

The bodily structure and function of a neonate strongly differ from those of older children and adults.

Many organs and systems of the neonate remain still underdeveloped in the early extrauterine life. This holds true for the central nervous system as well. Tissues of the neonate are rich in fluids, are underdeveloped functionally, are vulnerable to external effects. The thermoregulation of the body has not stabilized, in premature infants in particular. Neonates are therefore easily affected by temperature changes.

The neonate is easy to infect; especially it holds true for septic infection which may enter the infant body through the umbilicus, skin, nasopharynx, and the gastrointestinal tract.

The neonate cannot localize the infection at the site of its entrance and the microbes easily penetrate the blood and lymph systems and are carried through the entire body.

The postpartum period is the time during which the infant gets accommodated to the new (extrauterine) conditions of life. The adaptation is easy if the environmental conditions favour the newborn. Otherwise the adaptation mechanism is upset and the neonate can easily develop diseases.

When nursing the newborn and taking care of them it is necessary to remember that the neonate is vulnerable to infection, changes in temperature, and malnutrition.

Neonate Department

Special departments for neonates exist at large lying-in hospitals. These comprise wards for full-term mature neonates, premature neonates and those with labour injuries. Neonates with suspected infection should be kept in a separate ward, while those with diseases, at an isolation ward.

The second department (for patients with suspected infection) has the neonate ward of its own.

If the obstetrical establishment is small, a neonate ward should be available (instead of the department as at large institutions).

Special medical nurses should take care of the neonates.

In rural areas, where obstetrical institutions can accommodate only two or three patients at a time, the neonates are kept in the recovery room (separated by a screen). The obstetrician takes care of the neonates.

Neonates should be kept in spacious and well-lit and aired rooms (departments). A floor area of at least 2.5 square metres should be allotted to each crib.

The neonate room should be free from all extraneous objects (except those which are absolutely necessary for the care of neonates). All pieces of furniture and other objects in the neonate room should be easy to wash. The neonate room should contain the fol-

lowing: cribs, a balance, a swaddling table, a cabinet for tools, medicines and dressing materials, a cabinet for clean linen, a vat for used swaddles, a wash stand with hot and cold water taps, and a small writing table for keeping records.

The cribs should preferably be metallic, painted in light shades. A small mattress is placed upon the network; it is covered with an oil-cloth and a sheet atop. The pillow should be small. The neonate can do without it as well (Fig. 148).

Light swaddles and vests should be of soft white cotton fabric; warm swaddles and vests should be fustian, flannel or sort flannelette. The swaddles and vests should have no coarse seams or buttons. Blankets to be used in winter should be flannelette, while summer swaddles are cotton. Three vests, three shirts, twenty diapers (breechcloths), twenty light swaddles, ten warm swaddles, two blanket cases and one bedsheet are required for one neonate daily. The total amount of linen required for a neonate depends on the laundry conditions. As a rule, at least three sets of articles listed are required.

The ambient temperature in the room for mature infants should be 20-22° and for premature neonates, 22-24°C. Additional heaters should be installed during winter time. Measures to prevent overheating should be taken during summer. The room should be aired each time during feeding. The windows should be kept open in summer.

The neonate room should be kept absolutely clean. When the infant is brought to the mother for feeding, the neonate room should be washed. In addition to the repeated daily cleansing, the room should be disinfected regularly. Infants born on one day are placed into one room and discharged

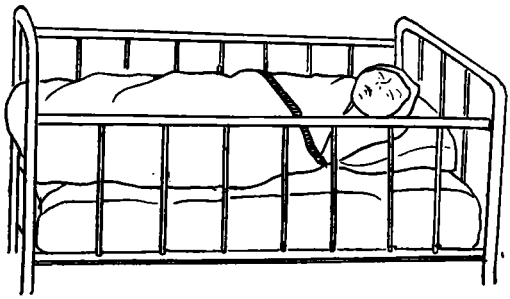

Fig. 148. A neonate in the crib

on the same day. Therefore, when the room is emptied, it is given the sanitary treatment: the room is aired for 24 hours, the furniture is washed thoroughly; mattresses and furniture are treated with a disinfectant solution. Thus treated room and furniture are then irradiated with a mercury-quartz lamp. The clean room is now ready to receive neonates from the delivery room.

Articles worn by the neonate require special cleanliness. They are washed separately from other articles, boiled thoroughly and pressed by a hot iron. Whenever possible, sterile swaddles and vests should be given to the neonates during their first days of life.

Glassware of the neonate department, soothers, tools, etc. should be boiled after each use.

The personnel of the neonate department should follow all rules of personal hygiene (see Chapter 7), paying special attention to cleanliness of the hands, overalls, hair, kerchieves and masks. The personnel should undergo regular medical examinations (X-ray and laboratory examinations included).

Infected personnel, or those who come in contact with infectious patients, or else carriers of bacilli should not be admitted to neonates.

Care of the Neonate at the Nursery

The care of the neonate should provide conditions favouring its development. The main principle underlying the care of the neonate is its protection from unfavourable effects of the environment, especially from possible infection.

Specially trained nurses are admitted to take care of the neonate. An obstetrician takes care of the neonate at small hospitals. Auxiliary personnel is not admitted to contact the neonate.

At the beginning of the shift, the medical personnel should obligatory wash their hands (to the elbows) using soap and a brush and then disinfect them (alcohol, lysoform, chloramine solutions, etc.). The nurse should wash her hands and disinfect them each time before swaddling the infant.

When the infant is brought into the neonate room from the delivery room, it is wrapped in warmed-up cloths, placed in bed and its condition is observed thoroughly. It should be remembered that a neonate may vomit or develop cyanosis; the umbilical stump may bleed.

Fig. 149. Toilet of a neonate

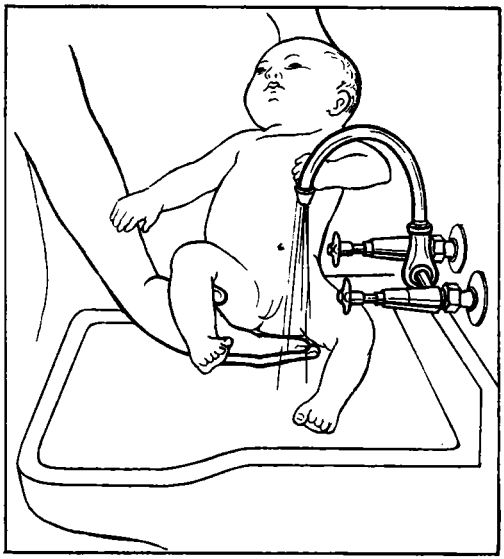

Two times a day (before the first feeding and in the evening) the neonate should be given a hygienic treatment. During this procedure the infant is given a general outer examination, all skin folds are inspected, the bandage on the umbilical stump is checked, and the prescribed procedures are done. The weight and temperature of the infant are also measured.

Proper care of the infant's skin is very important since abrasion and intertrigo may become the site of entrance of infection. Purulent diseases of the skin may become the cause of sepsis.

The body of the infant is inspected during the morning and evening toilet; special attention should be paid to the skin folds where intertrigo would most likely occur (behind the ears, on the neck, in the armpits and groins, etc.).

The infant should not take bath before the umbilical cord falls off since infection is likely to enter through the non-healed umbilical wound. The washing therefore consists only in wiping the face with a piece of cotton wool soaked in warm boiled water or a 2 per cent solution of boric acid. The ears, the skin behind the ears, the skin folds on the neck, the palms and soles should be wiped with a wet cotton wool pad. The body should then be dried up.

If any reddening appears on the skin, the affected sites should be coated with sterile vaseline or sunflower oil.

The neonate should be swaddled anew after each urination or defaecation (in

the intervals between nursing). Soiled swaddles are replaced by clean ones, while the lower part of the infant's body should be washed in a jet of warm water (Fig. 149). In doing so it is necessary to protect the umbilical region from wetting with water. The skin should then be dried up by touching (not rubbing!) it with a clean cloth readily absorbing moisture. For prophylactic purposes the skin of the buttocks and the groins should be coated with sterile oil.

Intertrigo would normally be the result of inadequate care of the neonate. Treatment of intertrigo includes improved care, prevention of the skin from soiling with faeces or urine. If intertrigo is insignificant (skin is only reddened) application of sterile oil would usually be enough. If the reddened skin is macerated, a 3 per cent solution of potassium permanganate should be used to treat the affected skin with subsequent powdering with the preparation of the following composition: boric acid 1.0 g, bismuth subnitrate, zinc oxide 5.0 g of each, talcum and starch (amylum), 50.0 g of each.

Prophylaxis of pyodermitis is especially important. If any purulent foci appear on the skin, the infant should be isolated from other neonates. Each pustule should be treated with an alcoholic solution of gramicidin (0.04 per cent), streptocide (1-2 per cent), or potassium permanganate (3 per cent). Penicillin is often prescribed intramuscularly. The neonate should be under constant medical observation.

Care of the organs of senses. The eyes of the neonate should be treated with cotton wool soaked in a 2 per cent solution of boric acid. Each eye is treated with a separate ball of cotton wool, moving it from the outer canthus of the eye to the inner one (Fig. 150).

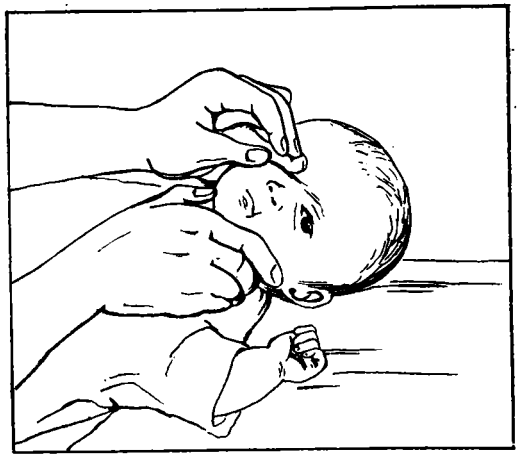

Fig. 150. Washing the eyes

Wiping the ears with wet cotton during the morning toilet will normally be enough; it is unnecessary to clean the meatus.

The nostrils should only be treated if the respiration is difficult and much mucus or crusts are accumulated in them. The openings are then wiped carefully with a piece of cotton wool twisted into a cord and soaked in vaseline oil.

It is prohibited to wipe the mouth mucosa since it can easily be damaged. Even in case of thrush (the result of inadequate care and feeding) the mucosa should not be wiped but only coated carefully with a 10 per cent solution of borax and glycerol.

Swaddling. In the first days after birth, the infant should be swaddled to the full (the head and the arms included), but later the arms and the head should remain free. Beginning with the 3rd or 4th day, the neonate should be dressed in a vest opening on its back and a warm shirt opening

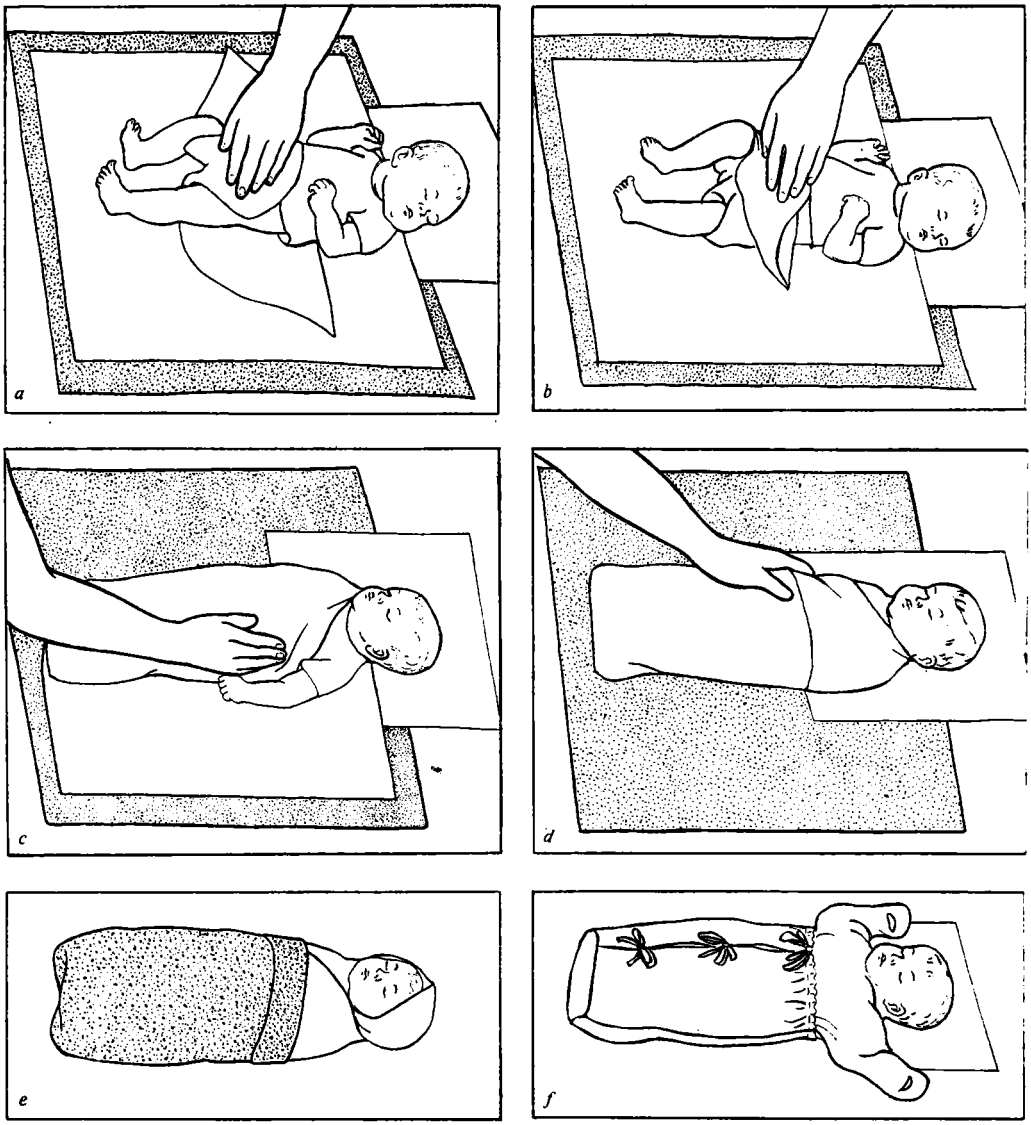

Fig. 151. Swaddling the neonate:
a — the first movement: the breechcloth angles are passed between the legs; *b* — the second movement: the breechcloth side angles are turned round the abdomen; *c* — the third movement: wrapping the infant in the swaddle; *d* — the fourth movement: the swaddled infant; *e* — swaddling is complete; *f* — the neonate in a vest

on the chest (both should be provided with laces of soft fabric). The sleeves of the shirt should be long and closed at their ends. The lower part of the body should be wrapped in a breechcloth and a swaddle.

The swaddling technique is as follows (Fig. 151, *a* through *e*). The infant is placed on a breechcloth lying over the swaddle. Underlying the swaddle is a blanket.

The breechcloth (diaper) is a square napkin folded into a triangle. The base of the triangle should align with the lumbar region of the neonate, lower ends of the breechcloth are passed between its legs, while the outer ends are wrapped around the infant's waste. The body of the neonate is then wrapped in a large and soft swaddle. Next the infant is wrapped in the warm swaddle and finally in the blanket. An oilcloth is placed between the first and the second swaddle. If swaddles are available in ample quantity, another swaddle (folded 6 or 8 times) can be used instead of the oilcloth. This is another preventive measure against intertrigo and skin diseases.

Breast-Feeding

Normal food of the neonate is its mother's milk. Only breast-feeding ensures normal development of the baby. Morbidity and mortality among neonates fed by the mother's milk is many times lower than those among artificially fed neonates.

The mother should be informed by the medical personnel of the importance of breast-feeding, and measures should be taken that each mother feed her infant by her milk.

This task is easy to solve since most women (from 80 to 90 per cent) are capable of feeding their infants, especially so during the first weeks and months of the infant's life. Successful breast-feeding largely depends on the observation of the rules for breast-feeding.

The baby should be given to nurse for the first time in 12 hours after its birth. Some paediatrists suggest that the first nursing should be in 6 to 8 hours after birth. (Premature infants should be nursed for the first time in 6 to 8 hours after birth.)

The usual schedule for feeding is 6-7 times during a day (at 3 to $3^1/_2$ hour-intervals) with an obligatory 6-hour interval during night.

The following measures should be taken to prevent infection of the neonate:

1. The mother should wear a mask to prevent possible droplet infection of her infant.
2. The mother should wash her hands with soap and water and wipe them with gauze soaked in 0.25-0.5 per cent ammonia solution before each feeding.
3. Before each feeding the nipples are cleansed by warm boiled water.

During nursing the infant should be placed on the mother's bed over a special napkin.

The feeding technique is an important factor. During the first days after birth, the mother feeds her infant in her bed, only slightly turning toward the baby lying by her side and holding it by her arm (Fig. 152). Beginning with the second or third day, the mother feeds her baby in the sitting position (Fig. 153). Later the mother can sit upon a chair or a stool, placing one leg on a bench and supporting the head and the back of the baby which lies in her laps (Fig. 154).

Before feeding the mother should express by hand a few drops of her milk

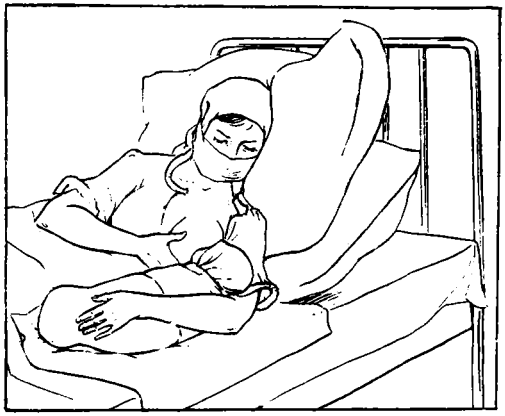

Fig. 152. Feeding the baby in bed

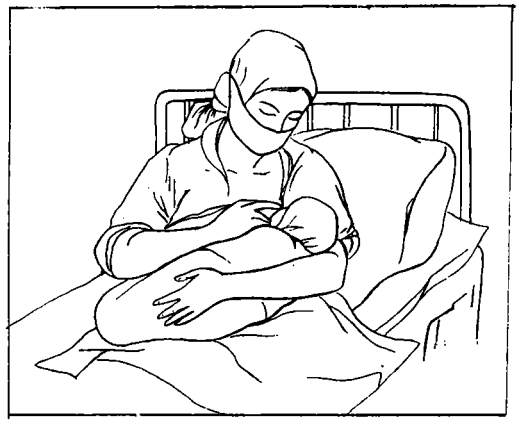

Fig. 153. Feeding the baby in the sitting position

Fig. 154. Feeding the baby by the mother after she is allowed to walk

to clear the clogged lactiferous canals. Next she takes hold of the nipple by the forefinger and the thumb and puts it (together with the areola) into the infant's mouth. When the baby takes the nipple together with the areola, nursing is easy and swallowing of the air by the infant is prevented. During feeding care should be taken that the nostrils should not be closed by the mother's breast thus interfering with

Fig. 155. Manual withdrawal of milk

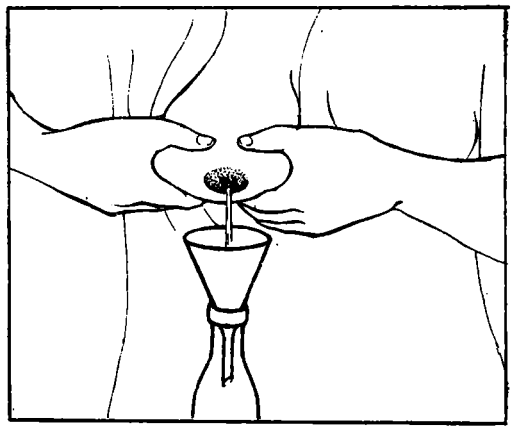

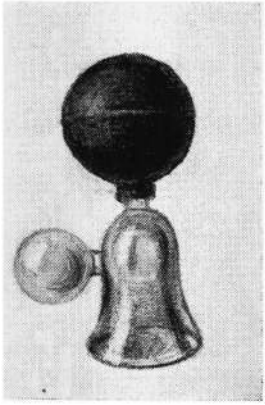

Fig. 156. Breast pump

Fig. 157. Glass adapter with a rubber nipple

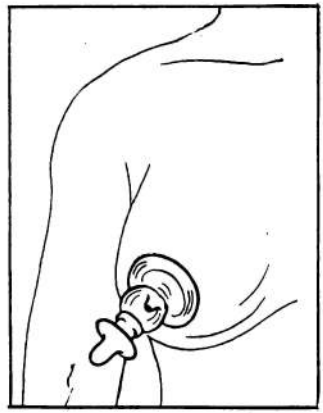

Fig. 158. Dyatlov's adapter

normal breathing of the baby. After feeding the mother should dry the nipple and put on a clean bra holding the breasts in the lifted position. If the skin of the breast is very soft, the nipple should be coated with sterile vaseline oil and covered with a piece of cotton wool or gauze.

The infant should be fed only at one breast during each feeding. Feeding at two breasts is only allowed during the first days post partum when the milk secretion is insufficient, or if the mother suffers from hypolactation.

It is customary to have the infant nurse 15-20 minutes. An adequately nursing baby sucks about 50 per cent of the required quantity within the first five minutes. The breast should be fully emptied of its milk. It has been established that incomplete withdrawal of milk from breasts during feeding decreases their secretory function.

The milk that remains in the breast after feeding should be removed manually (Fig. 155) or by a sterile breast pump (Fig. 156).

If the nipple is flat or inverted, or else if it has fissures, the baby should nurse through a glass adapter provided with a rubber nipple (Fig. 157). A breast pump and Dyatlov's adapter suit the purpose best (Fig. 158).

The growth of the neonate depends largely on the amount of milk obtained from its mother. The amount of milk in millilitres that the infant should obtain during each feeding in the first 8 or 9 days of its life is equal to the number of days of life multiplied by ten.

For example, during the second day of life the baby should obtain 20 ml of milk during each feeding; on the third day it is 30 ml, on the fifth day, 50 ml, etc. The daily milk demand of an infant during the first days of life can be calculated by the formula $X=(10\times n)7$ where X is the daily milk demand in millilitres, n is the number of days of the infant's life, and 7 is the average daily number of feedings.

If the baby obtains the required amount of milk, its condition is good, it sleeps well, and sucks actively. If any doubt arises, the baby should be

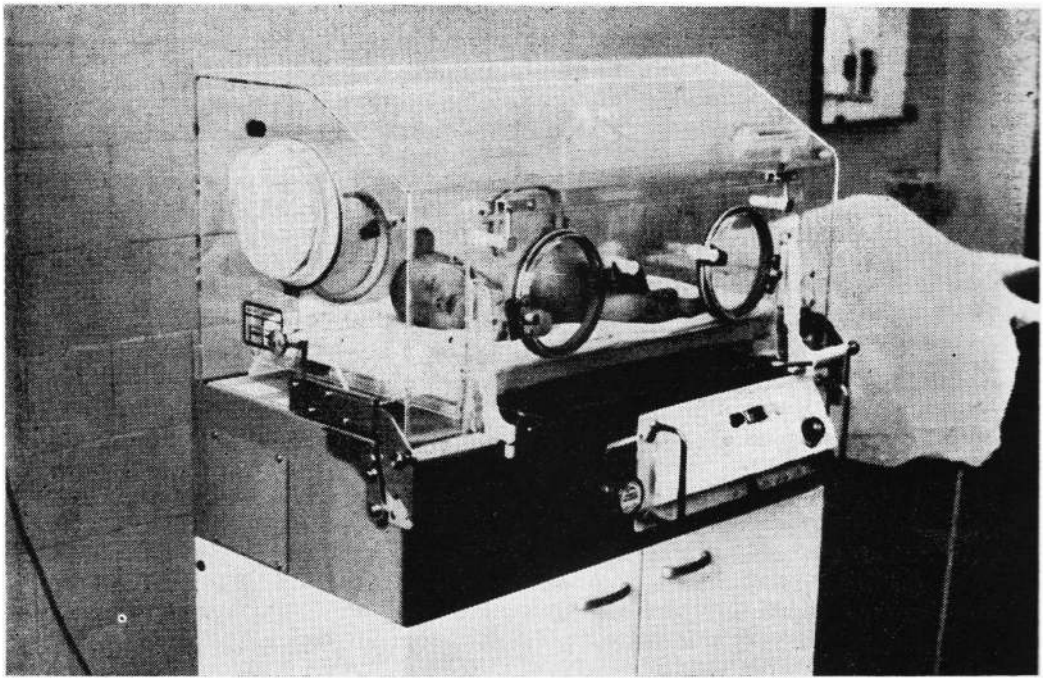

Fig. 159. Couveuse

weighed before and after feeding (the difference being the weight of milk obtained by the baby during feeding). Beginning with the first days of life the baby should be given from 30 to 50 ml of boiled water or tea daily. In the hot season this quantity should be increased to 100-120 ml.

The weight gain curve is a good indicator of growth and adequate nutrition of the infant. During the first 3 or 4 days the neonate loses from 100 to 300 g, which is 6-8 per cent of the initial weight. The loss is normal for a full-term neonate. Beginning with the 4th or 5th day of the infant's life its weight increases and by the day of discharge from the hospital the infant recovers the lost weight and even gains in weight.

Care of Premature Neonates

When determining the degree of dysmaturity, the anamnestic data, the objective findings of the obstetrical examination, and first of all the findings of examination of the neonate should be taken into account.

Premature neonates are inactive, sleepy, their cry is feeble, the respiration is superficial, often irregular, and the reflexes are not active. If the degree of dysmaturity is high, the sucking and swallowing reflexes are absent. Premature neonates have inadequate thermal regulation and the body temperature therefore lowers or rises with the lowering or rising ambient temperature.

The immunity is weak in premature

neonates and hence their susceptibility to infectious diseases (influenza, pneumonia, pyodermitis, sepsis).

Survival of premature neonates depends largely on the care and feeding. Premature newborns should be protected from cold. The first toilet of the newborn should be done very quickly on a warmed 'baby' table (heaters, warmed up swaddles) and then the infant should be wrapped in swaddles and a blanket under a lamp-heater. Further swaddling of the baby and its toilet should obligatory be done with additional heating.

Premature neonates should be kept in couveuse (Fig. 159) or in ordinary cribs provided with hot water-bags. Couveuse may be provided with automatic devices that control the ambient temperature and air humidity.

If couveuse is not available, the premature neonates may be kept in common cribs with hot (60°C) water-bags placed around them. One water bag is placed at each side of the infant and one bag at the legs. It is unnecessary to place water-bags under the neonate. The water-bags should be renewed one after another (not at once).

Premature neonates are sensitive to elevated temperatures. When overheated, they become restless, the body temperature rises, the skin reddens and perspiration appears. The temperature of water in the bags or in couveuse should then be lowered. Neonates of small weight can be wrapped in cotton wool.

Premature neonates should be carefully protected against infection. Keeping them in a separate room facilitates this task. If the obstetric institution is small and it is impossible to keep premature neonates in a separate room, they should be kept in the nursery behind a glass screen. Rules of asepsis and antisepsis should be observed especially thoroughly by those who take care of premature neonates.

It is especially important that a premature neonate should be fed with breast milk (better its mother's milk). The feeding technique depends on the degree of immaturity, the general condition, and on the sucking and swallowing reflexes of the baby. The premature neonate should be fed for the first time in 4-6 hours after birth. The feeding schedule depends on specific characteristics of the infant. A. F. Tur recommends that the infant should be fed from 7 to 8 times a day if it weighs from 2000 to 2500 grams, from 8 to 10 times if the infant weighs from 1500 to 2000 grams and from 10 to 14 times if the infant weighs from 1000 to 1500 grams.

If the baby sucks well, it can be nursed by its mother with observation of the appropriate rules. If the sucking reflex is weak and the baby soon becomes tired, breast-feeding should be alternated with bottle feeding (through a rubber soother). The infant then nurses at breasts once or twice a day. When the infant strengthens, breast-feeding may be more frequent, and the soother soon becomes unnecessary. If the infant does not nurse at the breast, or it does not take the soother, warmed breast milk can be given to it from a spoon in small portions. A small tea spoon or a spoon with a drawn end should be used for the purpose (Fig. 160). The infant should be given oxygen to breathe with before and after feeding. Asthenic infants should be fed from a pipette. The milk is dropped from the pipette on the upper lip near the nostrils (Fig. 161) and flows by gravity into the oesophagus through the nasopharynx.

Neonates who are unable to suck or

Fig. 160. A spoon for feeding the neonate

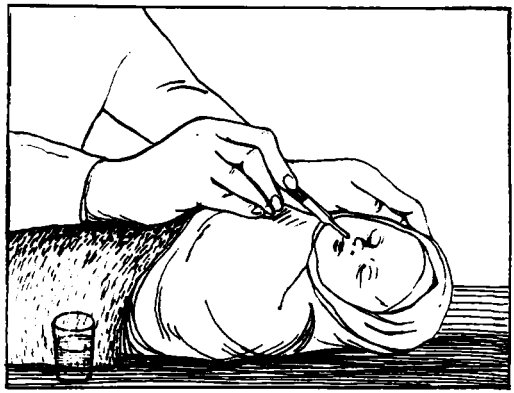

Fig. 161. Feeding through the nose by a pipette

Fig. 162. Feeding through a probe

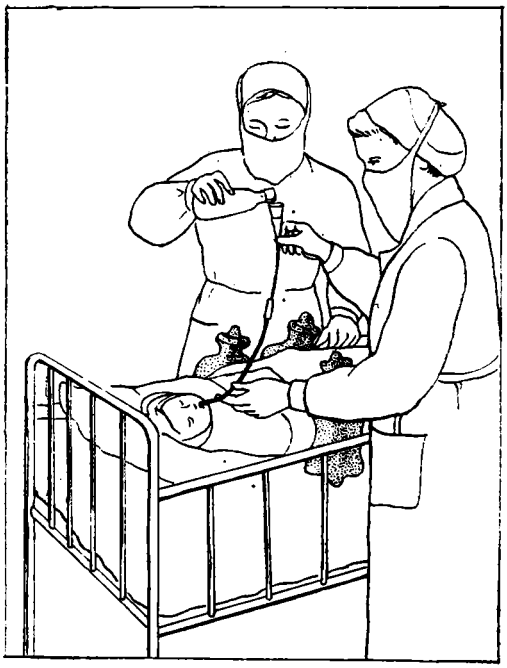

swallow are fed through a probe. An elastic catheter No. 13-15 should be used for the purpose. The catheter is connected by a rubber tube to a funnel and introduced into the oesophagus of the infant. (The tip of the probe should be coated with sterile vaseline oil and should freely pass the mouth.) Milk should be poured into the oesophagus in a continuous jet so that air would not get into the stomach (Fig. 162).

The temperature, weight, the condition of the skin and the organs of senses, the function of the intestine, the general condition and the conduct of the premature neonate should be observed thoroughly. Premature infants should be kept in the lying-in hospital for at least two weeks; if the degree of immaturity is high the infant may be kept in the hospital for longer periods of time.

When the mother is discharged from the hospital, she is given detailed instructions how to take care and feed her premature infant. The district paediatrist is duly informed of the prematurely born infant.

Asphyxia

Intrauterine asphyxia. The intrauterine foetus obtains the necessary oxygen from the maternal body through the placenta. If the transport of oxygen through the placenta is upset, the foetus develops asphyxia.

Asphyxia can be the result of diseases of the mother, complicated labour accompanied by disordered placental blood circulation and gas exchange of the foetus.

Asphyxia often develops in toxicosis of pregnancy (nephropathy, eclampsia), hypertension, grave diseases of the heart and the lungs, acute anaemia,

and diseases accompanied with fever. Asphyxia can be the result of prolonged labour after the loss of the amniotic fluid, placental separation, compression of the umbilical cord, its entanglements and knots around the foetal neck or the body. The incidence of asphyxia is more frequent in breech presentation when compression of the umbilical cord is more likely to occur. Insufficient amount of oxygen is delivered to the foetus in convulsive contractions of the uterus.

Asphyxia may develop due to disorders in the cerebral blood circulation which results from prolonged pressure of the birth canal on the foetal head. It is especially significant in cephalopelvic disproportion. Asphyxia may develop by reflectory pathways, e.g. in external version of the foetus.

Asphyxia of the foetus involves disorders in the blood circulation which can cause multiple haemorrhage. Asphyxia is the main cause of intracranial haemorrhage.

Disordered heart function of the foetus is the most vivid and persistent manifestation of the developing intrauterine asphyxia. The symptoms are as follows: (a) the heart rate is accelerated to 160 beats per min and above (the normal heart rate is 120-140 beats); (b) the heart rate drops to 110-100 beats per min and does not normalize in the pauses between uterine and abdominal contractions; (c) upset cardiac rhythm; (d) the foetal heart tones become dull.

The developing asphyxia is manifested by staining of the amniotic fluid with meconium in vertex presentation (in breech presentation meconium is expressed mechanically and its presence in the amniotic fluid cannot be regarded as the sign of asphyxia). The developing asphyxia is often accompanied by intense movements of the foetus. These two signs (appearance of meconium and intense movements of the foetus) are however often absent in quite obvious cases of asphyxia.

A persistent and most vivid sign of asphyxia is the upset cardiac function. Foetal heart tones should therefore be constantly listened to to detect developing asphyxia and take timely measures to remove it. Electrophonocardiography is an effective means to detect the disordered heart function associated with asphyxia.

When the first, though indistinct, signs of cardiac dysfunction appear, measures should immediately be taken to stop the developing asphyxia. If the mother has had the disease that can interfere with normal gas exchange in the foetus or if labour is complicated by some other causes, prophylactic measures should be taken to preclude possible asphyxia. V. N. Khmelevsky suggests that glucose with ascorbic acid and calcium chloride should be administered to prevent asphyxia of the foetus. The author recommends that 40-50 ml of 40 per cent solution of glucose with a 2 per cent ascorbic acid solution and 5-10 ml of a 10 per cent calcium chloride solution should be given intravenously in the beginning asphyxia. Moreover, to 100 g of glucose, 2 g of calcium chloride and 0.5 g of ascorbic acid, 30 mg of vitamin B_1 and 8 drops of dilute hydrochloric acid in half-glass of water should be prescribed per os.

According to A. P. Nikolaev the following 'triad' can control asphyxia: breathing with oxygen, intravenous injection of glucose and intramuscular administration of cardiazole (corazol). All these substances are transported to the foetus through the placenta. Glucose intensifies the oxidation processes,

decreases the oxygen demand of the brain, and maintains viability of the foetus in conditions of oxygen deficiency. Cardiazole excites the vasomotor centre of the foetus to remove disorders in the blood circulation. Oxygen inhaled by the mother passes to the foetal blood through the placenta and thus removes the developing asphyxia.

Prophylaxis of asphyxia consists in the following:

1. The parturient is given to breathe with oxygen for ten minutes at five-minute intervals until the improvement in the foetal heart tones becomes stable.
2. At the same time 50 ml of a 40 per cent glucose solution should be given intravenously. Glucose can be given per os (50 g of glucose dissolved in a glass of hot water).
3. Cardiazole (1 ml of a 10 per cent solution) should be injected intramuscularly.

The 'triad' can be repeated in an hour (or more).

If these measures prove ineffective, delivery should be accelerated to preclude foetal death from asphyxia. The method by which the woman is delivered depends on the conditions of each particular case.

Neonatal asphyxia. Asphyxia after birth is characterized by the absence of natural respiration or by irregular respiratory movements in a live born infant (the heart tones are heard).

Two forms of asphyxia are distinguished, viz., blue asphyxia and asphyxia pallida. The former is the light and the latter is the grave form of asphyxia. Blue asphyxia (asphyxia livida) is characterized by cyanotic skin and mucosa of the neonate, bradycardia, weak reflexes and satisfactory muscular tone. Asphyxia pallida is attended with paleness of the skin, cyanotic mucosa, weak pulse, abolition (or weakness) of reflexes, and muscular atony. Blue asphyxia can in most cases be removed while the death rate in asphyxia pallida is high. If the neonate survives, it often develops sequelae: intracranial bleeding evoking disorders

Evaluation of Newborn Infant (modified from Apgar)

Sign	Scoring		
	0	1	2
Heart rate	absent	slow (below 100 beats per min)	100-140 beats per min
Respiratory effort	absent	slow, irregular	good, crying
Reflex irritability	no response to irritation of soles	grimace or movements	motion, loud cry
Muscle tone	absent	decreased	active motion
Skin colour	pale or blue	body pink, extremities blue	completely pink

in the vital functions, pneumonia, atelectasis of the lungs, etc.

During the last years the status of the neonate at birth and the gravity of asphyxia are evaluated by the Apgar scoring system. The vital physical signs, such as the heart rate, respiration, reflexes, the muscular tone and the colour of the skin of a neonate are evaluated immediately after birth. The scoring principle is as follows: 2 is assigned for an optimum, 1 for an average and 0 for an absent response. A score of 10 to 7 is consistent with a healthy neonate. Light asphyxia scores 6-5, asphyxia of medium gravity 5, grave asphyxia 4 and below and the score is zero in clinical death.

Asphyxia is characterized not only by disordered respiration, blood circulation and other dysfunctions, but also by disordered metabolism. Cyanosis would usually develop.

Resuscitation of Infants Born in Asphyxia

Many methods have been proposed to revive neonates born in asphyxia. The following technique is practiced in most hospitals to control asphyxia.

1. The infant born in asphyxia is placed in a tub filled with warm (38-40°) boiled water; the tub is placed on the delivery bed between the abducted mother's legs (Fig. 163). The umbilical cord should not be cut since until it pulsates, oxygen is still transmitted to the foetus from the mother. During resuscitation the infant should always be kept warm. The method suggested by I. S. Legenchenko does not ensure a hundred percent success.

2. The upper airways of the infant should immediately be aspirated to remove mucus and amniotic fluid that

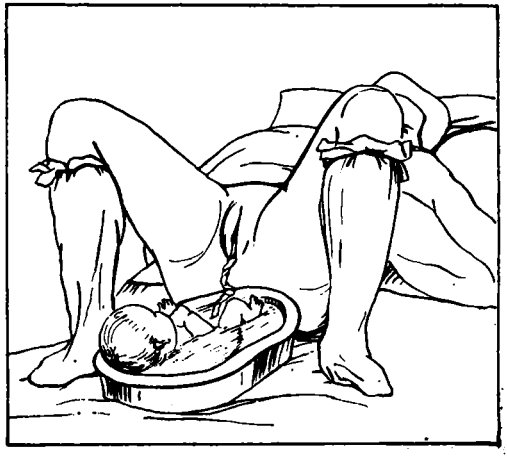

Fig. 163. A neonate born in asphyxia placed in a warm water bath

enter them during asphyxia. A bulb syringe is used for the purpose. If this measure fails to initiate respiration, mucus should be removed from the trachea. A sterile elastic catheter is attached to the bulb syringe, air is expressed from the bulb, the end of the catheter guided by the finger into the trachea (Fig. 164) and the pressure on the rubber bulb is released.

Fig. 164. Aspiration of mucus from the trachea

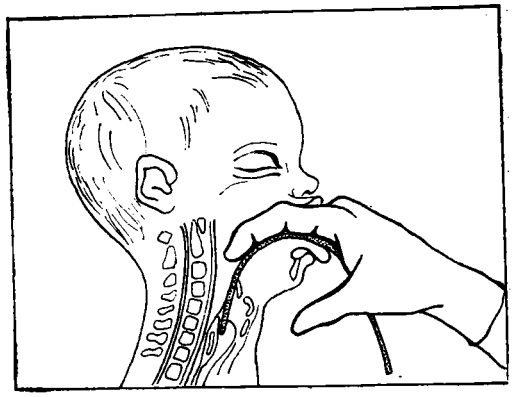

Mucus is thus aspirated from the trachea and large bronchi. If much mucus is present, the aspiration should be repeated. This method is often successful: the infant begins to breathe, its skin becomes pink.

3. If the infant starts breathing but respiration is irregular and superficial, the chest and the occiput of the infant can be sprinkled over with cold water. Sprinkling is also used during the transition of the asphyxia pallida into asphyxia livida.

Fig. 165. Apparatus for artificial lung ventilation:
a —gas mask; *b* — 'Vita-1' apparatus for artificial lung ventilation



4. All infants born in asphyxia should be given 0.2-0.3 ml of a 10 per cent caffeine solution subcutaneously, a 5 per cent sodium hydrocarbonate (4-8 ml) and a 10 per cent glucose solution (10-15 ml) intravenously. Intravenous injections should be performed by a physician.

When the umbilical cord stops pulsating, it is cut, the infant is given its first toilet, and wrapped in warm swaddles.

5. These measures may prove ineffective in grave asphyxia. Artificial respiration should then be given to the infant. Apparatus for artificial lung ventilation are now successfully used

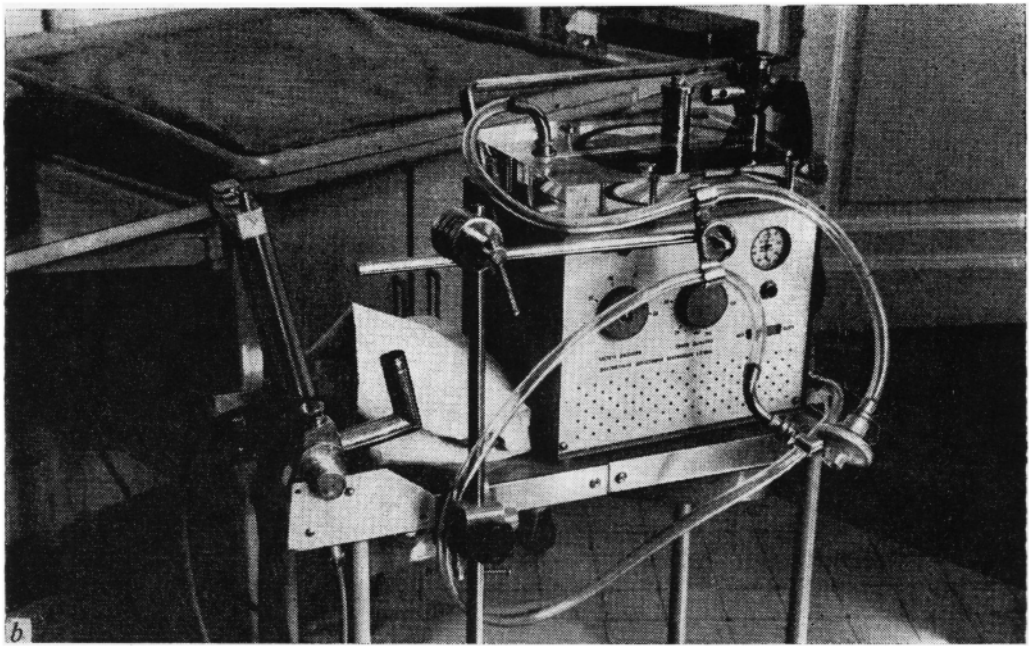

for the purpose. These apparatus control the insufflation of the ambient air or a mixture of oxygen and air. Artificial respiration with this apparatus will unfold the lungs and initiate gas exchange. The nerve endings are stimulated by this procedure. This causes reflectory stimulation of the respiratory centre which in turn initiates spontaneous respiration.

Apparatus for artificial respiration of various design are available. These may be gas masks and apparatus requiring preliminary intubation. The former type apparatus consists of a mask, which covers the mouth and the nose of the neonate, and a rubber bag by which the air is insufflated into the infant's airways (Fig. 165, *a*). The apparatus is hand-operated.

An apparatus shown in Fig. 165, *b* ensures artificial ventilation of the lungs with accurate batching of the air or an air-oxygen mixture (1:1).

The air is insufflated in 30-40 ml portions at a pressure of 20-40 mm H_2O at a rate of 20-25 per min.

If the apparatus is not available at the moment, the mouth-to-mouth insufflation may be used, or older (mechanical) methods can be used by which the chest of the neonate is stimulated to induce passive entrance of the air into the infant's lungs.

The mouth-to-mouth respiration (20-30 insufflations per min) should be given after placing a wet sterile gauze over the baby's mouth. This method is however fraught with danger of infection of the infant.

Mechanical compression and expansion of the infant's chest are now rarely used because of the low efficacy. The **Sokolov method** consists in the following: one hand of the physician grasps the infant's legs and the other hand is placed under the occiput (Fig. 166, *a*). The legs are flexed on the abdomen and the head on the chest simultaneously. This operation should be repeated 20-30 times per min. Accord-

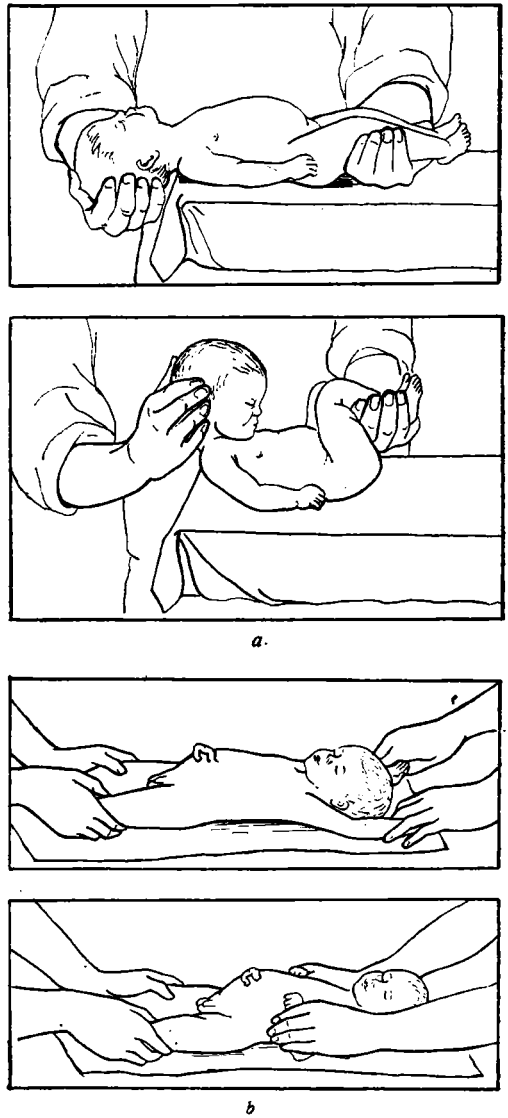

Fig. 166. Resuscitation of a neonate: *a* — by the Sokolov method; *b* — by the Silvester method

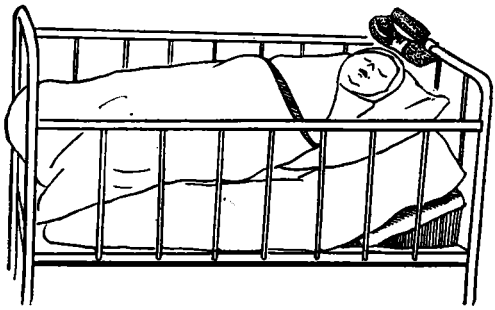

Fig. 167. The neonate with an intracranial injury in the crib: the head is slightly lifted and an ice bag is hanged above the head

ing to the **Silvester method,** the infant is placed on a table covered with a sterile swaddle. The infant's hands are raised up above the head (inspiration) and then pressed against the chest (expiration). The nurse should hold the baby by its legs (Fig. 166, *b*). This operation should be repeated 20-30 times per min.

Infants born in asphyxia may develop haemorrhage in the brain and other organs. All manipulations should therefore be carried out very carefully.

L. S. Persianinov suggested that 3 ml of a 10 per cent calcium chloride solution and 5-7 ml of a 40 per cent glucose solution be administered into the umbilical artery of the infant born in asphyxia. If this does not help, blood (30-40 ml) should be given intra-arterially.

Revived infants need thorough observation. They may have relapses of asphyxia or develop intracranial haemorrhage.

Labour and Delivery Injuries of the Neonate

Various injuries can be inflicted to the foetus during pathological delivery, such as dislocation and fracture of bones, haematoma, paresis and paralysis, injuries of the spine, etc. Intracranial injury is most frequent among other injuries of labour.

A typical sign of an intracranial injury is haemorrhage localized in the cerebral membranes, in the medulla and the ventricles. In rare cases the injury is due to compression of the brain without haemorrhage. Intracranial injury may develop because of haemorrhage provoked by asphyxia. But the most frequent cause of intracranial labour injury is combination of asphyxia and compression of the foetal head by the walls of the birth canal. Complicated and improper obstetric manipulations can be the cause of intracranial and other injuries of labour.

Clinical signs of intracranial labour injuries manifest immediately after birth or later (on the second or third day of the infant's life). The symptoms vary depending on the extent of the injury and localization of the haemorrhage.

The early symptom is excitation of the baby. It is restless, cries occasionally, moves automatically. General convulsions, or convulsions of separate muscles (mostly face muscles) occur at times. The excitation is followed by sleepiness, the baby stops crying, sucks the breast unwillingly or does not take it at all. The respiration is irregular and slow, the pulse rate is also slow and arrhythmical. The skin is pale or slightly cyanotic, the extremities are cold. The body temperature drops or (less frequently) rises.

The symptoms of intracranial injuries are less distinct in premature infants. Convulsions and excitation are infrequent. The injury manifests in the grave general status of the baby (irregular respiration, cyanosis, low body

temperature, atony, irregular sucking and swallowing, etc.). Grave intracranial injuries can cause neonatal death.

If proper care is taken, most infants born with signs of intracranial injuries survive. The treatment consists in stoppage of the intracranial bleeding, for which purpose the infant should be kept absolutely quiet. It should be placed in bed so that the upper part of its body be slightly raised. A rubber bag filled with ice should be attached above the neonate so that it hang near the head without touching it (Fig. 167). The infant should be well wrapped in swaddles and a hot (60°) water-bag placed at its legs.

The mother does not feed her baby during the first 3 or 4 days and the infant is fed in its crib with the mother's milk from a bottle or a spoon. If the swallowing reflex is weak the infant should be fed through a probe. Swaddling and washing of the infant should be done with much precaution. The treatment is prescribed by the physician: haemostatics and means strengthening the general condition are given per os: a 10 per cent solution of calcium chloride, one teaspoonful three or five times a day, vitamin K 5 to 10 mg daily, ascorbic acid to 50 mg daily. Aminazin and bromides should be given if the infant develops convulsions.

In disordered respiration oxygen should be given to breathe. If attacks of asphyxia develop, mucus is aspirated from the airways, the infant is given oxygen and 0.1 ml of cordiamine subcutaneously. In case of cardiac failure, caffeine is given (0.5 ml of a 1 per cent solution, one teaspoonful three or four times a day).

Prophylaxis of intracranial injuries consists in control of asphyxia and careful conduct of labour. Careful management is very important for successful resuscitation of infants born in asphyxia.

Infectious Diseases of Newborns

The resistance of the newborn to pathogenic microbes such as staphylococci, streptococci, *E. coli*, etc., is much lower than in older children and in adults.

Should the conditions be unfavourable, microbes can enter the umbilicus, airways, skin, or gastrointestinal tract and cause various infectious diseases in the neonate. Local infectious processes (pyodermia, inflammation of the umbilicus, etc.) can become the source of general sepsis.

Pyodermia (purulent skin disease) of neonates is usually caused by staphylococci that get on the neonate skin from the environment (medical personnel that may be carriers of the microbes, the mother, nonsterile linen, etc.). As staphylococci penetrate the skin of the neonate, pustules are formed at the site of entrance of the microbes. The pustules contain turbid fluid and do not produce appreciable hyperaemia of the surrounding skin. The treatment is local: thorough care of the skin, washing in a dilute solution of potassium permanganate, treatment of the affected sites with a 70 per cent alcohol and brilliant green solution.

The infection of the skin can provoke a more serious disease, pemphigus. The disease develops in one or two weeks after birth. Bullae, the size of a pea or more, appear on the skin. Their contents is first clear, then turns purulent. The disease often develops without marked general disorders. Treatment: antibiotics, locally 70 per cent

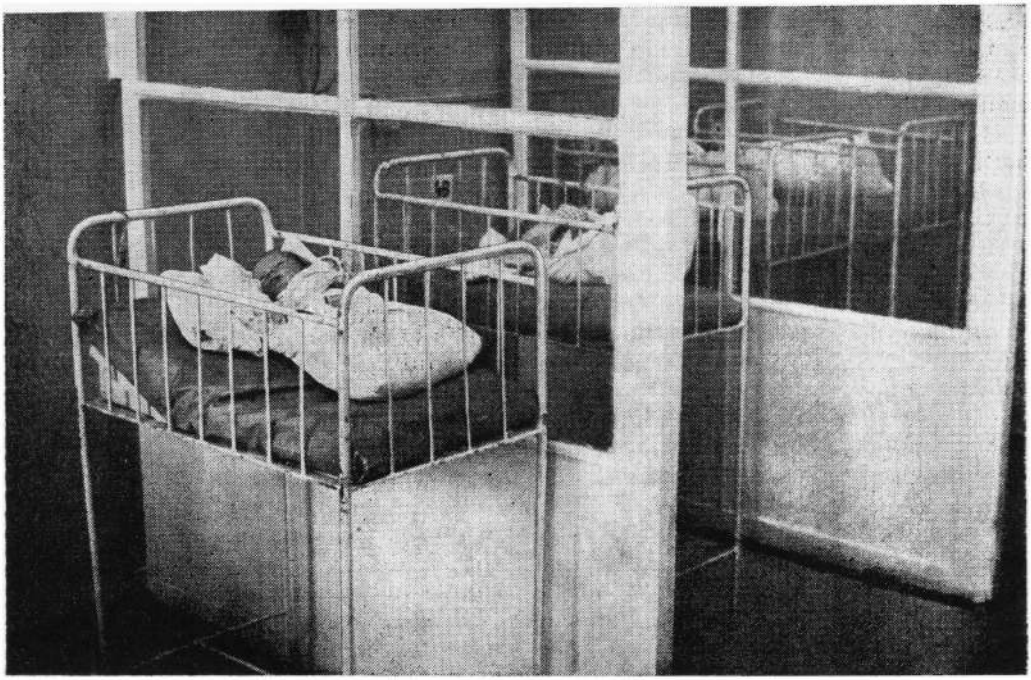

Fig. 168. Infants with infection

alcohol and brilliant green; hydrocortizone ointment can be prescribed if indicated.

Diseases of the umbilicus. As the umbilical wound heals, an inflammatory reaction may develop with liberation of serous or serous-sanies exudate (catarrhal omphalitis). Treatment: 70 per cent alcohol, 5 per cent potassium permanganate solution. If untreated in due time, superfluous granulation tissue (fungus) may grow. Treatment of fungus: washing with hydrogen peroxide, application of silver nitrate pencil or bactericidal powder (sulphadimezine and penicillin). If purulent omphalitis occurs, the surrounding skin reddens and infiltration develops. The infection can spread through vessels. It can be complicated by peritonitis and sepsis. The infant should be treated by a paediatrist in a specialized clinic (antibiotics, gamma globulin, etc., local treatment).

Sepsis. This is a systemic disease caused by pathogenic microbes which spread from a local focus (pyodermia, omphalitis, etc.), airways (rhinitis, pneumonia), or the intestine (enteritis).

The sources of infection may be infected infants, the mother, medical personnel who are carriers of pathogenic microbes, various objects of the environment, linen, etc. The precursors of sepsis are slow gain in weight, anaemia, regurgitation, conjunctivitis, rhinitis, skin infections, omphalitis. The early symptoms are the absence of appetite, refusal of the breast, vomiting, pallid or cyanotic colour of the skin.

The temperature reaction may be absent in neonates with sepsis, the general status of the infant being sharply upset: the turgor of the tissues decreases, the infant loses weight, the skin turns pale grey or yellow, diarrhoea and dyspnoea develop, the infant vomits. The liver and the spleen are enlarged. Eruption sometimes occurs. Moderate leukocytosis and leukopenia develop. Sometimes septic infection is characterized by the appearance of purulent (pyemic) foci (pneumonia, otitis, etc.).

The infant should be treated by a paediatrist at a specialized clinic (antibiotics, gamma globulin, blood and plasma transfusion, administration of vitamins, glucose, etc.).

Infectious diseases, especially purulent omphalitis and sepsis, are dangerous not only for the infant but for the other neonates since in the absence of proper isolation the infection can become epidemic.

Such epidemic outbreaks occur in lying-in hospitals where the rules of sanitation and hygiene are violated. When the obstetric department is managed properly and the neonates are given adequate care, infectious diseases do not occur (see Chapters 6, 9, 11 and 12). Timely isolation of infected mothers and infants is very important in this respect.

Puerpera with signs of infection (elevated body temperature, rhinitis, cough, hyperaemia of the pharynx, etc.) should be placed in isolated wards separately from healthy women; when feeding their infants, the mothers should wash thoroughly their hands and the breast, and wear a gauze mask. When first signs of infection (however insignificant they may be) develop in the infant, it should immediately be isolated from the other neonates. Separate rooms should be provided for the purpose (Fig. 168). Special overalls for the medical personnel and all other objects that might be needed for the care of the infected neonates should be available in this room.

If toxic infections are detected among the puerpera, the lying-in hospital should stop admission of new parturients and all measures of disinfection should be taken.

An independently working obstetrician should immediately report any slightest sign of disease in the neonate to the physician.

Chapter Thirteen

BREECH PRESENTATION

Breech presentation occurs on the average in 3.5 per cent parturients. In most cases breech birth is normal, but various complications often arise that may have an adverse effect on the foetus and the mother. Asphyxia, labour injuries and stillbirths occur more frequently in breech births. In this connection, breech presentation is regarded as a bordering condition between norm and pathology.

Classification of Breech Presentations

Breech presentations are classified as (1) frank breech, (2) complete breech, and (3) footling presentations.

1. In *frank breech presentation* the legs are extended and the thighs are flexed on the abdomen, the rounded caudal pole occupying the lower uterine segment (Fig. 169).

2. *Complete breech presentation* is characterized by the flexion of the thighs on the abdomen and the legs on the thighs, the feet lying in the birth canal at approximately the same level as the caudal pole of the foetus (Fig. 170).

3. *Footling presentation* is subdivided into *double* and *single* footling (Figs. 171 and 172, respectively) which are characterized by extension of two or one extremity into the birth canal. In rare cases one or both thighs may become extended while the legs remain flexed, resulting in presentation of one or both knees. As the labour progresses this variety changes to footling presentation.

The incidence of frank and complete breech is twice as more frequent compared with footling presentations, and single footling occurs more frequently than double footling presentation.

Causes of breech presentation are not completely clear.

Breech presentation often occurs in premature labour, in multiparas with decreased uterine tone, and in multiple pregnancy.

Conditions that interfere with the entrance of the foetal head into the lower uterine segment are also important: placental presentation, myomatous nodes in the lower uterine segment, abnormal structure of the uterus. Sometimes the foetus loses its mobility due to insufficient amount of the amniotic fluid and cannot assume the position with the head down.

Diagnosis of Breech Presentation

Breech presentation is mainly diagnosed by external and vaginal examinations of the pregnant.

Palpation of the abdomen reveals soft rounded (irregular) presenting part over the pelvic inlet plane (or in the

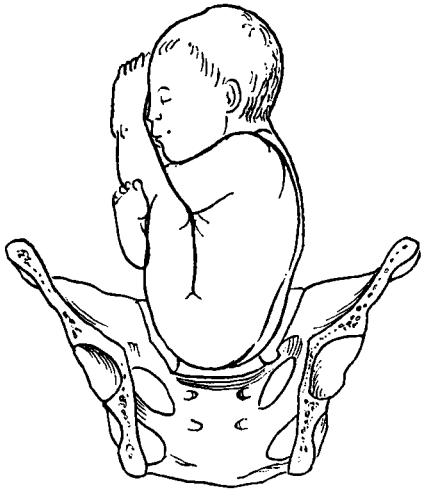

a

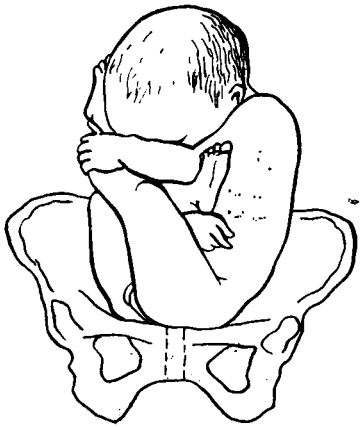

b

Fig. 169. Frank breech presentation: *a* — left sacrum anterior; *b* — left sacrum posterior

Fig. 170. Complete breech presentation; right sacrum posterior

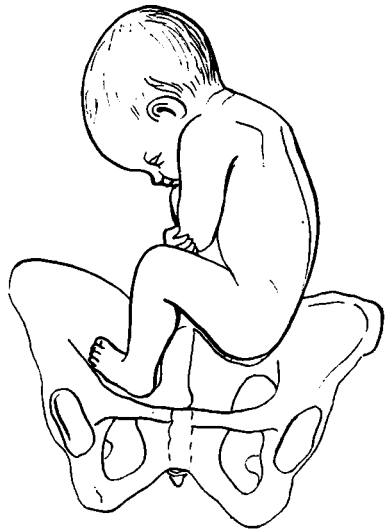

Fig. 171. Double footling, left anterior presentation

pelvic inlet). The presenting part is unballotable. The head can be palpated at the uterine bottom. It is ballotable. round, solid, and can be deflected to either side of the median line. The foetal heart tones can be best heard in breech presentation above the navel of the mother, sometimes at the level of the navel, on either of its sides (depending on position).

The level of the uterine bottom is high in breech presentation.

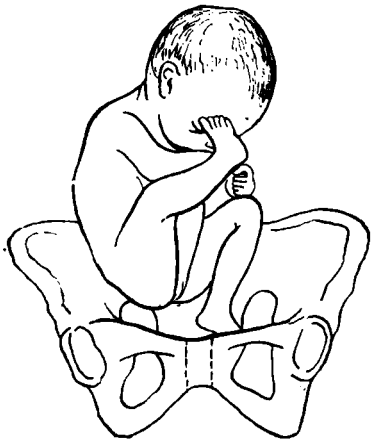

Fig. 172. Single footling, right posterior presentation

It is not always easy to identify the head and pelvis by external palpation. The vaginal examination is then necessary. If however these methods fail, X-rays or ultrasound can be used (Plate 5).

Vaginal examination during labour gives definite information on the presenting part, especially after the membranes have ruptured and the cervix is open wide enough.

Frank breech presentation can be diagnosed by palpating a bulky soft part on which the ischial tuberosities, the sacrum, the coccyx, the anus or the sex organs can be identified. The finger, examining the foetal leg, can feel the groin. A foot lying by side of the buttocks can be palpated in complete breech presentation.

If the sacrum can be identified by palpation, the position of the foetus back will be determined.

The swell on the presenting part (oedema) can be of considerable size, and an inexperienced obstetrician can mistake face for breech. Therefore the sacrum, the coccyx, the groin or foot should be identified for accurate diagnosis. The anal or genital region should be palpated very carefully to preclude possible injury.

Footling presentation is usually easy to diagnose by vaginal examination. The following differences between the foot and the arm should however be remembered. The foot has the heel bone, the toes are even and short, the first toe is not separated and is immobile, while the thumb on the hand is easy to flex on the palm. The elbow differs from the knee in the absence of a round movable kneepan. The position of the kneepan is indicative of the foetal position. The kneepan is directed to the left in left presentation and to the right in the right one.

Pregnancy and Mechanism of Labour in Breech Presentation

Pregnancy in breech presentation does not differ from that in cephalic presentation. The pregnant women are recommended to lead normal life with observation of the hygienic and nutrition requirements for the pregnant.

Bearing in mind that breech birth is often complicated, some authors suggest that the foetal poles be reversed externally by version (see page 376). B. A. Arkhangelsky and M. B. Trubkovich have developed methods for external version of the foetus and formulated indications and contraindications for such an operation. The authors maintain that version of the foetus reduces stillbirths and recommend that the foetus be turned externally on the 35-36th week of pregnancy. It is necessary to note that external version may have an adverse effect on the foetal condition and obstetricians prefer that the pregnant perform exer-

cises by which the position can be changed (I. I. Grishchenko and I. F. Dikan). The exercises are as follows: the pregnant lies in her bed and turns from side to side 3 or 4 times at ten-minute intervals. The exercise should be done 3 times a day. If normal amount of the amniotic fluid is contained in the uterus and the form of the uterus is normal, the foetus turns upside down within the first seven days. If it fails, breech birth is diagnosed.

Breech birth would normally end successfully but complications are not infrequent and may have an adverse effect on the foetus and, less frequently, the mother.

The *first stage of labour (dilation)* can be normal but complications can often occur. The most frequent and dangerous complication in breech birth is *early* or *premature* escape of the amniotic fluid. Its incidence is especially high in footling presentations. The podalic pole is smaller than the cephalic one and as it descends the pelvis its contact with the walls of the birth canal is incomplete and the seal by the line of engagement is thus absent. During each contraction the fluid is expressed into the lower segment of the uterus and the membranes are extended. When the thrust of the fluid increases the membranes fail to withstand the pressure and rupture prematurely. As the amniotic fluid escapes the uterus the umbilical cord may prolapse. The incidence of this complication is five times higher in breech presentation, but the prolapse of the umbilical cord in cephalic presentation is more dangerous for the foetus. The prolapsed loop of the umbilical cord can be compressed in breech presentation as well; hence asphyxia and foetal death are possible.

Atony of labour often develops in breech presentation especially with early and premature discharge of the amniotic fluid; the cervix then dilates very slowly and the hips stay over the pelvic inlet for considerable time.

The *expulsive stage* has its specific features which are explained by that the largest part of the foetus, the head, is delivered the last, not the first. The foetal hips are the first to engage in the birth canal; they are a less voluminous part of the body and cannot dilate the birth canal to the extent necessary to pass the shoulders and the head. As the foetus shoulders engage in the pelvis, the arms can be retained and the aftercoming head thus compressed. The delivery of the head is thus delayed. As the upper part of the foetal body and the head pass the pelvis, the umbilical cord may be compressed. If the expulsion of the upper part of the body and the head is delayed over 3 to 5 minutes, asphyxia develops. These complications more often occur in footling presentations because the forthcoming legs do not dilate the birth canal to the required extent.

Mechanism of Breech Birth

In breech birth foetus performs certain movements which on the whole are known as the mechanism of labour.

1. The hips of the foetus enter the pelvis so that the bitrochanteric diameter aligns with the one of the oblique diameters of the mother's pelvis (Fig. 173). The hips of the foetus descend into the mother's pelvis with the leading buttock below the aftercoming buttock. The anterior buttock is thus the *leading point* and a swelling is formed on it.

2. The buttocks are *rotated* in the

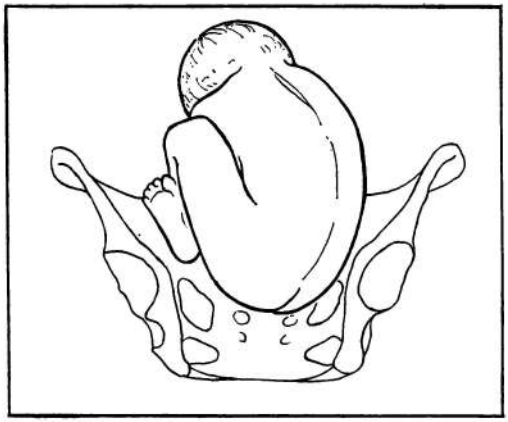

Fig. 173. Hips descend into the small pelvis the first movement of labour)

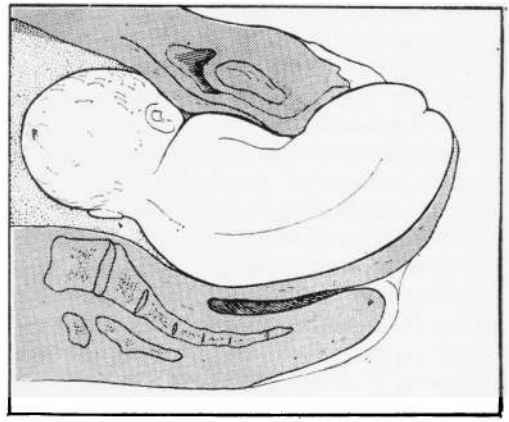

Fig. 174. Lateral flexion of the body. Delivery of the hips (the third movement of labour)

pelvic cylinder as they pass it, and align with the anteroposterior diameter of the pelvis: the anterior buttock rests against the os pubis and the posterior faces the sacrum.

3. The *buttocks now 'crown'* and the anterior one is delivered first: the iliac bone of the foetus bears against the pubic arch, which works as a fulcrum around which the foetal body is flexed to a high degree (Fig. 174), and the posterior buttock is delivered. The buttocks are delivered together with the legs in complete breech presentation, and the legs prolapse after the delivery of the body in frank breech presentation. After the lower end of the body has been delivered, it is deflexed and by a few contractions is delivered to the navel and then to the lower angle

Fig. 175. Complete rotation of the shoulders, the shoulders align with the anteroposterior diameter of the pelvic outlet plane (the fourth movement of labour)

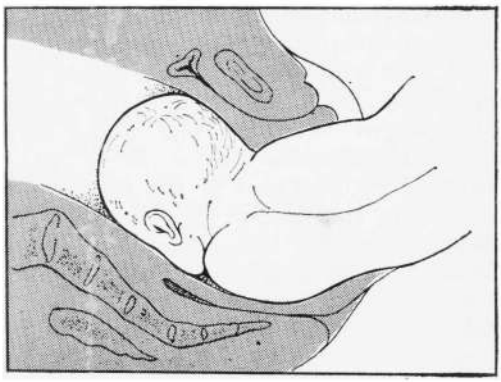

Fig. 176. Delivery of the aftercoming head (the fifth movement of labour)

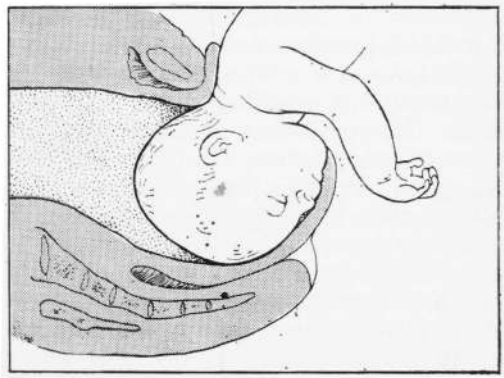

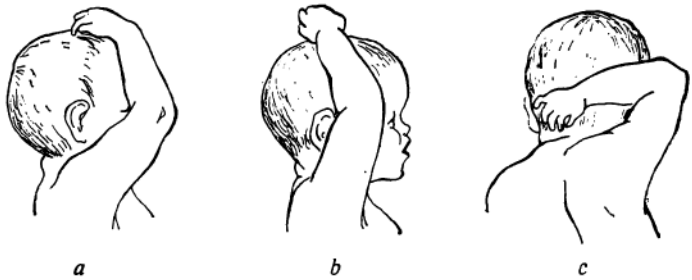

Fig. 177. Extension of the arm:
a — the first degree; *b* — the second degree; *c* — the third degree (nuchal position)

of the shoulder blades; the body is slightly turned with its back anteriorly.

4. The transverse diameter of the shoulders aligns with the oblique diameter of the mother's pelvis (the same as with the passage of the buttocks) but later turns to align with the anteroposterior diameter of the pelvis (Fig. 175). The anterior shoulder is brought under the symphysis while the posterior one is delivered over the perineum. The arms flexed on the chest are delivered spontaneously or released by obstetrician manipulations.

5. The flexed head aligns with the oblique diameter of the pelvis (opposite to that through which the hips and the shoulders have passed) and rotates with its occiput anteriorly (toward the os pubis) and with its face posteriorly inside the pelvic cavity of the mother. The head rests against the pubic arch with its posterior cranial fossa, the os pubis working as the fulcrum (Fig. 176).

First the chin, next the face, sinciput, the vertex and the occiput are delivered. The head is thus delivered in breech presentation by its suboccipitobregmatic diameter. The head is not moulded because of its rapid delivery and its shape is therefore rounded.

The mechanism of labour is about the same in footling presentation, the difference being in that one or both feet emerge from the pudendal cleft. The leading is the anterior leg (nearer the symphysis). When the leg is delivered to the knee level, the buttocks enter the pelvis. The further mechanism is the same as in frank and complete breech presentations.

Breech birth is often associated *with complications* which are unfavourable for the mother and especially the foetus.

Fig. 178. The head is deflexed; the chin is held by the symphysis

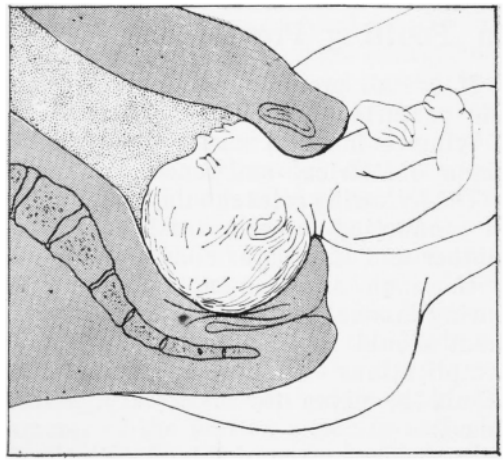

1. One of the important complications is *extension of the arms*. The arms may deflex and extend over the face, the head, or the occiput (Fig. 177). The volume of the head and the arms increases greatly compared with the diameter of the head alone and labour cannot be accomplished successfully. If the woman is not given timely aid the foetus perishes from anoxia.

2. During normal labour the back of the foetus turns anteriorly (anterior presentation). In some cases the back turns *posteriorly* (posterior presentation).

In the course of labour the posterior position of the foetus can spontaneously change to the anterior one. If this does not happen, labour can be delayed. If the head is flexed, the bridge of the nose rests against the symphysis and the occiput is delivered over the perineum. In some cases a grave complication occurs when the chin of a deflexing head is held over the symphysis (Fig. 178). Unless an urgent obstetrical assistance is given, the foetus perishes from asphyxia.

Conduct of Labour in Footling Presentation

If breech presentation is diagnosed, the parturient should be delivered to a lying-in hospital where she may be given obstetrical assistance.

The following rules should be observed in conducting breech birth: (a) the mother and the foetus should be given a thorough and constant observation during labour, (b) the expectant treatment should be adhered to, (c) if any complications arise, the parturient should be given the necessary assistance.

In the first stage of labour (dilation) measures should be taken to preclude early or premature rupture of the membranes. The parturient should stay in her bed during the entire period; a bedpan should be given for urination or defaecation. In case of uterine atony special medicines should be given to stimulate contractility of the uterine muscles. As soon as the amniotic fluid has escaped the uterus, a vaginal examination should be given to the parturient to verify the diagnosis and to preclude the prolapse of the umbilicus.

The second stage of labour requires special attention. The status of the foetus should be under constant watch; the *foetal heart tones should be listened and counted after each contraction*. Obligatory measures should be taken to preclude foetal asphyxia (breathing with oxygen, intravenous injections of glucose, ascorbic acid, intramuscular injection of cardiazole). Meconium is expressed mechanically in breech presentation and its discharge does not indicate the danger of asphyxia. The main symptom of developing intrauterine asphyxia is the disordered cardiac function. To prevent spasm of the uterine cervix, it is recommended that 1 ml of atropine sulphate (1:1000) and 1 ml of a 1 per cent papaverine solution should be injected to the parturient.

As soon as the hips begin 'crowning', the parturient should be placed so that her pelvis is at the edge of the bed. To that end the lower end of the Rakhmanov bed is collapsed and put beneath the head end. If the Rakhmanov bed is not available, the parturient should be placed across a common bed so that the pelvic region rests upon the bed edge while the abducted legs are supported by stools.

Four stages are distinguished in breech birth: (1) delivery of the foetus

to the navel; (2) delivery of the foetus from the navel to the lower angle of the shoulder blades; (3) delivery of the arms, and (4) delivery of the head.

The head becomes engaged in the pelvis when the foetus is delivered to the navel. The umbilical cord is now compressed and if the delivery is not completed within a few minutes after the delivery of the navel, the foetus is born in asphyxia. If the umbilical cord remains compressed for over ten minutes, the foetus usually perishes. Therefore, before the foetus has been delivered to the navel, the expectant treatment should be adhered to. In the normal course of labour, the upper part of the body and the head are delivered quickly and no operative intervention is necessary. If delivery is not completed in three to four minutes (two or three contractions) after the delivery of the body to the navel, manual assistance is required.

Manual Assistance in Frank Breech Presentation (according to Tsovyanov)

The method of conducting labour in frank breech presentation suggested by N. A. Tsovyanov is now widely used in obstetric practice to reduce the stillbirth rate. The method is based on the preservation of normal relation between the parts of the foetal body to preclude possible complications such as extension of the arms or deflexion of the head. In normal frank breech presentation, the legs are extended along the body and press the flexed arms to the foetal chest. The feet of the extended legs reach the face and thus promote the flexion of the head with the chin resting against the chest.

According to the proposed method, the normal arrangement of the foetal parts is preserved by the extended legs which are pressed against the body and are not allowed to be delivered prematurely.

The normal arrangement of the body members is also important for the dilation of the birth canal to the extent required to pass the aftercoming head. The girth of the body with the arms flexed on the chest and the extended legs (at the shoulder level) is considerably greater than the girth of the head (42 cm against 32-34 cm), and the latter is therefore delivered without any obstacle.

Manual assistance according to Tsovyanov in frank breech presentation consists in the following. When the hips are delivered, they are grasped by hands as follows: the thumbs are pressed against the legs flexed on the abdomen, while the other fingers of both hands hold the foetus by the sacrum (Fig. 179). This position of the fingers prevents (a) premature prolapse of the legs; (b) hanging down of the delivered body. The delivered body is lifted in the direction of the extended pelvic axis. As the foetus body is being expelled from the uterus, the obstetrician moves his hands in the direction of the pudendal cleft of the parturient, pressing carefully the flexed legs against the abdomen by the thumbs; the other fingers slide higher along foetal back (Fig. 180). It is necessary that the legs should not prolapse before the shoulder girdle has been delivered. As soon as the shoulders are delivered, the arms usually prolapse spontaneously. If it fails, they are released as follows. Without changing the position of the obstetrician hands, the shoulders are turned to align with the anteroposterior diameter of the mother's pelvis and the body is deflexed posteriorly: the ante-

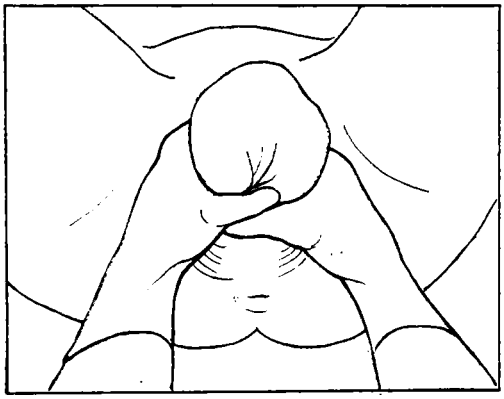

Fig. 179. Manual assistance according to Tsovyanov in frank breech presentation. Holding the body of the infant

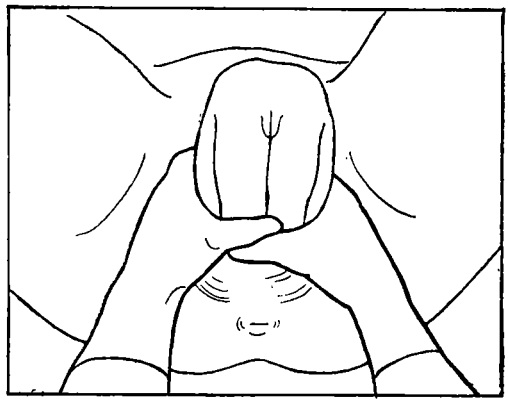

Fig. 180. Manual assistance according to Tsovyanov in frank breech presentation. As the body is expelled from the birth canal, the obstetrician hands move closer to the pudendal cleft

rior arm is delivered from under the pubic arch. The body is then lifted anteriorly and the posterior arm is delivered over the perineum.

The heels of the foetus prolapse simultaneously with the posterior arm, and the chin and the mouth show at the pudendal cleft. The head is delivered spontaneously by strong expulsive efforts, while the body should at this moment be lifted anteriorly. If the delivery of the head is delayed, it should be assisted by the Mauriceau-Levret manoeuvre (see below).

Conduct of Labour in Footling Presentations (Tsovyanov's method)

The incidence of complicated labour in footling presentations is higher than in frank or complete breech presentation.

Complications arise because the forthcoming legs cannot dilate the birth canal to the extent required to pass the bulky shoulders and the head. The head is therefore often deflexed and the arms extended in footling presentations. Not infrequently the head is compressed by the convulsive contractions of the uterine cervix.

These complications can be precluded if, by the moment of expulsion of the shoulders, the uterine os is opened completely.

To ensure this, Tsovyanov suggested that a method should be used by which the legs are retained in the vagina until the uterine os has completely opened.

If the diagnosis of footling presentation has been confirmed by the vaginal examination, the obstetrician covers the external genitalia with a sterile napkin, places the palm of the hand over it and prevents premature expulsion of the legs (Fig. 181). This ensures full opening of the uterine os because the foetus 'squats' to assume the complete breech presentation. As the foetus further moves along the birth canal, it presses the sacral nerve plexus to

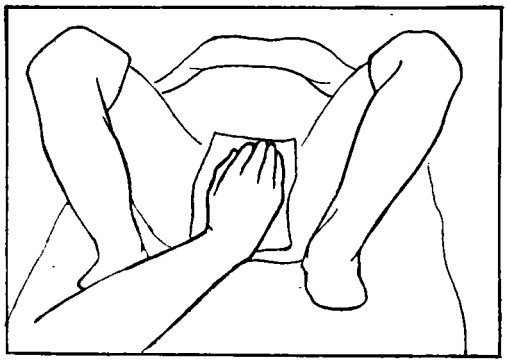

Fig. 181. Manual assistance according to Tsovyanov in footling presentation

intensify the uterine and abdominal muscle contractions.

Complete opening of the cervical os is evidenced by the protrusion of the perineal area under the thrust of the foetal hips, by the opening anus, frequent and strong expulsive efforts, and the presence of the contraction ring at the level of 4-5 finger-breadths above the symphysis. Under the downward thrust of the descending hips the pudendal cleft opens and the legs overcome the resistance of the obstetrician hand to show from under it. If the signs of full dilation are obvious, the obstetrician removes his hand and further labour is conducted as described for breech birth.

Manual Assistance in Breech Presentations

Classical manual assistance is a *set of manoeuvres* aimed to release the arms and the head of the foetus in breech birth.

When the leading parts emerge from the pudendal cleft the obstetrician should abstain from any manual assistance and should wait patiently. Pulling by the leg or the groin is contraindicated, since it will upset the normal position of the foetal parts: the arms will be extended and the head deflexed. As soon as the foetus has been delivered to the navel, the tension of the umbilical cord should be checked. If the cord is tense it should be relaxed by slightly pulling it from the uterus. If these measures prove ineffective, the umbilical cord should be cut and the delivery accelerated. If the umbilical cord passes between the legs of the foetus, it should carefully be passed over the posterior foetal hip.

As soon as the hips have been delivered, the body should be supported carefully by hands to preclude its hanging down. The fingers should not press strongly on the abdominal wall so that the internal organs of the foetus (especially the liver) should not be injured. The foetus should be held by its legs (at the hips), the thumbs resting on the sacrum, and the other fingers holding the hips without touching the abdomen (Fig. 182).

The foetus body should be kept in this position until it is being delivered. If the delivery is delayed, manual assistance is required.

The arms are first released. By this moment the foetus should be delivered to the lower margin of the shoulder blades.

The posterior arm should be delivered first since it is more readily accessible from the side of the perineum and the sacrum. Each arm should be released by the synonymous hand of the obstetrician, i.e. the left arm by the left hand and the right arm by the right hand.

The manoeuvres are as follows: the obstetrician fingers are locked about

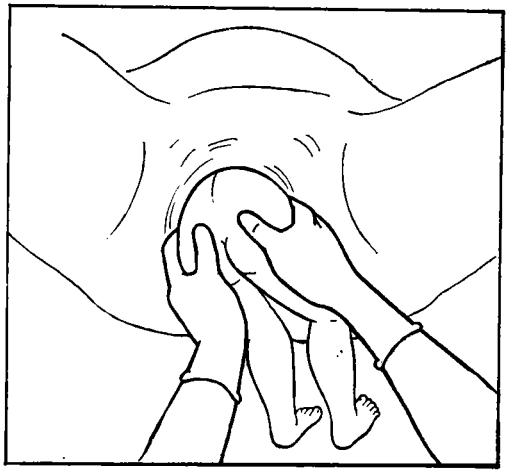

Fig. 182. The delivered body is held by its legs

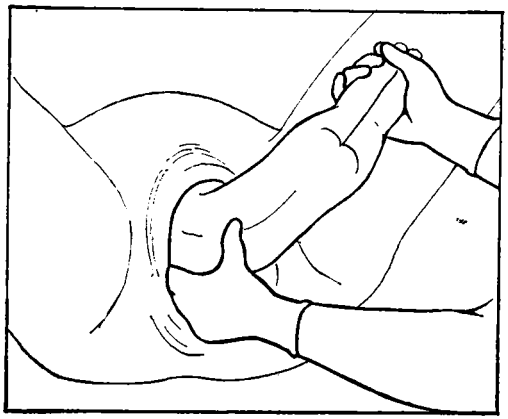

Fig. 183. The legs are pulled aside toward the mother's groin; releasing the first arm

the baby's ankles and the legs are pulled upward and toward the groin of the mother (Fig. 183); the posterior arm can be delivered spontaneously by this manoeuvre. If it fails, the arm should be extracted by the second and the third finger of the synonymous hand. The fingers should slide into the vagina along the foetal back till they reach the elbow and the upper third of the forearm. The arm should carefully be pulled down without separating it from the body. The arm should slide over the foetal face (if it is extended) and the chest downward, as if performing the washing movement.

When the posterior arm has been released, the foetal body is turned through 180° so that the other arm could be extracted from the side of the perineum. To that end the body is held by both hands at the chest (together with the extracted arm). The thumbs are placed along the spinal column and the other fingers along the anterior surface of the chest. The rotation should be done so that the back should pass under the symphysis and be directed toward the other thigh of the mother; the body should not be pulled. When the rotation is complete, the legs of the foetus should be grasped again and lifted upward in the direction of the groin; the second arm is released (Fig. 184). Now that both arms are delivered, the *head should be freed*, which is in the pelvic cavity, and is normally flexed. The assistance should simulate the normal mechanism of delivery of the aftercoming head.

The head is extracted as follows (after Mauriceau-Levret). The hand that was used to extract the second arm is introduced into the vagina, while the foetal body 'sits' on the forearm of the operating hand. The tip of the forefinger is placed inside the foetal mouth to facilitate flexure of the head and its internal rotation. The index and the middle fingers of the other hand are flexed into a fork and placed by sides of the foetal neck without pressing the clavicular bones or fossa (Fig. 185). Traction is done by the upper hand. First the direction of traction is downward (posterior). When the

posterior cranial fossa is beneath the symphysis, the direction of traction should be changed to upward (anterior): the mouth, the face, and then the entire haired part of the head are delivered over the perineum. The delivery is facilitated if an assistant presses the head downward (from the side of the abdominal wall).

The perineum is often lacerated during this manipulation since the bulky part of the body (head) passes rapidly the birth canal which has not attained complete dilation. The condition of the perineum should therefore be constantly observed during delivery of the head and episiotomy should be better done if the perineum undergoes excess strain.

The upper end of the foetus is delivered faster in multiparas. Complications with manual assistance are more frequent in primiparas, especially aged ones.

Manual Assistance in Posterior Breech Birth

The delivery of arms and legs is often complicated in posterior breech presentation. In the course of labour the posterior presentation often changes to the anterior one: the body is slowly rotated about its longitudinal axis and the foetal back turns anteriorly. If the foetus fails to rotate spontaneously, external version should be done. To that end the prolapsed posterior leg should be pulled down and turned toward the symphysis so that it becomes anterior (the body is rotated simultaneously). In posterior frank presentation the delivered body is rotated carefully about its longitudinal axis to turn the back anteriorly (to the right or to the left, depending on the initial position). If the rotation is difficult, labour is continued in posterior presentation.

Puerperium

The puerperium is normal in most women, but puerperal diseases are more frequent in breech than in cephalic

Fig. 184. Releasing the second arm after rotation of the body through 180°

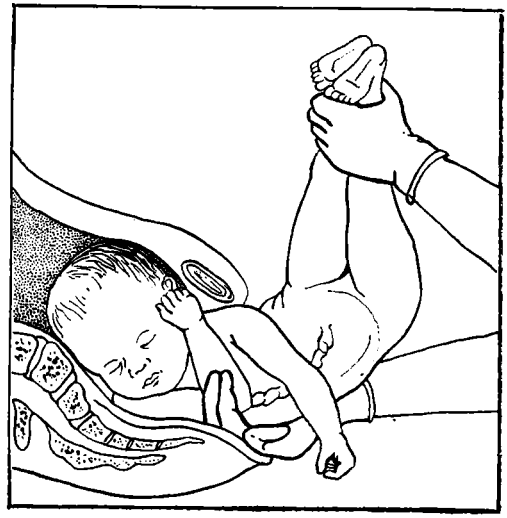

Fig. 185. Delivery of the aftercoming head

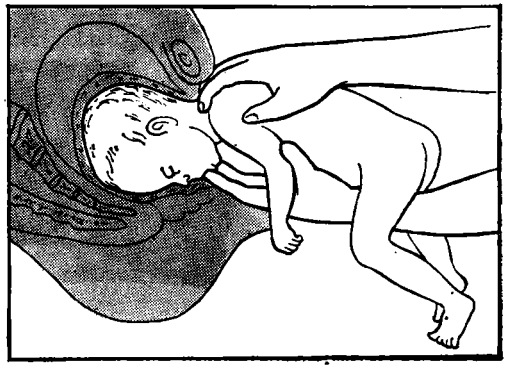

birth. This is explained by more frequent injuries of soft tissues of the birth canal, early loss of the amniotic fluid, and other complications of labour.

The prognosis for the foetus is less favourable than in cephalic presentations since asphyxia and birth injuries occur more frequently and the neonate born in asphyxia or with injuries is more susceptible to infections and other diseases.

Chapter Fourteen

MULTIPLE PREGNANCY

Pregnancy resulting in the birth of more than one infant is called multiple. *Infants born from multiple pregnancy are twins.*

Pregnancy with two foetuses occurs in one of 70 or 80 births, three infants (triplets) are born in one of 6000-7000 cases, and quadruplets or quintuplets are born very rarely.

Multiple pregnancy would be more common in aged multigravida. Heredity is also important: multiple pregnancy often occurs in families where the mother or father (or both) were born from multiple pregnancy.

Multiple pregnancy may result from simultaneous fertilization of two or more ripe eggs. Two or three eggs may ovulate from one follicle or from different (two or three) follicles which have ripen simultaneously in one or the two ovaries. Twins formed from two fertilized eggs are called *binovular (dizygotic) twins.*

Multiple pregnancy may develop also from one fertilized egg as a result of its atypical division: two (or three) germs are formed which develop into twins (or triplets). Twins born from one fertilized egg are called *monovular, (monozygotic).*

Dizygotic (binovular) twins occur much more frequently than monozygotic ones.

Dizygotic twins. Two fertilized eggs develop independently. After the fertilized eggs have implanted into the endometrium, separate chorion and amnion develop for each egg, and later each conceptus develops its own placenta with an independent vascular system. If the fertilized eggs have implanted at a distance from each other, their placentas are absolutely separated (Fig. 186). If however the eggs are near each other, the contact between the placental margins is so tight that they seem to form one whole. This fusion is only apparent and each placenta is independent with its own vascular system (Fig. 187). This can be revealed by a close examination: each conceptus has its own amnion and chorion. The partition separating the two conceptuses consists of four membranes: two amnions and two chorions (Fig. 189). These membranes are easy to separate from each other. Dizygotic twins can be alike or unlike in sex.

Monozygotic twins. Monozygotic twins have one chorion and placenta in common (Fig. 188). The vessels of the twins communicate through many anastomoses. Each of the twins has, as a rule, its own amnion; the partition between the two conceptuses is composed of two amnions (Fig. 190), and only in rare cases both twins have one common amnion (monoamniotic twins).

Monozygotic twins are always alike in sex (both are girls or boys). They have the same blood group and are very much alike in appearance.

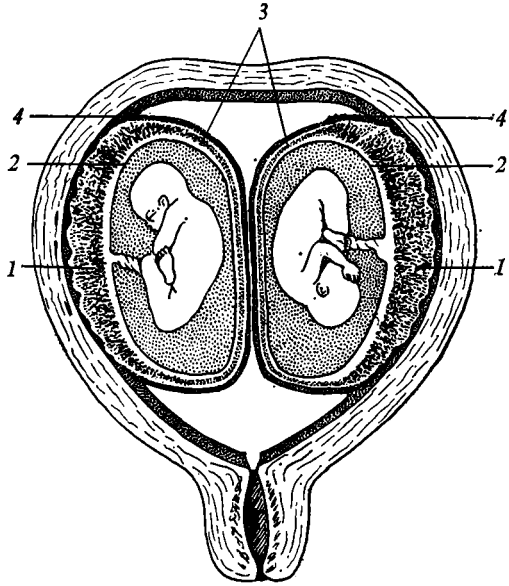

Fig. 186. Two eggs implanted in the uterus at a distance from one another: each foetus has its own placenta (*1*), amnion (*2*), chorion (*3*) and decidua capsularis (*4*)

Fig. 187. Two eggs implanted near each other; the placentas (*1*) almost touch each other. Each foetus has its own amnion (*2*) and chorion (*3*); the decidua capsularis (*4*) is common

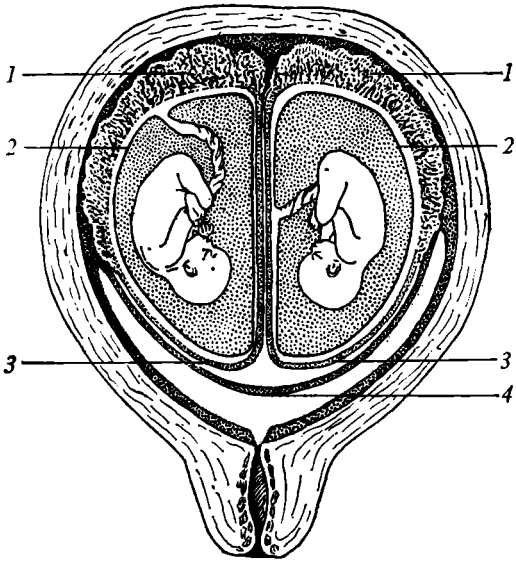

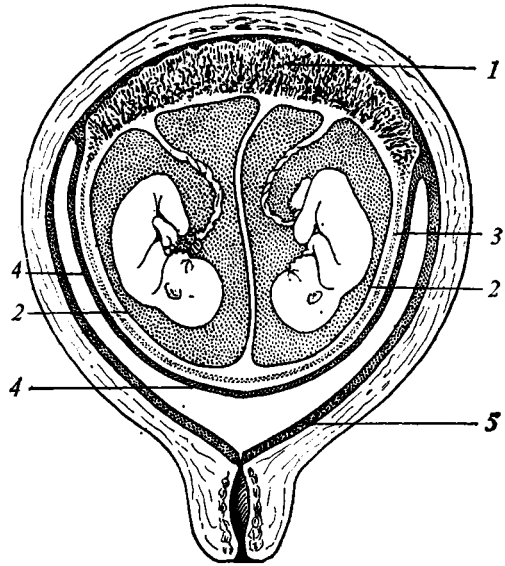

Fig. 188. Monozygotic (monovular) twins. The placenta is common, each foetus has its own amnion:
1 — placenta; *2* — amnion; *3* — chorion; *4* — decidua capsularis; *5* — decidua parietalis

Zygosity is determined by examining the placenta (common placenta, two separate, or contacting placentas) and the membranes. The factor which is decisive for the diagnosis is the number of leaves in the partition separating the conceptuses (two or four).

Course of Multiple Pregnancy

The function of the cardiovascular system, lungs, liver, kidneys and other organs of the woman with multiple pregnancy is very intense and the course of pregnancy is more complicated than with a single foetus. Women with multiple pregnancy often complain of fatigue, dyspnoea, constipation, pyrosis, and urinary disorders.

Toxaemia of pregnancy attended with

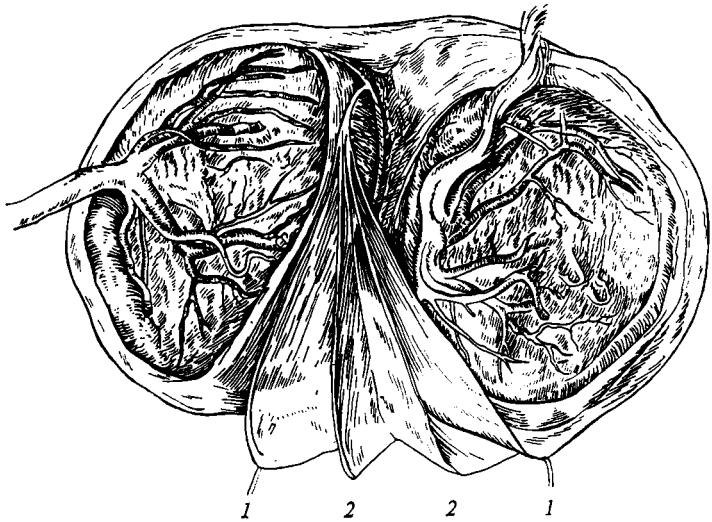

Fig. 189. The placenta of dizygotic twins. The partition separating the two foetuses comprises four membranes, viz. two amnions (*1*) and two chorions (*2*)

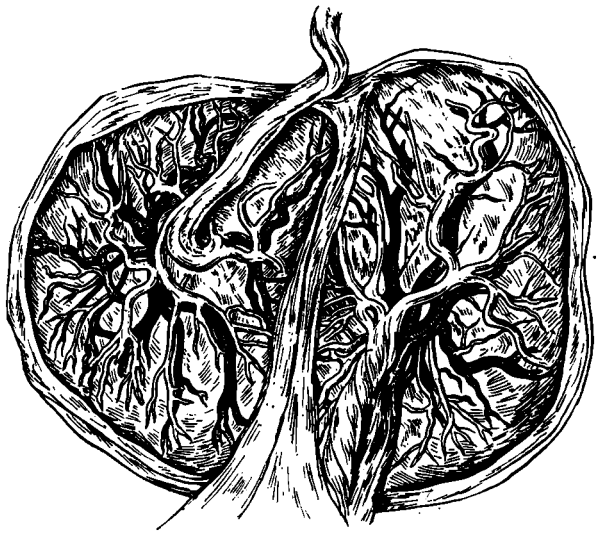

Fig. 190. Placenta of monozygotic twins. The partition separating the two foetuses consists of two membranes (two amnions)

vomiting, hypersalivation, oedema, nephropathy, and eclampsia is more frequent in multiple pregnancy.

Multiple pregnancy often ends in abortion. Labour in twin pregnancy is premature in at least 25 per cent cases,

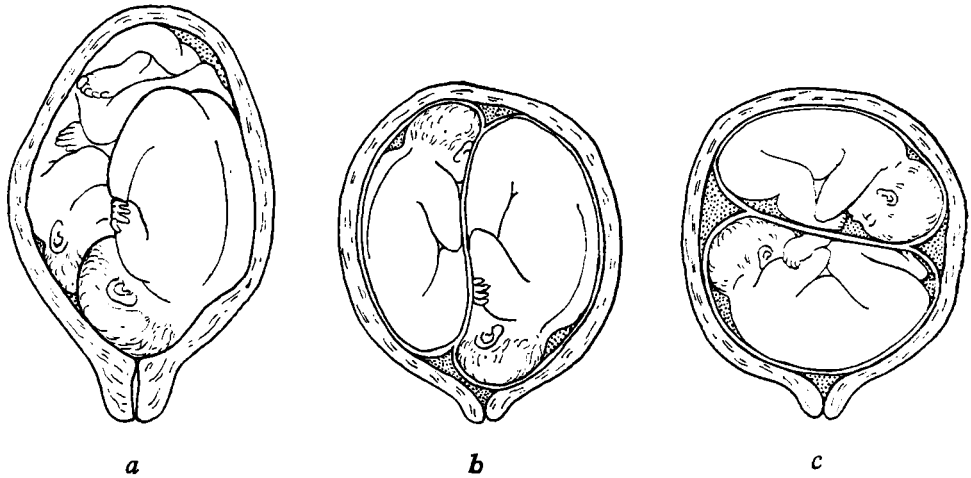

Fig. 191. Position of twins in the uterus:
a — both foetuses are presenting by the vertex; *b* — one foetus is presenting by the vertex and the other by the breech; *c* — both foetuses are in transverse position

and in triple pregnancy premature delivery is even more frequent. In general, the greater the number of foetuses, the more frequent premature delivery.

Women with multiple pregnancy should be specially observed. In the second half of their pregnancy, their blood pressure should be measured systematically, the urine tested, body weight determined, and the woman should be given systematic general and obstetric examination. Whenever signs of complications develop, the pregnant should be directed to the department for pathological pregnancy. Since labour is often premature in multiple pregnancy, the pregnant should be admitted to the lying-in hospital two or three weeks before the anticipated labour.

Twins delivered at term *develop normally* in most cases. Pre-term twins are immature functionally. Their viability is especially low if the degree of dysmaturity is high.

Monozygotic twins sometimes develop differently because of uneven supply of the nutrients from the common placenta. One of the twins receives lesser nutrition and its growth is delayed or the foetus may even perish. The surviving foetus grows to compress the dead one (foetus compressus) which is delivered together with the placenta after the birth of the live twin. Hydramnion of one foetus may develop in pregnancy with monozygotic twins and this will interfere with normal development of the other twin. Conjoint twins are born sometimes (joined at the chest, head, abdomen or pelvis).

The *position assumed by the foetuses in the uterus* is longitudinal in most cases (90 per cent). Both twins may have cephalic (or breech) presentation (Fig. 191, *a*) or one foetus may present by its head while the other by the breech (Fig. 191, *b*). Less frequently one foetus may have longitudinal and

the other transverse presentation, and in rare cases both foetuses may have transverse presentation (Fig. 191, *c*).

Diagnosis of Multiple Pregnancy

Diagnosis of multiple pregnancy presents certain difficulties, especially in early weeks. The diagnosis becomes easier as pregnancy progresses.

The uterus with multiple pregnancy grows rapidly and there is a discrepancy between the size of the uterus and the duration of gestation. The uterine bottom stands high and the volume of the abdomen is great. The girth of the abdomen at the end of pregnancy is 100 cm and over.

The most important diagnostic signs are obtained by palpation and auscultation of the foetal heart tones. Palpation of three large parts in the uterus (two heads and one pelvic end or two podalic ends and one head), or else reliable identification by palpation of two heads or two podalic ends of the conceptus is a positive evidence of multiple pregnancy.

The presence of two zones where foetal heart tones are clearly heard is another important sign of multiple pregnancy (Fig. 192). This sign is positive if (1) there is an area separating the two zones and (2) the heart rates in the two zones are different. In the latter case the pulses should be counted by two persons simultaneously.

The large size of the pregnant uterus and the high level of its fundus (while only a small head is palpated) evidence for multiple pregnancy. Motion of the foetus and also identification of its smaller parts in various regions of the abdomen also indicate multiple pregnancy.

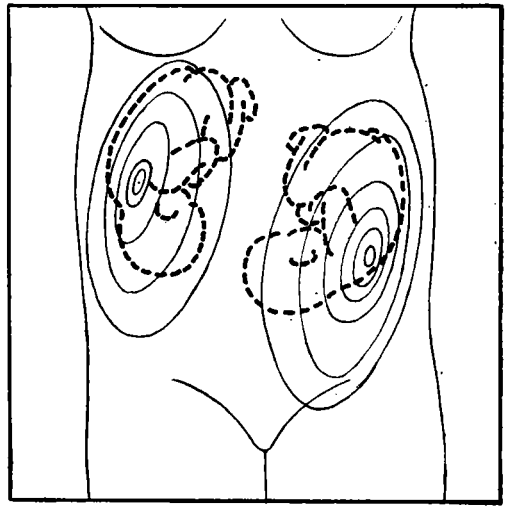

Fig. 192. Foetal hearts are clearly heard at two zones

The signs of multiple pregnancy are often indistinct and its diagnosis becomes difficult. X-rays can then be used which clearly show the number of foetuses present in the uterus and their position (roentgenography is done in the late weeks of pregnancy).

Labour in Multiple Pregnancy

Labour in multiple pregnancy can be normal. The cervix is dilated, the membranes of one foetus are ruptured and one of the foetuses delivered. After the first delivery the expulsive efforts are suspended for a period from 15 to 60 minutes (sometimes over 60 minutes) during which the uterus becomes adapted to its new decreased volume. The expulsive efforts are then resumed. The membranes of the second conceptus are broken, and another foetus delivered. After delivery of the second foetus, both placentas are separated from the uterine wall and ex-

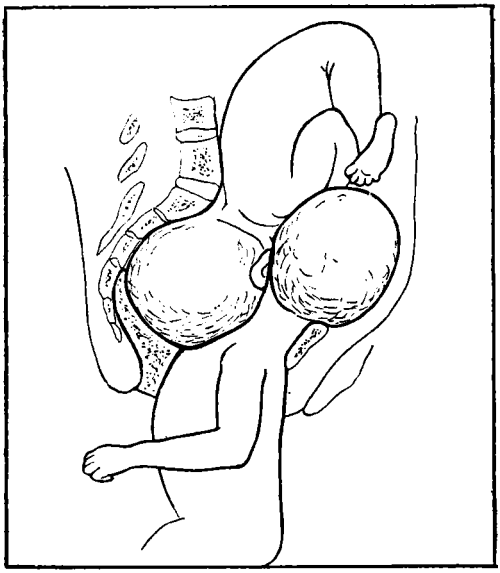

Fig. 193. Twin interlocking

pelled simultaneously from the uterus and the birth canal.

This mechanism of labour and delivery is however ideal and various complications are quite frequent.

A frequent complication is uterine atony due to excess extension of the uterine muscles which thus become incapable of strong contractions. The dilation period becomes protracted. The expulsive stage can also be prolonged.

The delivery of the first foetus may be followed by premature separation of the placentas of both the first and the second (not yet delivered) foetus, or of their common placenta. Profuse bleeding that attends premature separation of the placenta is dangerous to the mother and the foetus.

Sometimes the rupture of the membranes of the second foetus is delayed. The membranes should then be ruptured artificially, otherwise the delivery of the second foetus may be delayed many hours. After the delivery of the first foetus, the remaining one can assume a transverse position in the uterus and its delivery will then become impossible.

Interlocking of twins is a rare but very grave complication. A typical interlocking occurs over the pelvic inlet (Fig. 193); other locks are also possible. Obstetric operations are indicated in cases of locked twins.

The puerperium is often aggravated by bleeding due to incomplete separation of the placenta or retention of the separated placenta in the uterus.

Uterine atony can be another cause of bleeding in the first hours post partum. The involution of the uterus is often slow in the puerperium.

Conduct of Multiple Birth

Frequent complications of labour in multiple pregnancy make multiple birth a bordering condition between physiological and pathological processes. Obstetrical aiding, operations, and drugs are often necessary in multiple births, and they should therefore be conducted in the presence of a physician.

Multiple birth requires special patience on the part of the obstetrician. The condition of the parturient and the foetuses should be carefully observed and the progress of labour watched attentively. The parturient should be given a nutritive and easily assimilable food in due time, her urinary and intestinal functions should be observed, and the toilet of her external genitalia done systematically.

In cases of uterine atony the contractility should be stimulated by medicines (Chapter 21). Other interventions are usually unnecessary during the

dilation stage of labour. In cases of polyhydramnios the membranes should be ruptured artificially when the cervical os is only open two or three fingers (that is prematurely). After the excess amniotic fluid is withdrawn the size of the uterus decreases, its distension lessens and the contractility improves. A rapid discharge of the fluid may cause unfavourable sequelae such as the prolapse of the umbilical cord, the arm or premature separation of the placenta. The fluid should therefore be discharged at a slow rate. To that end, the membranes should not be punctured in the centre but at the side, and the operating hand should not be removed from the vagina at once but only slowly, thus holding back the gush of the fluid.

The expulsive stage should preferably be natural. Active obstetrical aid is only given when complications dangerous to the mother and the foetus develop. Medicines stimulating the contractions are given in cases of atony, and steps to prevent asphyxia of the foetus are taken.

After birth of the first infant, the foetal and the maternal ends of the umbilical cord are tied thoroughly. The undelivered monozygotic twin can die from blood loss through the umbilicus of the first-born twin if it is not tied up in due time.

As soon as the first twin has been delivered, the second one in the uterus is examined: its position is determined and the heart tones are listened. If the condition of the parturient permits, the position of the second foetus is longitudinal, and asphyxia is absent, the labour is allowed to pass by its natural pathway.

If the second foetus is not delivered in 20-30 minutes the membranes should be ruptured (with a slow release of the fluid) and the labour is again tried to follow its natural course.

If the second foetus is in the transverse position, it should be turned to present by its foot by which it is removed from the uterus.

In cases of asphyxia or bleeding from the birth canal, external rotation of the foetus and its extraction from the uterus should be done immediately, provided its head stands high; if the head is engaged or is at the pelvic outlet, obstetric forceps should be applied to end the delivery.

The third stage of labour requires special attention too. The condition of the puerpera should be carefully observed and the amount of blood lost accurately measured.

At the beginning of the last stage of labour the puerpera is given an intramuscular injection of 1 ml of pituitrin for prophylaxis of profuse bleeding. If however it fails and bleeding occurs, measures should immediately be taken to remove the placenta from the uterus. If there are signs of placental separation the placenta should be removed by external methods. If the placenta is not separated, while the haemorrhage is significant, the placenta should be separated manually, i.e. removed by the hand introduced into the uterine cavity.

The delivered placentas (placenta) should be carefully inspected to make sure that no remnants of the placenta remain in the uterus and to establish whether the twins are mono- or dizygotic.

The condition of the puerpera should be carefully observed during the first hours following delivery. The contraction of the uterus and the amount of blood discharged from the birth canal should be estimated.

Another pituitrin and ergometrine

injection can be given to the puerpera if the contraction of the uterus is slow, and a bag with ice should be placed on the abdomen. Whenever necessary the uterus can be massaged or other measures to stop bleeding should be taken (see Chapter 25).

The involution of the uterus during the puerperium is slower than after singleton birth. Lochia should therefore be examined with special care, and the state of the uterus and the general condition of the puerpera should be observed. If necessary, medicines promoting contraction of the uterus may be prescribed. Exercises are especially helpful. They strengthen the muscles of the abdominal wall and the pelvic floor.

Twins, especially premature ones, require special care.

Chapter Fifteen

TOXAEMIA OF PREGNANCY

Toxaemia of pregnancy is a series of pathological conditions occurring in a pregnant woman. As a rule these disturbances subside after termination of pregnancy. After childbirth (or an abortion), almost all symptoms of toxicosis are abated; long-term sequelae persist after grave and prolonged forms of these disturbances.

The aetiology of pregnancy toxaemia was explained by poisoning of the female body with various toxins the formation of which was also explained by various causes. Some authors maintained that the toxins were endogenic in character, i.e. produced by the woman herself, as a result of upset metabolism, while others insisted that the source of the toxins was the placenta. According to this latter concept the toxic substances were produced by the perverted placental functions or by penetration into the blood of the pregnant of chorion elements which were then split. According to another hypothesis toxaemia of pregnancy is a result of accumulation in the blood of the pregnant of the foetal metabolites, if they are not neutralized in the maternal body and are not excreted in due time (retention toxicosis).

Numerous attempts to isolate toxins from the pregnant with toxaemia have been unsuccessful. For this reason, the theories which try to explain the genesis of toxicosis by poisoning are ungrounded. The immunological theory of pregnancy toxaemia deserves consideration. According to this theory, the pathology arises as a result of increased sensitivity of the woman to foreign proteins which enter the pregnant from the conceptus (the foetus and the placenta).

Another hypothesis explains the toxicosis by the upset endocrine function. But the changes in the hormonal equilibrium that attend toxaemia of pregnancy are probably the effect rather than the cause.

The development of pregnancy toxaemia depends largely upon the functional characteristics of the female nervous system. Pregnancy imposes new load on the female body and the function of all organs and systems is therefore altered to evoke considerable shifts in the metabolism. These are physiological, or accommodative changes, and are favourable to the normal course of pregnancy and the development of the foetus. All these changes occur and develop under the control of the nervous system, and if the nervous system of the pregnant is affected, the adaptation reaction of the body is upset. The changes in the function of certain organs and systems thus become pathological, the metabolism is upset, and the response to various endogenic and exogenic stimuli changes. All these disturbances promote the development of toxaemia. The alteration of the function of the nervous system, and hence the

development of toxaemia are favoured by grave diseases of the past history, mal- or inadequate nutrition, improper personal hygiene, overstrain, and other factors that weaken the resistance of the female body. Late toxaemia of pregnancy is grave and often occurs in women with hypertension, diseases of the heart, kidneys, liver, endocrine glands (diabetes, thyrotoxicosis, etc.) and other organs and systems.

Toxaemia developing against the background of other diseases is known as combined toxicoses.

Toxicoses of pregnancy (*gestoses*) can be classified as follows:

1. Early pregnancy toxaemia: vomiting of pregnancy, incoercible vomiting, hypersalivation.
2. Late toxaemia: dropsy, nephropathy, pre-eclampsia, eclampsia.
3. Rare forms of toxaemia: diseases of the skin, liver (jaundice of pregnancy), nervous, bone and other systems.

Early Pregnancy Toxaemia

Vomiting of Pregnancy and Incoercible Vomiting

Vomiting of pregnancy (emesis gravidarum). During early months of pregnancy, many women, primigravida in particular, suffer from nausea and vomiting in the morning. Vomiting does not occur every day; nor does it affect the general condition of the woman. This cannot be classified as toxicosis. Toxaemia is characterized by vomiting that occurs several times a day (not only in the morning), and even after taking food. Vomiting is attended with nausea, absence of appetite, desire for salt and spicy foods. Despite vomiting, part of the food taken is retained in the stomach and the pregnant does not lose her weight. The pregnant complains of fatigue, irritability, sleepiness, sometimes of insomnia. The general condition of the pregnant is satisfactory, the temperature normal, the pulse may be slightly accelerated (to 90 per min). Vomiting of pregnancy occurs during the first 2 or 3 months; it is easy to treat or it may subside spontaneously. In rare cases vomiting intensifies to develop into incoercible vomiting.

Incoercible vomiting of pregnancy (hyperemesis gravidarum) is a grave condition, often attended with other symptoms which indicate disturbances in the vital body functions.

Vomiting attacks occur to twenty times (and over) a day, both during the day time and in the night. Neither food nor water is retained. Disgust for food develops. Vomiting is often attended with hypersalivation. The woman loses her weight. If vomiting persists, the woman may develop cachexia. The skin becomes dry and flaccid, the tongue coated, breath unpleasant. The temperature is subfebrile, the pulse accelerated to 100-120 beats per min, the arterial pressure drops, acetone and protein are found in the urine. The sleep of the patient is deranged, she becomes easily excited or apathic. In grave forms of the disease the body temperature is high, the skin is yellow, the pulse is fast and arrhythmic; delirium may develop. Incoercible vomiting requires timely treatment, otherwise the woman may die.

Treatment of vomiting of pregnancy. The patient should be hospitalized and conditions should be provided for her complete psychic and physical rest. Hospitalization alone can often improve the condition of the patient.

Proper care of the patient, rest, ade-

quate sleep, quieting talks with the doctor (who should persuade the patient that the vomiting will subside in further pregnancy) are very important for the treatment. The patient is given light and readily assimilable food to her taste (rusk, puree, tea, coffee, lean meat, fish, eggs, butter). The patient takes food in bed, in small portions at short intervals; cold food is often better assimilated by the patient.

If food is not assimilated, glucose is prescribed intravenously (30-50 ml of a 40 per cent solution) or it may be admixed to physiological saline solution, which is given by proctoclysis. Physiological saline solution (100 ml of a 40 per cent glucose per litre of physiological saline solution) is widely used to preclude dehydration and to promote the transport of nutrients. Proctoclysis should be given daily (1.5-2 litres of physiological solution and glucose).

Broth, milk, eggs, and other nutrient matter can be added to enema which is instilled at a rate of 60-80 drops per min (200-300 ml per hour). The condition of the patient will soon improve and common food can be taken as usual.

Vitamins (first of all vitamins C and B_1) are given intravenously with glucose (or per os).

If vomiting is severe, medicines should be given. Bromides are helpful (microenema of 50 ml of a 4 per cent solution of sodium bromide once a day).

N. V. Kobozeva suggests that bromine together with caffeine should be given. Sodium bromide should be given intravenously as a 10 per cent solution (10 ml daily), and 1 ml of a 10 per cent caffeine solution (twice a day subcutaneously). The injections should be given for 10 to 15 days.

To prolong nocturnal sleep, barbamyl (0.1-0.15 g) should be given two times a day; the course of treatment, 7 to 10 days. If vomiting is uncontrollable, barbamyl should be given as microenema (0.15-0.2 g per 30-40 ml of physiological saline solution). Luminal can also be given to improve sleep.

Calcium chloride (10 ml of a 10 per cent solution) given intravenously or as enema (one tablespoonful of a 10 per cent solution in 1/4 glass of water or milk) is helpful as well. Transfusions of small portions of blood (100-150 ml) are effective too.

Aminazine tablets or capsules (0.025 g of aminazine and 0.5 g of glucose, 2 or 3 times a day) or intravenous injections of 1 ml of 2.5 per cent solution with glucose once a day, or intramuscular injections of procaine hydrochloride solution would usually be effective to control vomiting.

Other preparations are also known, such as droperidol, etc.

Treatment is effective in most cases; if however vomiting cannot be stopped, the pregnancy should be terminated.

Hypersalivation

Hypersalivation (ptyalism) often attends vomiting or incoercible vomiting of pregnancy. It can however be an independent syndrome. The amount of secreted saliva can be as high as one litre a day.

Moderate hypersalivation does not affect the general condition of the pregnant, but if the secretion of the saliva is excessive the subjective condition of the patient is aggravated, insomnia develops, and the woman loses weight. Hypersalivation does not however evoke grave disturbances in the body and abortion is not required.

Hypersalivation can be treated in the

same way as vomiting: rest, bromides, hypnotics; food should be taken in small portions at short intervals; glucose should be given intravenously or as proctoclysis. If hypersalivation is grave, small doses of atropine (0.0005 g twice a day) are prescribed.

Toxaemia of Late Pregnancy

Late pregnancy toxaemia (dropsy, nephropathy, pre-eclampsia, eclampsia) are stages of development of one pathological process. The initial stage, dropsy, may develop into a more grave form, nephropathy, and nephropathy into pre-eclampsia. Eclampsia is usually preceded by pre-eclampsia or nephropathy.

Dropsy

Slight and readily subsiding postural oedema of the lower extremities during late weeks of pregnancy is not infrequent. It is not considered as toxaemia.

Dropsy of pregnancy (hydrops gravidarum) is characterized by more persistent oedema. The disease develops during the second half of pregnancy, actually in its late weeks. Postural oedema first develops, and then it turns into persistent oedema of feet and legs: further development of dropsy is characterized by oedema of the thighs and the external genitalia. Grave dropsy is marked by generalized oedema.

Since water is retained in the body, the pregnant rapidly gains in weight. Normal weekly gain is 250-300 grams while in oedema, the increase in weight is as high as 500-700 g and over. Oedema can be latent and the gain in weight can therefore be significant in the absence of marked signs of dropsy. Only systematic weighing will reveal hydrops in such cases. Liquid is mainly accumulated in subcutaneous cellular tissue and would not usually accumulate in serous cavities (abdominal, pleural, etc.).

Accumulation of fluids depends on the upset water-salt metabolism and increased capillary permeability. Tissues retain salts and fluids that are derived from the vessels with increased permeability.

Hydrops would not be usually attended with changes in the heart, liver, kidneys or other organs. Arterial pressure is normal; protein is absent from urine. With developing oedema, the amount of urine decreases. The general condition of the patient remains normal and only in grave oedema the pregnant complains of fatigue and the feeling of gravity.

Hydrops of pregnancy is a persistent condition; oedema may abate and then develop again. Bed rest and adequate diet will usually help, but when the woman returns to her normal life the disease recurs. Sometimes oedema abates spontaneously before labour, and in most women oedema subsides after childbirth.

If the patient does not follow recommendations of the physician, hydrops may transform into a more severe form of the disease, nephropathy of pregnancy.

The best prophylaxis of hydrops of pregnancy is personal hygiene, adequate nutrition, and normal way of life. Systematic observation of the pregnant will reveal in due time the developing disease. Weekly determination of the body weight is also very important.

Treatment of hydrops of pregnancy consists in imposing certain limitation on liquids (to 3 or 4 glasses a day) and food, which should contain no

salt. The diet should mainly consist of food containing carbohydrates and vitamins; curds, sour milk or yoghurt should be substituted for meat. When oedema subsides, boiled meat can be used again (in small quantity). If oedema is marked or persistent, the patient should be hospitalized.

Bed rest, limited intake of water and saltless diet are required in considerable oedema (until the symptoms subside). To lessen oedema ammonium chloride (0.2-0.3 g powder), hypothiazide, and other diuretics should be prescribed.

Nephropathy of Pregnancy

Nephropathy of pregnancy (nephropathia gravidarum) is characterized by the triad of symptoms: (1) oedema, (2) albuminuria, and (3) hypertension. Sometimes nephropathy is marked by the following three diads: hypertension and oedema, oedema and albuminuria, and hypertension and proteinuria. Nephropathy usually develops against the background of hydrops: oedema is attended with hypertension and albuminuria. The maximum arterial pressure exceeds 130 mm Hg. It can be as high as 150-180 mm and in severe hypertension, 200 mm Hg and over. The protein of urine varies from 0.1 to 5 or 6‰ and over; in severe nephropathy urine can contain urinary casts and the daily discharge of the urine decreases.

Hypertension is the most common component in the combinations of symptoms characteristic of nephropathy. It is due to the upset nervous regulation of the vascular function. Finest arterioles and arterial capillaries are affected by spasms, permeability of the capillary walls increases, the retention of fluids, salts, and seralbumins in the vessels and tissues is impaired to interfere with normal transport of oxygen to tissues and organs. Hypoxia may develop in severe nephropathy. The liver function is affected in grave nephropathy and this may evoke disturbances in the water-salt, protein and fat metabolism. The content of unoxidized metabolites will thus increase in the body.

Nephropathy occurs more frequently in primigravida. It usually develops in the late months of pregnancy and its course is protracted, often lasting till childbirth.

Nephropathy is dangerous to the woman because it can transform into eclampsia. The development of the foetus is often retarded in nephropathy and the stillbirth rate is rather high.

The best prophylaxis of nephropathy is normal way of life, adequate nutrition during pregnancy, timely detection and proper treatment of late toxicosis at the stage of hydrops. Regular urine tests for albumin, measurement of the arterial pressure and of the body weight are important for timely detection of nephropathy.

Patients with nephropathy shall be hospitalized. Each pregnant, however indistinct signs of nephropathy might be, should be placed in the department for pathological pregnancy. The patient is prescribed bed rest and strict diet containing little water and salt. If nephropathy is marked, salt is ruled out from the diet at all; the food contains mainly carbohydrates (porridges, stewed and fresh fruits, sugar, puree, etc.). Proteins are given only as curds, and boiled meat or fish (in limited amounts). If oedema and hypertension are significant, fasting diet (1-1.5 kg of apples with sugar) shall be prescribed. Vitamins C, A and B are recommended.

The condition of the patient is observed, the weight and the arterial pressure measured, daily diuresis is determined and the urine tested at 2-3 day intervals. The patient is kept in a warm and well-aired room; warm shower is recommended (if the condition of the patient permits, she is prescribed daily showers).

Magnesium sulphate (20 ml of a 25 per cent solution four times a day at 6-hour intervals intramuscularly in the course of one day) is prescribed. If necessary, the magnesium therapy is repeated in 2 or 3 days. This preparation decreases arterial pressure, intensifies diuresis (oedema decreases), lessens excitability of the nervous system. Glucose (25-30 ml of a 40 per cent solution) should be given intravenously (better with ascorbic acid). Calcium chloride (one tablespoonful of a 10 per cent solution three times a day) should be prescribed on days when magnesium sulphate is not given. Aminazine is an efficacious hypotensive preparation. It can be given per os, intravenously or intramuscularly. Magnesium sulphate (20-25 per cent solution, two times a day) and aminazine (1 ml of a 2.5 per cent solution intramuscularly once a day) are recommended. Aminazine can be given in combination with reserpine (0.1-0.25 mg per os; two or three times a day). Other preparations (dibazole, pentamine, etc.) can also be used. Diuretics are prescribed in oedema; decoction of motherwort and valerian root are given for deranged sleep (nembutal, noxyron, etc., before night sleep).

In the past years they resorted to phlebotomy in severe nephropathy but this method is not used today because the amount of circulating blood in grave nephropathy is often decreased and the body may develop a strong undesirable response to loss of blood.

Pre-eclampsia

If the pregnant does not adhere to the hygienic requirements of pregnancy, or else nephropathy is not treated properly, the disease may transform into pre-eclampsia.

The clinical picture of pre-eclampsia is characterized by oedema, hypertension and albuminuria, i.e. the triad typical of nephropathy. The gravity of these symptoms usually increases in the transition from nephropathy to pre-eclampsia. Hypertension, oedema and albuminuria are complemented with severe headache, scintillating scotoma (teichopsia), and epigastric pain. Vomiting, insomnia and irritability occur as well. Headache and scotoma are symptoms of deranged cerebral circulation. Depressed vision can also be the result of changes in the retina (oedema, haemorrhage, detachment). Circulatory disorders, renal and hepatic dysfunction, and upset metabolism are more pronounced in pre-eclampsia than in nephropathy; hypoxia becomes more intense.

Pre-eclampsia may at any moment convert into eclampsia. Haemorrhages into the vital organs may occur without the transition to eclampsia. Premature separation of the placenta and other complications of pregnancy which are dangerous to both the mother and the foetus may develop. Asphyxia of the foetus may cause its intrauterine death or the foetus may perish during labour.

Treatment. The patient should be hospitalized immediately. She should be placed in a separate room and a constant watch organized (the patient should not be left alone for a minute).

All sources of irritation, such as noise, bright light, pain, exciting emotions, should be removed.

Fruit juice alone (300-400 ml a day) or fruits (500-800 g) are given during the first day of her stay in hospital. No other food should be given. Glucose (30-40 ml of a 40 per cent solution) is given intravenously twice a day. Food lacking salt and restricted liquid are given in the next days. Magnesium therapy or aminazine (in combination with magnesium sulphate, reserpine, etc.) should be prescribed.

If headache persists, medicinal leeches (three leeches in the area of each mastoid process) can be used.

Diuretics are indicated in oedema. Sedatives are also useful.

If adequate therapy has been selected, the conversion of pre-eclampsia to eclampsia can be prevented and the condition of the woman can be so improved that her pregnancy will be preserved.

Eclampsia

Eclampsia is the highest stage of late toxaemia. It usually arises against the background of pre-eclampsia or nephropathy. This grave condition is characterized by some complicated symptoms indicating the impaired function of all vital systems and organs. The most pronounced symptom of eclampsia are convulsions of the body musculature which are followed by the state of unconsciousness (coma).

Eclampsia would usually occur during labour, less frequently during pregnancy. Sometimes attacks of eclampsia occur after childbirth. The incidence of the disease is higher in primigravida. The occurrence is slightly higher in multiple pregnancy, constricted pelvis, and in women with diseases of the kidneys and the vessels.

The *clinical picture* of eclampsia is characterized by attacks of convulsions which overlie the existing symptoms of pre-eclampsia or nephropathy. The attack is often preceded by intense headache, depression of vision, insomnia, restlessness, elevated arterial pressure, and protein in the urine. Each convulsion continues one or two minutes. The onset is usually heralded by twitching of the face, the eyelids are closed and the whites of the eyes can only be seen, the mouth angles are lowered. All muscles of the body become then involved: the body is strained, the respiration discontinues, the face becomes blue (tonic convulsions). Vigorous convulsions (clonic) of the face, body and the extremities then develop and continue 30-40 seconds. The convulsions gradually subside, coarse breathing is regained, and frothing of the mouth is observed (the patient bites her tongue if it is not protected). After the convulsions subside, the patient remains in a coma for a certain period of time, then she regains her consciousness slowly and is amnesic to the event. Sometimes the attack of convulsions recurs while the patient is in a coma. The number of such attacks varies from one or two to ten and over. Modern treatment usually succeeds in limiting the number of convulsions to one or three. The convulsions usually do not occur after childbirth. Proper treatment also succeeds in most cases to remove attacks of convulsions that may develop during pregnancy.

Eclampsia is characterized by severe derangement of the vital bodily functions. The function of the central nervous system is upset: its excitability increases sharply. In this connection, noise, bright light, etc., may provoke a new attack of eclampsia. Circulatory disorders are intensified, oedema of the

brain develops and haemorrhage into the brain, liver and other organs occurs. Oxygen deficiency increases and the metabolism becomes upset: unoxidized products of fat and protein metabolism are accumulated in the body. Dystrophic processes develop in the liver, kidneys and other organs, and their function is impaired. Urine is meagre and it contains much protein and urinary casts. The placenta is often affected by haemorrhage and other changes that cause foetal distress.

Eclampsia is dangerous to the mother and the foetus. The woman can die during its attack (even during the very first one) and after the attack subsides. The main cause of lethal outcomes in eclampsia is haemorrhage in the brain, asphyxia, cardiac failure, and oedema of the lungs. Secondary injuries may occur in the absence of timely medical aid: contusions, bone fractures, biting of the tongue. Aspiration pneumonia, renal dysfunction and psychoses sometimes develop on cessation of the attack.

Intrauterine asphyxia of the foetus is frequent in eclampsia. The stillbirth rate is also high. At the present time the death rate from eclampsia has sharply reduced, which is explained by improved prophylaxis and treatment of the disease.

Prophylaxis is the main measure to control eclampsia, and much attention is given to it at obstetrical institutions. The method is based on the following: (1) strict observation of hygienic and diet requirements during pregnancy; (2) regular and careful observation of the pregnant by the obstetrical personnel; (3) timely detection and adequate treatment of the preceding stages of late pregnancy toxaemia: hydrops of pregnancy, nephropathy, and pre-eclampsia. Appropriate treatment of these precursors will prevent the development of eclampsia.

Treatment of eclampsia. Various preparations, hormones, urgent delivery (both pelvic and abdominal) were tried, but none had been very much successful and the maternal and foetal mortality remained high enough.

The turn point in the history of treating eclampsia would be usually connected with the name of a prominent Russian obstetrician V. V. Stroganov who radically changed the clinical management and treatment of eclampsia. His practical methods became decisive in the changing attitude to urgent operative delivery and extreme conservatism in managing cases with eclampsia.

According to V. V. Stroganov, the *main danger of eclampsia are the attacks themselves and they should therefore be prevented by all possible means.* Keeping patients away from possible sources of excitation and giving them narcotics are the main principles of his method, which consists essentially in the following:

1. Removal of optical, auditory, and tactile stimuli; keeping the patient in a shaded and well-aired room isolated from any noise. All examinations, injections, catheterization and other procedures should be done with inhaled narcotics.
2. Attacks of eclampsia should be abated by morphine and chloral hydrate (0.015 g of morphine, then, an hour later, 2 g of chloral hydrate in an enema, then in three hours after the therapy has been started, 0.015 g of morphine again, in 7 hours 2 g of chloral hydrate, and in 13 and 21 hours 1.5 g of chloral hydrate, i.e. 0.03 g of morphine and 7 g of chloral hydrate during one day).
3. Accelerated but not urgent delivery (rupture of the membranes, forceps delivery, external version, and extraction of the foetus).
4. Maintaining normal cardiac and other vital functions of the body.

The Stroganov method has been widely used in this country and abroad to reduce the mortality rate 5-6 times.

During recent years the Stroganov method has been improved without deviating from

its main principles. Narcotics were first of all replaced by other preparations because some narcotics, along with their positive effects, have some adverse influence on the patient. Large doses of narcotics inhibit the central nervous system and when in the state of coma the patient's condition may even be aggravated. Morphine decreases the urinary discharge which is also an unfavourable condition in eclampsia. Chloroform and chloral hydrate may have an adverse effect on parenchymatous organs whose function is inhibited in eclampsia. Morphine and chloral hydrate were therefore (by suggestion of D. P. Brovkin) replaced by magnesium sulphate, and chloroform by ether. When used in small stunning doses for various manipulations ether is almost harmless, or at least its harm is much repaid by its positive effect. Morphine (1-1.5 ml of a 1 per cent solution) is only used before transportation of the patient to the hospital (if the attack occurs at home). The patient should then be brought to the lying-in hospital under the observation of an obstetrician.

Eclampsia is treated today as follows.

1. The sensor and motor centres of the brain are sharply excited in eclampsia, and various stimuli, such as bright light, noise, pain, etc., can provoke an attack of convulsions through the reflex pathways. The main therapeutic principle is therefore *absolute rest*, and the absence of optical, auditory, tactile or pain stimuli. Light ether anaesthesia should be given to the patient before her toilet on admission, before external and vaginal examinations, injections, catheterization, phlebotomy or other manipulations. The patient is kept in a shaded room where she is isolated from noise or other stimuli that might affect the patient adversely; the room shall be aired well. Special rooms for eclampsia patients should be provided by standard designs of lying-in hospitals.

2. The patient should be under an incessant observation of the obstetrician. Instructed by the physician the obstetrician gives the patient the necessary medical and hygienic treatment and also careful concern which is very important for the patient. The obstetrician should air the room, cover the patient with the blanket, turn her to the side, take care of cleanliness of her skin, the intestinal function, urination, measure the arterial pressure, give oxygen to breathe, wipe the froth from the mouth, etc.

3. When signs of the approaching attack develop (twitching of the face, eyelids), the obstetrician inserts a mouth dilator, a spatula or a haft of a spoon wrapped in gauze between the patient's molars to protect the tongue from biting. Steps should be taken to prevent the patient from injuries during the attack of convulsions. When the patient regains her breath, oxygen should be given until the cyanotic colour disappears from the face. The mouth should be wiped with a napkin to prevent penetration of the saliva into the airways.

4. 25 ml of a 25 per cent magnesium sulphate solution should be given intramuscularly at 6-hour intervals. The daily dose of magnesium sulphate should by no means exceed 25 g.

The favourable effect of magnesium sulphate depends on its ability to remove increased excitability of the central nervous system. The vasodilating effect of magnesium sulphate is no less important (it alleviates vascular spasms). Magnesium sulphate decreases arterial pressure and improves capillary circulation. The therapeutic effect of magnesium sulphate is finally connected with its diuretic properties.

These three therapeutic effects of magnesium sulphate (the ability to calm down the nervous system, to decrease arterial pressure, and to increase diu-

resis) account for the importance of this preparation in treating eclampsia.

Arfonad (given intravenously during labour) and viadril produce a good hypotensive effect. Aminazine is used instead of magnesium sulphate (usually 1 ml of 2.5 per cent solution with 40-60 ml of a 40 per cent glucose solution, one or two times a day intravenously, or with procaine hydrochloride solution intramuscularly). Aminazin reduces arterial pressure and removes increased excitability of the brain. Other spasmolytics are also used.

5. Phlebotomy was earlier used to decrease arterial pressure and to improve the general condition of the patient, but now it is not used because (1) a vasogenic shock may develop; (2) haematopoiesis decreases in eclampsia, and (3) it is difficult to predict the blood loss during forthcoming labour.

6. Intravenous administration of glucose is an important measure in eclampsia since it decreases intracranial pressure, increases diuresis, and improves nutrition of the myocardium. Glucose decreases acidosis and improves the capillary circulation. It is given in 30-50 ml doses (40 per cent solution) with ascorbic acid (0.2 g) two or three times a day.

Hypothiazid (dichlothiazide, esidrex), mannitol, lasix (furosemid) and other diuretics are used in the complex therapy of eclampsia (and pre-eclampsia). They remove excess liquid from the tissues and improve many vital functions of the body. Albumin, dry plasma solution, and other preparations should be given in marked hypoproteinaemia.

7. Lumbar puncture is sometimes used in the absence of therapeutic effect, but in most cases it becomes unnecessary after the therapeutic measures are taken.

8. Sparing methods should be resorted to in eclampsia (that develops during labour) in order to accelerate delivery. Early puncture of the membranes is recommended (the cervix is 2 or 3 fingers open). Obstetrical forceps, external version, and extraction by the pelvic end should be used. Caesarean section is rarely used and only for special indications when other measures have proved ineffective. Anuria, retinitis, or retinal detachment, premature separation of the placenta and other severe complications are indications for the caesarean operation in the absence of pelvic delivery.

Pregnancy is usually saved after the eclampsia attack subsides and in comparatively rare cases premature delivery is induced. Eclampsia that develops during labour should be treated by the same methods.

The therapy of eclampsia adopted in the Soviet Union improves the prognosis for both the mother and the foetus. Mortality from this disease has decreased ten times compared with that in the pre-Stroganov period. The incidence of severe eclampsia has decreased as well. The frequency of attacks was formerly 5 or 6 (and over) while in recent years cases with one or two attacks prevail. Cases with three and more attacks are comparatively rare.

The incidence of eclampsia has considerably decreased during the past decades in this country.

Women recovered from eclampsia require special care and observation. Arterial pressure should be measured daily after delivery and the urine tested at 2 or 3-day interval. The general condition of the puerpera, her cardiac function, the status of the respiratory system, and the involution of the sex-

ual organs are observed thoroughly. It is necessary to remember that sepsis, pneumonia and other complications of puerperium are possible.

Children born of mothers who suffered from eclampsia or other toxaemic disorders often have decreased resistance to infection, to temperature changes or other unfavourable effects of the environment. These neonates therefore require special care and observation as well.

The puerpera and the infant should be observed also after their discharge from the hospital. It should be borne in mind that the arterial pressure may remain increased in the puerpera for comparatively long periods and that headache and renal dysfunction, which developed in eclampsia, may also persist over post partum.

Rare Forms of Pregnancy Toxaemia

Diseases of the Skin

There are several skin disorders that develop in pregnancy and subside after childbirth. These conditions are manifested as itching, less frequent as eczema, nettle rash, erythema, and herpes.

Itching may develop at the beginning and the end of pregnancy, the symptom being localized to the external genitalia, or spread over the entire body. Itching is often intense and causes insomnia, depression, and irritability.

Dermatoses are treated by the regulation of nervous function and metabolism (bromides, barbiturates, calcium chloride, vitamins), adequate nutrition (decreased intake of proteins and fats) and reasonable way of life (adequate rest, normal alternation of sleep and wakefulness, etc.).

Jaundice of Pregnancy

Jaundice developing during pregnancy can be a symptom of various diseases or pregnancy toxaemia. It can be the symptom of epidemic hepatitis, diseases of the liver and bile ducts (cholelithiasis, etc.), and of the toxicosis. Jaundice may occur in incoercible vomiting and eclampsia due to the related liver affection. Jaundice as an independent toxaemic syndrome, characterized by predominant affection of the liver, is comparatively rare. It may occur in the first and the second half of pregnancy. Jaundice is often attended with itching, sometimes with vomiting. Jaundice may persist over considerable periods of time (weeks or months) and will only subside completely after delivery or abortion. It is supposed that hepatic insufficiency due to epidemic hepatitis or other diseases in past history may predispose to the development of jaundice. Jaundice of pregnancy is an alarming sign of hepatic dysfunction. The patient should be hospitalized immediately and the causes of jaundice cleared out. Infectious hepatitis requires special treatment. Jaundice of pregnancy is treated by the same methods as hepatitis and hepatocholecystitis. An abortion is sometimes necessary.

Acute yellow atrophy of the liver is very rare. This disease may develop in connection with incoercible vomiting or independently. The disease is characterized by progressive dystrophy of the liver and the sharp reduction of its size, development of necroses, and atrophy. The disease is very grave (marked jaundice, itching, vomiting,

convulsions, coma) and would usually end fatally. An abortion is indicated but it rarely improves prognosis because of grave affection of the liver parenchyma.

Tetany, bronchial asthma, anaemia and other diseases of pregnancy were formerly classified as toxaemia. But these diseases, as well as disorders of the nervous system (and psyche), which occur during pregnancy for the first time, are not toxaemia and occur in both pregnant and non-pregnant women. Pregnancy only exacerbates obliterated forms of some pathological processes because of the changed functions of some organs and systems and altered reactivity of the body.

Chapter Sixteen

DISEASES AND ABNORMAL DEVELOPMENT OF INTRAUTERINE FOETUS, FOETAL MEMBRANES AND PLACENTA

The causes of abnormal development of the foetus, placenta and the foetal membranes are not clear. The information available suggests that foetal abnormalities might be due to unfavourable environmental conditions which have their effect on the intrauterine conceptus. Defects of growth may arise through hereditary pathways or as a result of the damaging effect of the harmful factors on the parent sex cells.

The normal development of the embryo can be affected by many factors, such as infectious diseases and intoxications of the mother, in diseases that are attended with oxygen deficiency, elevated body temperature, X-rays, harmful chemicals, etc.

The normal growth of the foetus can be upset by poisoning with alcohol, nicotine, pharmaceutical preparations (especially taken by the pregnant without prescription of the doctor), as a result of infection with pathogenic microbes and viruses. The embryo is especially sensitive to these unfavourable effects at its early stage of growth (during early weeks of pregnancy). The defects of growth may be very significant and incompatible with foetus life so that it perishes before or soon after delivery. Sometimes only separate organs or parts of the body may be affected (malformations of the lip, fingers, sexual organs, etc.) which do not interfere with the development of the newborn.

Defects of Foetal Growth, Post-Term Delivery, and Intrauterine Foetal Death

Hydrocephalus. This is the hydrops of the head (Fig. 194). It arises due to abnormal accumulation of fluid in the cranial vault. The amount of liquid accumulated is in certain cases as high as two or three litres. Cases with marked hydrocephalus are rare.

As the liquid is accumulated, the head increases in size, the skull bones are separated to widen the sutures; the fontanelles become large, the bones soften and thin, and the brain undergoes atrophy under the thrust of the liquid. The cephalopelvic disproportion is a frequent result of hydrocephalus. The enlarged head is constricted in the pelvic inlet, the lower uterine segment undergoes excessive distension, and the danger of rupture of the uterus arises. Hydrocephalus is diagnosed by outer and vaginal examinations. External examination reveals abnormal size of the head which does not engage in the pelvis. Vaginal examination during labour shows extraordinarily wide sutures, large fontanelles, thin and flexible skull bones.

As soon as the diagnosis has been verified, the head of the foetus is punctured by a trocar or a long needle to release the fluid from the head (provided the cervix has opened enough). This decreases the size of the foetal head and labour can thus be completed

Fig. 194. Hydrocephalus

spontaneously. In the presence of indications for accelerated delivery (uterine atony, elevated temperature, etc.) the foetus is extracted using a cranioclast.

Anencephalia. This developmental anomaly is characterized by the absence of the cranial vault and of the major part of the brain; the face however is developed. The small head is mounted directly upon the shoulders, and the eyes are protruded (frog head). Anencephalus (Fig. 195) is usually born dead, or perishes soon after birth. Labour would usually be normal.

Fig. 195. Anencephalus

Encephalocele. This is the hernia of the brain manifested by protrusion of the brain through the anterior fontanelle, the occiput or the nose bridge. Labour is usually uneventful and the foetus can be delivered alive but would normally die post partum.

Cleft palate. The upper lip, the hard palate and the maxilla are cleft to communicate the mouth and the nasal cavities. As the infant sucks milk it flows out from nose, and the baby should therefore be kept in the vertical position during nursing to facilitate milk entrance into the oesophagus.

Hare-lip. This is the fissure of the upper lip. The anomaly does not interfere with sucking or normal growth of the baby.

Cleft palate and hare-lip can be corrected by plastic surgery. The operation is performed in few months after birth or even later (during the first years of life).

Hare-lip is corrected by plastic surgery during early postnatal period at some obstetrical institutions.

Spina bifida is the anomaly characterized by a defect in the bony encasement of the spinal cord (mostly in the lumbar region). The spinal cord can protrude through an opening in the spinal canal, being thus protected only by membranes and thinned skin. This anomaly usually does not interfere with normal labour.

Umbilical hernia may be of various size. If the defect in the abdominal wall is large, a considerable part of the bowel (including the liver and omentum) may protrude through the umbilicus. Even large umbilical hernia will not interfere with normal labour. Small hernias are corrected surgically, while

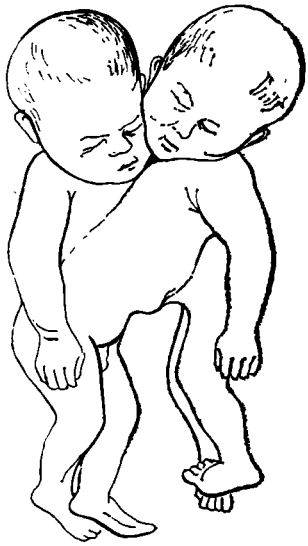

Fig. 196. Conjoined twins (sternodymus)

large hernias often become the cause of foetal death.

Imperforate anus. This is a grave condition and will cause death unless the infant is not operated. This defect is revealed by a thorough examination of the newborn in the delivery room and careful observation of the intestinal function of the neonate during its first day of life.

Polydactylia is a developmental anomaly characterized by the presence of supernumerary digits (fingers or toes) on the hands or feet, which are often underdeveloped.

Conjoined twins. Monozygotic monoamniotic twins may be delivered united by various parts of their body. Twins may be united by their heads, chests, abdomen (Fig. 196) or buttocks. Incomplete splitting of the germ results in the development of monsters characterized by doubling of various parts of the body (two heads upon one body, two bodies with one head, etc.). Conjoined twins cannot be delivered spontaneously and surgery is required.

Twins conjoined by their heads or pelvis can be born spontaneously.

Among other developmental defects may be cyclopia (single orbital fossa), defects of ears, extremities (phocomelia or sirenomelus), of the sexual organs, cardiovascular system, etc.

Giant foetus. Foetuses weighing over 5000 g are called gigantic. These are usually post-term infants, but giants born at term also occur. Giant foetus usually develops in women with diabetes, pre-diabetes, and other diseases. Delivery of a giant foetus is prolonged, often attended with asphyxia and labour injuries.

The obstacle to normal labour is the head, though the shoulders and the body itself are also difficult to deliver.

Post-term foetus. Pregnancy that lasts more than 14 days over full term is called postmature. The foetus is usually large, the bones of its skull are firm, and its moulding becomes difficult.

Cheesy varnish is absent from a postmature foetus, and signs of maceration can be seen on the skin. It should be remembered that the weight of a post-term infant may be normal.

Regressive changes occur in protracted pregnancy, which are responsible for the disturbances in the oxygen transport to the foetus. As a result, the foetus may perish from intrauterine asphyxia or during labour. Complications dangerous to the mother and the foetus often arise during labour. Infants are often born with injuries. Women with postmature pregnancy should be delivered to the lying-in hospital where labour should be induced artificially.

Erythroblastosis Fetalis. Haemolytic Disease of the Foetus and Newborn

The antigen, known as rhesus factor (Rh factor), is contained in most (85 per cent) people. Rhesus negative blood occurs in about 15 per cent people.

If a woman with a negative Rh factor is fertilized by a man with 'positive' blood, the foetus will in most cases inherit the father's positive blood. Rh factor will pass into the mother through the placenta in this case. Rhesus antibodies often develop in the woman in response to the entrance of the positive Rh factor. As the antibodies pass from the mother to the foetus, they cause erythroblastosis and evoke the haemolytic disease. The incidence of antibodies in women with negative Rh factor is lower in primigravida than in multigravida. Formation of the antibodies is promoted by blood transfusion and abortions. When antibodies are formed in the mother with negative Rh factor the foetus develops haemolytic disease which is manifested by jaundice, anaemia and oedema of tissues. Mild forms of the disease may manifest in anaemia and jaundice alone (sometimes only one of these components); grave forms are characterized by the presence of all signs, oedema included. The grave form of the disease is attended also with enlargement of the liver and the spleen, icteric staining of the subcortical nuclei of the brain, oedema of the brain, ascites and hydrothorax.

The foetus is born dead in grave forms of the disease or it is delivered in a critical condition. The symptoms are indistinct in mild forms of the disease, but the foetus will perish due to the continuing haemolysis of erythrocytes, anaemia and jaundice provided it is not given adequate treatment.

Treatment of haemolytic disease of the newborn comprises transfusion of blood, intravenous administration of plasma, and neocompensan; vitamins, prednisolone and other drugs are also given for special indications.

Special gamma globulin is given to the woman for prophylaxis of haemolytic disease of the foetus in subsequent pregnancies. Tests for the presence of Rh factor should be carried out during pregnancy. 'Negative' women should be observed and treated in a specialized lying-in hospital.

Infectious diseases of the mother are a danger to the foetus because of possible penetration of the microbes and viruses to the foetus through the placenta. The infection may cause disorders in the development of the foetus and its intrauterine death.

Intrauterine death. The foetus can die in the uterus from various causes which upset its normal growth. Among these are infectious diseases of pregnancy (typhus, dysentery, influenza, and other viral diseases, toxoplasmosis, listeriosis, syphilis, malaria, etc.), grave diseases of the cardiovascular system (hypertension, cardiac decompensation), severe pregnancy toxaemia (nephropathy, pre-eclampsia, eclampsia) and kidney diseases. The foetus can die from poisoning of the mother (with mercury, lead, carbon monoxide, etc.), from anomalies that are incompatible with life, from true umbilical knot, and separation of the placenta. Rhesus incompatibility of the blood of the mother and the foetus may also become the cause of intrauterine death or severe diseases of the newborn.

All women who had spontaneous abortions and premature labour, stillbirths of obscure aetiology, and neonatal deaths from severe jaundice should have their blood tested for Rh

antigen, syphilis, toxoplasmosis, listeriosis, and other infections.

Intrauterine death of the foetus can be diagnosed by the following signs:

1. Foetal heart tones are not heard and its motion is not detected.
2. The uterus stops growing. If the dead foetus is not delivered, the amniotic fluid is gradually absorbed, the uterus diminishes in size and becomes compacted (missed abortion).
3. The breasts stop engorging; the woman feels abdominal discomfort, indisposition, and fatigue. The general condition of the woman may however remain unchanged.
4. The oestriol content of the urine falls abruptly and the bioelectrical activity of the foetal heart (ECG) is absent.

The dead foetus is expelled from the uterus soon after its death or may be retained for more or less long periods. Sometimes the delivery of the dead foetus is delayed to the time of full term. The dead foetus retained in the uterus undergoes various changes.

Maceration of the dead foetus occurs most frequently. This is the degenerative softening of dead foetal tissues; they become soaked with the amniotic fluid and the blood serum. Vesicles are first formed on the skin; the skin then falls off in strips. The foetus becomes flaccid, the bones of its skull become easily movable and the tissues acquire a yellowish tint.

Mummification is drying up of a dead foetus. The incidence is significantly less frequent. Mummification occurs after the death of either of the twins. In rare cases it develops due to the umbilical entanglement. The amniotic fluid is absorbed, the foetal body shrinks, or is compressed (foetus compressus).

In exceptionally rare cases the dead foetus is *petrified* (through deposition of salts in the tissues of the dead foetus).

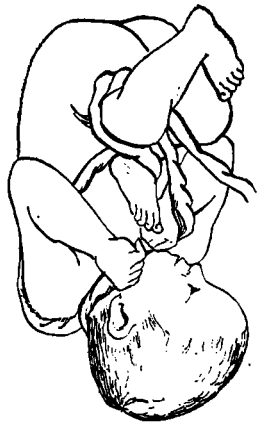

Fig. 197. Entanglement of the umbilical cord (the cord is wound round the neck and the extremities)

Prophylaxis of intrauterine foetal death is an important duty of the physician and obstetrician.

Prophylaxis of prenatal death is based on strict observation of hygiene of pregnancy, adequate nutrition, protection of the pregnant from infection and other diseases. Timely revealing of pregnancy toxaemia, diseases of the cardiovascular and other systems with subsequent proper treatment at hospitals is very important for the prophylaxis of foetal death.

Prevention of foetal death during labour depends on careful observation of the parturient and the foetus, timely detection of possible complications, and rendering adequate medical aid. Prophylaxis of intrauterine asphyxia is very important as well.

Anomalies of the Umbilicus

The average length of the umbilical cord of a foetus at term is 50 cm, but shorter or longer cords also occur.

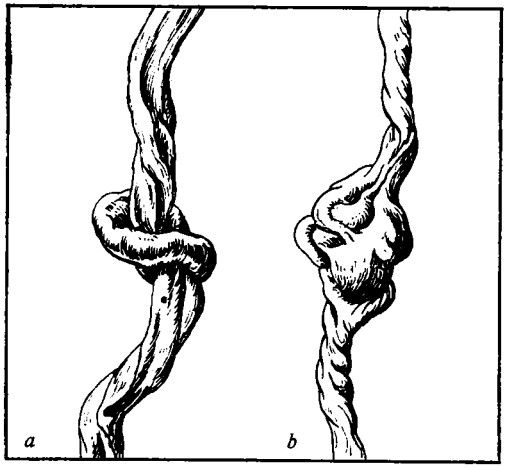

Fig. 198. Umbilical knots:
a — true knot, *b* — false knot

A *long umbilical cord* would not usually interfere with normal labour but it often forms loops around the neck, trunk or the extremities (Fig. 197). The cord can thus be tensed during the expulsive stage of labour, the lumen of its vessels is narrowed and asphyxia develops. A long umbilical cord can prolapse during the escape of amniotic fluid if the head is not engaged. The prolapsed umbilical cord will be compressed in the vagina by the presenting part and the foetus will die of asphyxia if timely aid is not given.

Shortness of the umbilical cord may be conventional or absolute. An absolutely short umbilical cord is less than 40 cm in length. A conventionally short cord is actually of normal length but entangled, or coiled around the neck or other part of the body. Too short umbilical cord interferes with normal movements of the foetus and can cause malpresentation. During the second stage of labour the short umbilical cord becomes tense and this will slow down the progress of the foetus in the birth canal or cause premature separation of the placenta.

Fig. 199. Marginal insertion of the umbilical cord

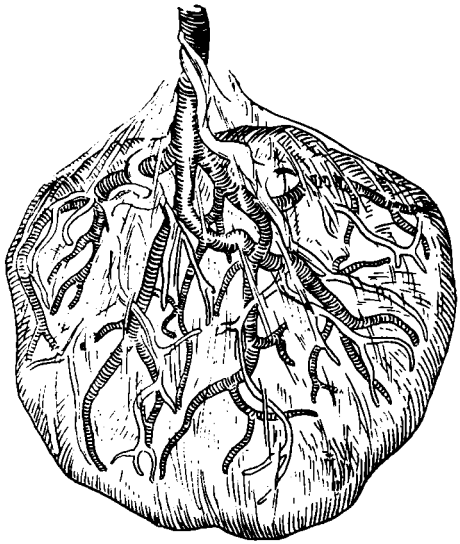

Fig. 200. Membranous (velamentous) insertion of the umbilical cord

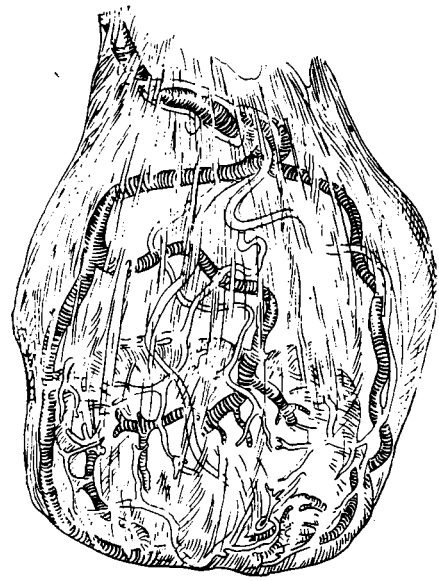

True knots of the umbilical cord (Fig. 198, *a*) occur in rare cases. They are formed at early pregnancy when a small foetus passes through the loop of the cord. If the knot is not tight, the foetus is born alive. The knot can however tighten during pregnancy or labour and the foetus will then die of asphyxia.

Knots may also be false (Fig. 198, *b*). These are enlargements on the umbilical cord formed by varicose dilation of the umbilical vein or due to accumulation of Wharton's jelly. False knots have no effect on the foetus.

The insertion of the umbilical cord into the placenta is usually central or lateral. Marginal insertion is not frequent (Fig. 199). Sometimes the umbilical cord inserts into the membranes at a certain distance from the placental margin which is called *membranous or velamentous insertion of the cord* (Fig. 200). The umbilical vessels with this insertion pass to the placenta in the space between the amnion and the chorion. If this portion of the membranes is in the lower segment of the uterus, it can rupture during labour and blood will discharge from the broken umbilical vessels to endanger the intrauterine foetus.

Diseases of the Foetal Membranes

Hydatidiform Mole (mola hydatidosa)

The disease is characterized by proliferation of the chorionic villi which turn into vesicles filled with a clear fluid. The vesicles are held by stalks and measure from a millet grain to the size of a cherry. The vesicles form grape-like accumulations.

When the chorion transforms into the mole, the villial epithelium (syncytium and cytotrophoblast) proliferates and the villial stroma becomes oedematous. The vesicles grow into the decidual membrane which becomes thin. The blood vessels of the decidual membrane often disintegrate and blood is discharged from them into the tissues surrounding the vesicles.

Sometimes the vesicles grow through the decidua to penetrate the myometrium and destroy the uterine walls with penetration into the abdominal cavity. The destructive form of hydatidiform mole occurs rarely (Fig. 201).

Complete and partial hydatidiform moles are distinguished. *Complete hydatidiform mole* is characterized by the degeneration of all chorionic villi, which occurs mostly in early months of pregnancy when the placenta has not yet formed completely. *Partial hydatidiform mole* develops at later terms and is characterized by that only part of the villi degenerate into vesicles.

Fig. 201. Hydatidiform mole (destructive form)

In the former case the foetus always dies, disintegrates and resorbs. In partial hydatidiform mole the foetus would usually die as well. It will only survive if a small area of the placenta is degenerated; such cases are however very rare.

After death of the foetus the hydatidiform mole continues growing and the size of the uterus increases rapidly. Cysts are often formed in the ovaries which develop from the corpus luteum. These cysts usually undergo regression after removal of the hydatidiform mole.

The clinical signs of hydatidiform mole are as follows:

1. A discrepancy between the size of the uterus and the gestation age: the uterus is much larger than in normal pregnancy of the appropriate term (the size of the uterus at the third month of pregnancy corresponds to the size of the uterus at its 4th or 5th month of gestation). The uterus is firm and elastic.

2. The absence of positive signs of pregnancy: parts of the foetus cannot be palpated, the heart tones are not heard, foetal quickening is absent.

3. Uterine bleeding is the most important sign of hydatidiform mole. The bleeding begins in the early weeks of pregnancy and continues for months (with alternation of increasing and diminishing intensity) till the mole is born. The blood is liquid and dark; sometimes it contains the vesicles. The bleeding is normally not profuse, but usually intensified during delivery of the mole.

4. The course of the disease is often aggravated by toxaemia of pregnancy (vomiting, oedema, nephropathy). Anaemia may develop due to lengthy bleeding.

The mole can be delivered spontaneously on the fifth or sixth month of pregnancy; sometimes the delivery is delayed to the tenth month and even longer. The hydatidiform mole is separated from the uterine walls, and is expelled from the uterus by its contractions. In destructive form of the disease fatal bleeding may develop. Another danger of the mole is that a malignant tumour (chorioepithelioma) sometimes develops. The tumour develops rapidly with metastases into remote organs.

Diagnosis of hydatidiform mole is established by the clinical signs described. Another diagnostic sign can be obtained by the Aschheim-Zondek test. Much gonadotropin is formed in women with hydatidiform mole and the Aschheim-Zondek test is therefore positive when dilute urine is administered to mice. When hydatidiform mole has been diagnosed or only suspected, the woman should be hospitalized.

If bleeding is not intense, delivery of the hydatidiform mole is stimulated medically.

To accelerate separation and expulsion of the mole, the woman is given oxytocin, pituitrin, and other drugs stimulating uterine contractions. If bleeding is profuse and the cervical os is opened wide enough, the mole is extracted by one or two fingers introduced into the uterine cavity. If bleeding is intense but the cervix is closed, the endocervical canal should be dilated surgically and the mole removed by the finger or a vacuum excochleator.

Curetting a uterus with mole is dangerous because the thinned uterine wall can be perforated. Only if bleeding is profuse and the cervical os does not pass a finger, the mole can be removed carefully by a blunted curette.

After delivery of the mole, when the uterus contracts and the danger of its perforation lessens, test curettage can

be performed to remove the retained parts of the hydatidiform mole.

After removal of the mole the woman should be observed systematically during 12 to 18 months so that the development of chorioepithelioma should not be overlooked.

Chorioepithelioma

Chorioepithelioma is a malignant tumour rapidly developing from chorionic cells. Macroscopically chorioepithelioma consists of bluish-red nodules or a diffuse proliferation in the uterine wall.

The tumour is located on the vessels and its particles are therefore carried by the blood to other organs of the body. Metastases of chorioepithelioma develop in the lungs, the vagina, the brain, the liver, the intestine, and other organs.

Chorioepithelioma features rapid metastasizing.

The clinical picture of chorioepithelioma is characterized by acyclic bleeding (or purulent discharge) immediately following the emptying of the uterus, or somewhat later. The uterus increases in size and becomes nodular. Anaemia develops which is attended with elevated temperature, coughing, bloody expectoration (metastases into the lungs), and other disorders associated with metastasizing into various organs. Metastasis in the vagina is blue-red.

The Aschheim-Zondek test should regularly be carried out for timely revealing chorioepithelioma. The Aschheim-Zondek test and the immunological reaction become positive in chorioepithelioma.

Polyhydramnios

Polyhydramnios is characterized by the abnormal accumulation of the amniotic fluid. (The normal amount of the amniotic fluid at term is one litre, with variation from 0.5 to 1.5 litre.)

In polyhydramnios the amount of the fluid is as large as 3-5, and sometimes even 10 to 12 litres and over.

The cause of polyhydramnios is not yet clear, but it is supposed that this anomaly is connected with the impaired function of the amnionic epithelium.

Polyhydramnios often attends multiple pregnancy, anomalies of the foetus, and some diseases of the mother, such as diabetes mellitus and nephritis. Polyhydramnios of one foetus is often concurrent with oligohydramnios of the other twin in multiple pregnancy.

Polyhydramnios usually develops in the middle or in the second half of pregnancy.

Acute and chronic polyhydramnios are distinguished. Acute polyhydramnios develops rapidly while chronic gradually. Acute polyhydramnios occurs less frequently than chronic.

Polyhydramnios promotes the development of some complications of pregnancy and labour.

Abnormal accumulation of the amniotic fluid sharply increases the size of the uterus which compresses the adjacent organs and lifts the diaphragm. The pregnant develops dyspnoea, fatigue, oedema of the lower extremities, pain and the feeling of gravity in the abdomen; pregnancy toxaemia frequently occurs.

High mobility of the foetus in polyhydramnios often causes malpresentations of the foetus (breech, transverse, oblique).

Pregnancy often ends prematurely in polyhydramnios. Labour would be prolonged and attended with atony. Smaller parts of the foetus often prolapse with the discharge of the amniotic fluid (the umbilical cord, in particular).

Bleeding is not infrequent in the placental and the puerperal periods.

The diagnosis of polyhydramnios is based on the following signs: the size of the uterus is exaggerated and its consistency is firm and elastic. The girth of the abdomen at the level of the navel is over 100 cm (110-120 cm and over).

In connection with the abnormal accumulation of the amniotic fluid the parts of the foetus are palpable with difficulty, the heart tones are dull or are not heard at all. The vaginal examination during labour shows that the membranes are highly strained not only during the contractions but also in the pauses.

Pregnant with polyhydramnios should be hospitalized.

In cases with acute polyhydramnios attended with disordered respiration and blood circulation, the membranes should be punctured artificially before labour. Surgery is not indicated in chronic polyhydramnios during pregnancy. Labour should be conducted under the supervision of a doctor because various complications of labour are likely to develop (uterine atony, prolapse of the umbilicus, foetal malpresentation, bleeding, etc.).

During the first stage of labour it is recommended to puncture the membranes when the cèrvical os opens 2 or 3 fingers (the membranes should be better punctured not at the centre but at the side) and to release the fluid slowly, without removing the operating hand from the vagina (to prevent the prolapse of the umbilicus). In cases of malpresentation, the foetus should be turned to present by its leg.

Oligohydramnios

Oligohydramnios occurs less frequently than polyhydramnios. It is considered to arise due to the decreased secretory function of the amnionic epithelium.

The uterus is small in pregnant with oligohydramnios. The developing foetus is in a tight contact with the amnion and the uterine walls. This imposes difficulties to the normal growth of the foetus.

Marked oligohydramnios becomes the cause of abnormal development of the foetus (deviation in the straight line of the spine, curved legs and arms, club foot, adhesion of various parts of the foetal skin to the amnion). The adhered skin is often distended to form bands and threads (Simonart's threads) that may wind round the extremities, the umbilical cord, or other parts of the foetus. Prolonged compression of the arms, legs, or the fingers of the foetus by the Simonart threads will interfere with normal nutrient supply to these parts and will require the amputation of the affected limb or part. When the umbilical cord is thus involved, the foetus perishes in the uterus.

Labour is prolonged with oligohydramnios and uterine contractions are extremely painful. To accelerate labour it is necessary to puncture the membranes without waiting for the cervical os to open completely.

Amnionic hydrorrhoea is characterized by a periodic or intermittent discharge of the amniotic fluid during pregnancy due to the rupture of the membranes above the level of the internal os. Pregnancy usually terminates prematurely and the foetus often has curved extremities or the trunk.

Untimely Rupture of the Foetal Membranes

If labour is normal, the membranes are ruptured when the cervical os is

completely or almost completely opened. The membranes act as a hydrostatic dilator to facilitate opening of the cervix. The rupture of the membranes in due time is favourable for normal labour and the intrauterine foetus.

Premature and Early Rupture of the Membranes

The rupture of the membranes before the onset of regular contractions is called premature. If the membranes are ruptured with the onset of labour before the cervical os is completely (or almost completely) opened, the rupture is called early.

The rupture of the membranes is often premature or early (with premature or early escape of the amniotic fluid) when the presenting part does not engage in the pelvic inlet. The presenting part does not form the engagement ring and the amniotic fluid is not separated. This occurs in contracted pelvis, in transverse, oblique, and breech (especially footling) presentations and in polyhydramnios.

The amniotic fluid may escape prematurely or early if the cervix is rigid while the membranes themselves are not strong enough (decreased elasticity). Premature and early escape of the amniotic fluid is a serious complication of labour. The first stage of labour (dilation) is usually prolonged, the contractions are painful, and the uterine atony often develops. If the amniotic fluid escapes the uterus in the absence of the engagement ring, smaller parts of the foetal body may prolapse (umbilicus, in particular). The uterine cavity freely communicates with the vagina for a long period which increases the danger of infection. Endometritis of labour therefore easily develops in prolonged dry period which is attended with elevated temperature, accelerated pulse, and appearance of turbid vaginal discharge.

Intrauterine asphyxia of the foetus often occurs in premature and early escape of the amniotic fluid.

Premature and early escape of the amniotic fluid is an indication for immediate transportation of the parturient to the lying-in hospital. Steps should be taken to prevent infection and asphyxia of the foetus.

If the uterus does not begin contracting in 6 to 8 hours after the discharge of the amniotic fluid, steps should be taken to stimulate the uterus. If the contractions are weak, the uterine contractility should be intensified and anaesthetics should be given if the contractions are painful.

Delayed Rupture of the Membranes

If the cervical os is open completely and the expulsive stage begins with intact foetal membranes, their rupture will be called delayed. The causes of this complication are excessive strength or, on the contrary, excessive distensibility of the membranes, which interferes with their timely rupture. Sometimes the delay depends on the meagre amount of the forewaters when the foetal membranes are near the foetal head or even come in a tight contact with it.

The labour is prolonged with delayed rupture of the membranes, the uterine contractions are painful, and the progress of the presenting part is slow.

As soon as it has been established that the membranes are intact with complete opening of the cervical os, the membranes should be ruptured artificially. The tense membranes should be

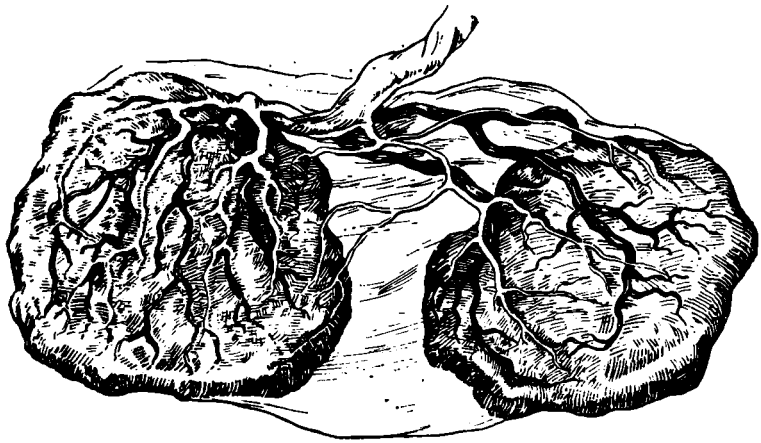

Fig. 202. Bilobed placenta

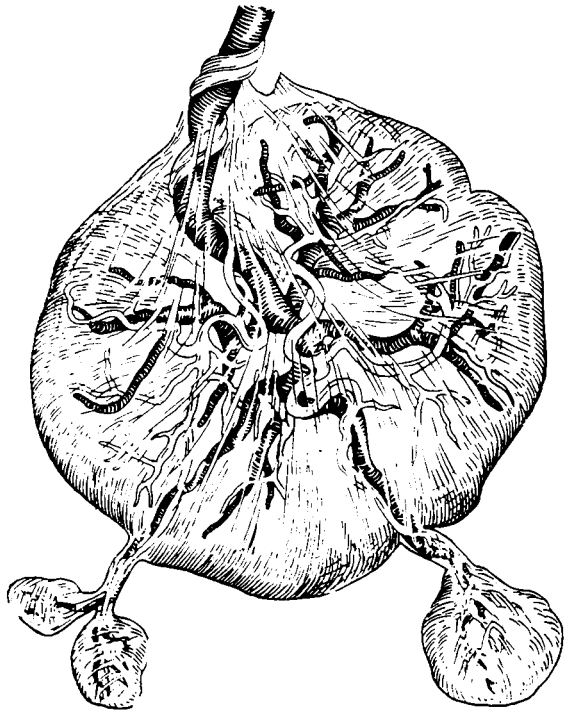

Fig. 203. Placenta with accessory lobes

pierced through with a finger (or two fingers). Long dressing or bullet forceps can be used for the purpose as well. If the presenting part is not engaged in the pelvic inlet, the gush of the amniotic fluid should be slowed down.

If the foetal membranes protrude from the pudendal cleft they can be ruptured by the finger; the head usually begins crowning soon after that.

If the infant is delivered wrapped in membranes (caul) they should immediately be removed from the baby, especially from its head to open the airways and thus to prevent asphyxia.

Anomalies of Placenta

The placenta would normally be round or oval. Sometimes it is prolonged, bean-shaped, or it may consist of two lobes (placenta bipartita) (Fig. 202). The placenta may consist of several parts interconnected by the vessels. The placenta may be abnormally thin and spread out over a large area of the uterine wall (placenta membranacea). Sometimes one or more accessory portions are attached to the main placenta (placenta succenturiata) (Fig. 203). They are located at a distance from the placental margin and are attached to it by arteries and veins which pass between the membranes. The accessory portions of the placenta may be retained in the uterus during the delivery and may thus become the cause of postpartum bleeding and puerperal sepsis. When the placenta is delivered, it should therefore be checked thoroughly for the absence of broken blood vessels; the presence of such vessels indicates that an accessory lobe of the placenta is retained in the uterus and it should immediately be removed manually.

In rare cases the placenta may be trimmed with a whitish margin from which the membranes extend.

The shape of the placenta depends on the site of its attachment and the condition of the uterine mucosa.

The attachment of the placenta in the tubal angles, or affection of the endometrium by dystrophic or inflammatory processes evokes abnormalities in the placenta.

Placental infarcts arise as a result of disordered blood circulation and necrosis of the villi. The changes are followed by the deposition of fibrin. Infarcts are whitish rounded plaques, sizing 15-20 mm, located on the foetal and maternal surfaces of the placenta. Infarcts may sometimes be of considerable size and pass through the entire depth of the placenta. Large infarcts often occur in nephritis and pregnancy toxaemia. Small infarcts have no effect on the foetus, while large infarcts, covering considerable areas of the placenta, can become the cause of abnormal development of the foetus and even its intrauterine death.

White firm spots can often be seen on the maternal surface of the placenta of full-term infants. These are calcium salt depositions in the degraded villi. They have no appreciable effect on the growth of the intrauterine foetus either.

Adherence of Placenta

Normally the villi grow into the compact layer of the decidual membrane without reaching the spongious layer of the endometrium or myometrium. The placenta is easily separated after delivery of the foetus at the spongiosum layer. But in some cases the adherence of the placenta to the uterine wall is more intimate.

False and true adherence of the placenta are distinguished. In *false adherence* (adherent placenta) the villi grow into the endometrium but do not reach the myometrium, and the placenta can be separated by hand.

In *true adherence* of the placenta (placenta accreta) the villi grow deep into the myometrium and the placenta thus becomes inseparable from the uterine wall. This is a very rare case though.

The placenta can adhere to the uterine wall by its entire surface or only by part of it. Adherence of the placenta is caused by changes produced in the uterus by inflammatory diseases (endometritis), cicatrices after curettage and other operative interventions on the uterus, fibromyoma, and malformations of the uterus (underdevelopment, uterus bicornis, etc.). Adherence of the placenta often occurs in women after abortions.

Adherence of the placenta does not show during pregnancy or the first and the second stages of labour. Bleeding begins during the third (placental) stage of labour. It often becomes profuse. When the placenta is attached to the uterine wall by its entire surface, bleeding is absent. But as soon as part of the placenta is separated, while the adherent portion prevents further separation of the placenta and its delivery, bleeding starts. When the placenta is retained the uterus does not contract. The vessels of the placental attachment site (at the site of the separated placenta) open and bleeding continues until the placenta remains inside the uterus.

Cases with adherent placenta require urgent operative intervention. False adherence is easily managed by manual separation of the placenta and its removal from the uterus. In cases of placenta accreta (true adherence), the uterus should be extirpated.

Chapter Seventeen

PREGNANCY AND LABOUR OF PATIENTS WITH MEDICAL DISEASES

Acute and Chronic Infectious Diseases

Pregnancy does not protect the woman from infection and the incidence of infectious diseases among pregnant is the same as in non-pregnant women. But the course of most infections is more grave in the pregnant. All infections, especially acute ones, are a danger to the intrauterine foetus. The foetus often dies and pregnancy is thus terminated prematurely. The incidence of abortion and premature delivery is especially high in acute infectious diseases such as typhus, abdominal fever, grave influenza, acute dysentery, infectious hepatitis, etc. The foetus dies and is delivered prematurely in connection with intoxication of the mother and the foetus, elevated body temperature, and upset vital functions of the pregnant. Premature termination of pregnancy may be the result of haemorrhage into the placenta and dystrophic changes in it, which often occur in infectious diseases. Many causative agents of infectious diseases acquire in these conditions the ability of penetrating the foetus from the maternal blood and thus poison the foetus. The latter will usually die because the immune response is absent or very weak.

Abortion and premature labour in turn aggravate the course of the infectious disease through the loss of blood, upset metabolism, or postpartum (post-abortion) sepsis, etc.

Scarlet fever, diphtheria, measles and other acute infectious diseases of the pregnant are very rare in the Soviet Union.

Influenza. The incidence of influenza in the pregnant is higher than of other infectious diseases. Influenza often causes premature labour, especially in the late months of pregnancy. Complications of labour, such as uterine atony, painful contractions, bleeding in the placental and postpartum periods, and puerperal diseases connected with septic infection, often develop in influenza patients.

Neonates are quite susceptible to influenza. If proper prophylactic measures are not taken, influenza rapidly spreads among the neonates in the lying-in hospital. To prevent spreading of influenza, the women and the babies should immediately be placed into separate rooms when the very first signs of the disease appear.

Masks should obligatory be worn and the wards aired thoroughly and irradiated with a mercury-quartz lamp if possible.

Tuberculosis. Tuberculosis often has an adverse effect on pregnancy, which in turn aggravates the course of tuberculosis.

Pregnancy usually has no negative effect on women cured of tuberculosis or on patients with tuberculosis in the compensated form. Active tuberculosis is aggravated with pregnancy, in late months in particular. Tuberculosis of

the larynx progresses rapidly in pregnancy.

The postpartum period and breast-feeding would adversely affect the tuberculous process.

Grave forms of tuberculosis can cause premature labour. *M. tuberculosis* rarely pass from the mother to the foetus but the infant can easily be infected by its mother post partum.

All pregnant with tuberculosis (or with tuberculosis in past history) should consult a doctor who decides whether or not the pregnant should attempt delivery. Artificial abortion is indicated in active pulmonary tuberculosis (and in tuberculosis of other organs, the larynx in particular). Compensated forms of the disease are not contraindications to childbirth.

Pregnant with tuberculosis should be under the constant observation of a specialist and the obstetrician. When necessary the patient is given special treatment (streptomycin, PASA, phthivazid, etc.). The patient should be delivered at special departments which must be available at one of the municipal lying-in hospitals. The puerpera and her infant should be thoroughly cared for. Breast-feeding is prohibited in active tuberculosis; with quiescent forms of the disease the mother may feed her baby, but the condition of the woman should be carefully watched. The mother should wear a mask to cover her mouth and nose during nursing.

For prophylactic purposes the neonate should be vaccinated against tuberculosis during the first days of its life (BCG vaccination), which increases the resistance of the baby to tuberculosis.

Malaria. The disease is unfavourable to pregnancy, labour and the puerperium, which, in turn, aggravate the course of the disease.

Malaria is often the cause of an abortion or premature labour. The disease is often attended with haemorrhage into the placenta, necrosis of the villi and other changes that worsen the conditions for the development of the foetus. Serious changes in the placenta provide conditions for the transfer of *P. malariae* from the mother to the foetus with subsequent infection of the latter.

Questioning of the pregnant should reveal the presence of malaria in past history; if any signs of malaria are revealed, such as elevation of the body temperature and the like, the blood of the patient should be thoroughly tested for *Plasmodium*.

Pregnant and puerperas with malaria should be given quinine and quinacrine. The anti-malarial therapy would not usually disrupt pregnancy. Abortion and premature labour occur as a result of malaria, while quinine and quinacrine prevent abortion.

Syphilis. Untreated syphilis is a grave complication of pregnancy. Syphilitic infection passes from the mother to the foetus and is detrimental to the latter.

If syphilis is untreated or treated inadequately, pregnancy ends in abortion or premature labour. The born infants are infected with the disease or born dead (even if delivered at term). The syphilitic infection is transmitted to the foetus through the placenta which undergoes significant changes in syphilis (narrowing of the vessels, swelling of the connective tissue, enlargement of the placenta). The infected neonate is born with eruption on the skin, with vesicles on the palms and soles, enlarged liver, and sometimes with ascites.

If the woman begins treatment before or during pregnancy, the danger of stillbirth or infection of the foetus diminishes. Adequate and timely treat-

ment of the pregnant helps her recover and deliver a healthy baby. Timely revealing of syphilis and its proper treatment are therefore of greatest importance.

Revealing syphilis is facilitated by questioning and a detailed examination of the pregnant. Querying reveals indications for syphilis in the pregnant (the presence of syphilis in past history, previous abortions and stillbirths), in her husband or relatives. The blood of the pregnant should obligatory be tested (Wassermann's test). Pregnant with syphilis should be treated (penicillin, neosalvarsan, biiochinol, etc.). Two or three courses should be given during pregnancy. The mother and the infant should be treated after delivery as well.

Gonorrhoea. The pregnant may develop gonorrhoea before or during pregnancy. Gonococcal diseases of the female genitalia are often the cause of sterility. The incidence of sterility is especially high in patients with gonorrhoeal inflammation of the fallopian tubes which become obstructed. The gonorrhoeal affection of the endometrium can cause temporary sterility; pregnancy often ends in abortion. If the gonorrhoeal affection is limited to the cervix and the urethra, pregnancy may occur and develop normally after the symptoms subside. If the woman is infected during pregnancy, the urethra, the cervix and Bartholin's glands are affected by the acute inflammatory process. The infection may spread onto the vulva and vagina which is facilitated by looseness and increased content of serous fluid of tissues. Urination becomes painful and intense leukorrhoea develops. Wartlike excrescences (condylomas) develop on the external genitalia and in the vagina. Acute condylomas may develop in viral diseases.

Gonorrhoeal infection that develops during pregnancy does not spread onto the uterus. After delivery (provided gonorrhoea is not treated) the disease spreads onto the uterus as well, and the process may propagate to the tubes, ovaries, and the pelvic peritoneum.

The foetus can be infected with gonorrhoea during delivery. The infection may cause blennorrhoea (the gonococcal inflammation of the conjunctiva), inflammation of the rectum, and (in girls) vulva and the vagina.

If gonorrhoea has been successfully treated before the onset of pregnancy, the residual changes caused by the inflammation (cicatrices, commissures, infiltrations) will subside during pregnancy.

When the pregnant is being examined, all indications for gonorrhoea should be taken into consideration (gonorrhoea in past history of the woman or her husband, painful urination, purulent leukorrhoea, etc.). If any suspicion arises as regards gonorrhoea, the urethral discharge should specially be tested and the cervix, vagina, and other organs examined thoroughly.

The pregnant with gonorrhoea should be treated immediately after the diagnosis has been established. The therapy is in general the same as prescribed for non-pregnant women.

Toxoplasmosis. It has recently been established that toxoplasmosis can be the cause of abnormal development of the foetus and stillbirths. Organisms of the genus *Toxoplasma* parasitize on monkeys, domestic and wild animals, roddents and birds and may be transmitted to man through the gastrointestinal and respiratory tracts, bites, etc. Acute and chronic toxoplasmosis occurs in adults. The acute form is characterized by a variety of symptoms and resembles in its course typhus, me-

ningoencephalitis, lymphadenitis, etc. Chronic toxoplasmosis is only marked by few symptoms and is often latent; it can be revealed by special serological tests.

The foetus can be infected by its mother. Congenital toxoplasmosis may be the cause of intrauterine death. When born alive, the infant develops anomalies (hydrocephalus, microcephalus, etc.), its nervous system may be affected (convulsions, paralysis, paresis), diseases of the retina (chorioretinitis), liver, kidneys, and other organs may develop.

Affection of Vital Organs and Systems

Cardiovascular diseases. Pregnancy and labour impose an additional load on the cardiovascular system of the woman. A healthy pregnant overcomes the new burden with an ease, but patients with cardiovascular diseases often develop circulatory disorders and other medical complications. Pregnancy and labour, as well as the postpartum period, deteriorate the course of cardiovascular diseases. The most dangerous are defects of bicuspid valve with prevalence of stenosis, all cardiac disorders of rheumatic aetiology (myocardial and endocardial affections), septic endocarditis, and stenocardia. All these diseases are aggravated during pregnancy: cardiac decompensation and circulatory disorders often develop (dyspnoea, cyanosis, oedema, etc.), which are indications for the termination of pregnancy. Cardiac and circulatory disorders easily develop during labour, especially in the expulsive stage. The strain of the nervous and muscular systems during labour cramps provokes disorders in the cardiac function. Collapse may also occur after delivery (due to the fall in the intra-abdominal pressure).

Cardiac disorders may be fatal. Pregnancy can end prematurely in women with decompensated heart diseases. Foetal asphyxia often occurs during labour. Symptoms of intracranial injuries are sometimes found in neonates during their first days of life.

If the mitral insufficiency is compensated, cardiovascular disorders occur rarely in connection with pregnancy. Labour is usually normal as well, but decompensation may develop. Some patients with heart diseases develop cardiac decompensation post partum.

For timely detection of cardiovascular patients, all pregnant women should be thoroughly inspected during their first visit to the doctor (anamnesis, examination, percussion, auscultation, taking pulse and arterial pressure). The pregnant with signs of cardiovascular disorders should be examined by the obstetrician, gynaecologist and therapist. If diseases dangerous to the woman health (mitral stenosis, endocarditis, myocarditis, stenocardia, etc.) are found, pregnancy is terminated at early terms (to 12 weeks); if pregnancy is over 12 weeks when the woman first consults the doctor, she is hospitalized for treatment and the physician decides whether the woman is able to continue her pregnancy. If the condition of the pregnant worsens despite the therapy given, the pregnancy is terminated by a caesarean section. The condition of the pregnant permitting, the operation is performed at late terms to deliver a viable foetus.

Labour of cardiovascular patients should be conducted under observation of the physician; cardiac drugs, glucose and oxygen should be given. To facilitate labour the foetus is extracted by

forceps. Spontaneous labour can be allowed in women with compensated mitral defects (with prevalence of valve defects).

After the infant has been delivered, weight should be applied onto the abdomen (a bag with sand), or the abdomen should immediately be bandaged to prevent collapse.

Bed rest is necessary to the puerpera with disorders of the cardiovascular system, and the patient should be dismissed from the hospital not sooner than in three weeks after childbirth. Medical observation of the woman at home is required because her health may worsen in a few weeks or months following the delivery.

Hypertension. Pregnancy, as a rule, aggravates the course of hypertension. Pregnancy and labour can only be normal if the disease is mild (mild and transitory increase of the arterial pressure and the absence of organic changes). In persistent and marked hypertension, pregnancy worsens the clinical picture of the disease. The arterial pressure would slightly decrease during the first weeks, but the remission is only temporary and is followed by a new rise in the pressure, sometimes to high values.

Increasing vascular spasms impair oxygen and nutrition transport to tissues and cause disorders in the function of the vital organs and induce dystrophic processes in them. These disorders are attended with headache, deterioration of vision, proteinuria and casts in the urine. The uterine and placental vessels are also affected by spasms to impair the transport of oxygen and nutrition to the foetus, and severe hypertension is therefore often associated with delayed growth of the foetus, miscarriage and premature labour; stillbirths also occur. Haemorrhage into various organs, the brain included, may develop during the expulsive stage of labour.

Timely diagnosis of hypertension in the pregnant is the best prophylaxis of these complications. The pregnant should be thoroughly examined during her first visit to the doctor in order to reveal possible signs of the disease. If hypertension is diagnosed, the woman should be examined by a specialist. An abortion is indicated in cases with marked and persistent forms of the disease. If the woman desires to bear a child, she should be treated and observed systematically.

Diseases of the blood. *Anaemia* is often associated with pregnancy. Haemoglobin is reduced due to the increased requirements for iron by the developing foetus. Anaemia may also develop due to malnutrition, gastrointestinal dysfunction and disorders of other systems which are attended with insufficient assimilation of iron from the food taken.

Adequate nutrition and treatment will increase haemoglobin: the woman should take fresh vegetables, fruits, liver, vitamins, iron preparations.

A corresponding therapy should be prescribed to patients with disorders of the gastrointestinal and other systems.

Malignant anaemia of pregnancy is a rapidly progressing disease and pregnancy should therefore be terminated artificially.

The condition of *leukaemia patients* worsens with pregnancy and the woman may die from bleeding during labour or post partum. Thorough examination of the blood is therefore decisive in diagnostication of leukaemia.

Disorders of the urinary system. A very serious complication of pregnancy is *nephritis*. An acute condition may occur during pregnancy in connec-

tion with tonsillitis or other infectious diseases. Spontaneous abortion often occurs in nephritis. Pregnancy would usually aggravate the course of chronic and acute nephritis and this disease therefore indicates artificial abortion.

Pyelitis often occurs during pregnancy. The development of this disease is stimulated by ureteral atony and the associated retention of urine. The infection penetrates the lymph system from the intestine and, less frequently, from the bladder (ascending pathway). The most frequent causative agent of pyelonephritis is *E. coli*.

Pyelonephritis usually develops during the second half of pregnancy, in multigravida in particular. The onset of the disease is manifested by the rapid development of the symptoms; less frequently the disease develops gradually. The body temperature is elevated (often attended with shivering), lumbar pain develops, and the general condition worsens. The urine contains many leukocytes, epithelial cells of the renal pelves, and bacteria. The inflammation of the renal pelves can be detected by slightly knocking on the lumbar region (the Pasternatskii test is positive if knocking is painful).

Pyelitis is curable without imposing grave sequelae on the mother or the foetus. Pregnancy is discontinued only in rare cases. Milk and vegetable diet, warmth on the lumbar region, and intramuscular injections of streptomycin, kanamycin, and other antibiotics are recommended.

Cystitis may occur during pregnancy. The disease is evoked by compression of the bladder by the growing uterus or a presenting head, or oedema of the bladder walls. The infection can enter the bladder through the urethra, especially during catheterization. The urinary frequency increases, urination becomes painful, and body temperature is elevated.

Phenyl salicylate is prescribed if the urine is acid and urotropin if alkaline; sulpha drugs, antibiotic injections and milk-vegetable diet should also be prescribed.

Appendicitis. Acute appendicitis may occur during pregnancy or chronic appendicitis may be exacerbated. The danger of this complication consists in possible peritonitis. The blind-gut and the vermiform appendix are lifted by the growing uterus during the second half of pregnancy and this displacement impairs the conditions for separation of the inflammatory infiltration in acute appendicitis and may break down the commissures in chronic process. Appendicitis may become the cause of spontaneous abortion; the prognosis is less favourable for a pregnant woman.

Appendicitis should be treated surgically in pregnancy. The patient should be operated immediately after establishing the diagnosis. If the signs of appendicitis are obvious (pain in the right half of the abdomen, Shchetkin-Blumberg symptom, nausea, etc.), the patient should immediately be delivered to the hospital.

Disorders of the nervous system. Psychoses associated with pregnancy and labour occur infrequently and mostly in women with unbalanced nervous system. Psychoses of pregnancy are usually manifested by depressive states. Postpartum psychoses are often characterized by excitation. The woman should be hospitalized and appropriate treatment given to completely eradicate the symptoms in both pregnant and puerperas.

Pain in the region of the trigeminal, sciatic, or intercostal nerves often occurs in pregnancy.

Neuritis and *polyneuritis* associated with pregnancy are rare.

An epileptic patient may become pregnant; the course of the disease is, as a rule, aggravated, and less frequently, the number of epileptic fits decreases with the onset of pregnancy. Worsening of the patient's condition is an indication for an artificial abortion. Attacks of epilepsy differ from those in eclampsia in that the former occur in the absence of increased arterial pressure, oedema or albuminuria; anamnestic data reveal similar attacks before pregnancy.

Chorea is a rare disease of pregnancy; in some patients it first developed in childhood and in others occurs during pregnancy. The disease is characterized by the ceaseless jerky convulsions of all muscles of the body which do not discontinue during the night. The body temperature is elevated, the pulse increased and psychic disturbances are also frequent. Chorea is often the cause of spontaneous abortion.

Chorea is treated by hypnotics and preparations improving the general condition of the patient. If the therapy proves ineffective pregnancy should be terminated artificially.

Disorders of the endocrine system. The menstrual and reproductive function is often deranged in diseases of the endocrine system. But a patient with endocrine dysfunction often becomes pregnant and pregnancy frequently impairs her condition, though improvement also occurs in rare cases.

Diseases of the thyroid gland (hyperthyroidism and hypothyroidism) are usually exacerbated during pregnancy. In few patients the signs of Basedow's disease (hyperthyroidism) subside in pregnancy.

Thyroid dysfunction is indication for the termination of pregnancy except in cases with improvement.

Diabetes mellitus in the pregnant is not infrequent. The disease is usually aggravated during pregnancy and a coma may even develop because of the increased requirement of the mother and foetus for insulin, the amount of which decreases in diabetes mellitus. Polyhydramnios and toxaemia often develop in diabetes mellitus. The foetus may be large or even gigantic; it may often be born with signs of asphyxia, anaemia and upset metabolism. But if the disease is in the mild form and treated properly, pregnancy may develop normally.

Pregnant patients with diabetes mellitus should take food lacking carbohydrates; insulin and vitamins should be prescribed. The patient should be under observation of the physician (obstetrician, gynaecologist and therapist).

Pregnancy in Patients with Malformations and Diseases of the Genitalia

Malformations (abnormalities) of female genitalia. Abnormalities of the genitalia comprise (a) defective anatomy of the genitalia, e.g. duplex (double) uterus or vagina, atresia of the uterus, vagina, etc. and (b) underdevelopment of otherwise normal genitalia.

Marked abnormalities of the genitalia are often attended with deranged menstrual and reproductive function. The woman with certain abnormalities of the genitalia may conceive and even deliver.

Underdevelopment of the genitalia. The condition is characterized by scant pubic hair, drawn-in perineum, a narrow and short vagina, a

narrow cone-shaped cervix, a small uterine body (sometimes shorter than the cervix), and an acute angle between the uterine body and the cervix. The menstrual function is established at late age, and is often irregular (algomenorrhoea, scanty or, on the contrary, profuse and lengthy menstruations); sterility is frequent. Pregnancy often ends by a spontaneous abortion or premature labour. If the woman is delivered at term, complications of labour arise due to the uterine atony (underdeveloped uterine musculature). The atony usually manifests at the very onset of labour or during the expulsive stage. The placental stage of labour is often marked by bleeding, and the postpartum period is characterized by slowed down involution of the uterus.

Duplex uterus and vagina. The uterus and the vagina are formed during the early stages of the intrauterine foetal growth; they are formed from two müllerian ducts (canals) which unite at their middle and lower parts. The middle part of the fused canals forms the uterus, while the vagina is formed by their lower parts. The upper (non-fused) portions of the canals develop into the uterine tubes (Fig. 204).

Fig. 204. Formation of the uterus, the tubes and the vagina from müllerian ducts in an embryo:
1 — tubes; *2* — uterus; *3* — vagina; *4* — urogenital sinus; *5* — ureter; *6* — bladder

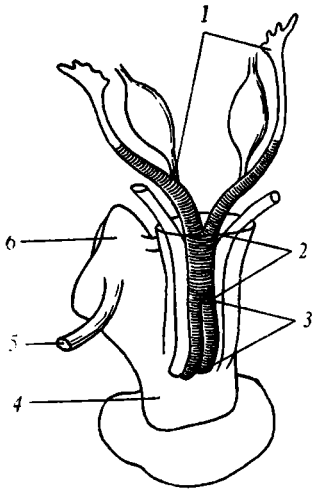

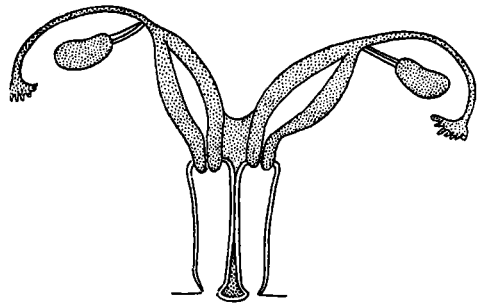

Fig. 205. Double uterus and vagina

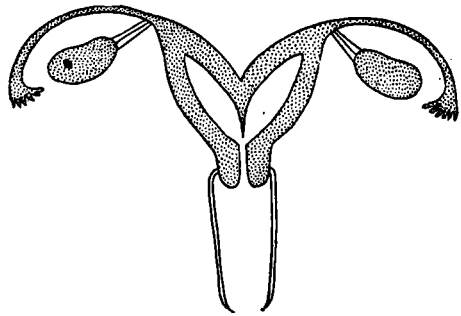

Fig. 206. Uterus bicornis

Abnormalities in the formation of the uterus and the vagina occur if the process of fusion of the müllerian ducts is disturbed.

A duplex uterus varies in structure: there may be two distinct uteri with two vaginas (Fig. 205), two uterine bodies (uterus bicornis) may be united by one cervix (Fig. 206), the uterus may have a depressed fundus (uterus arcuatus) (Fig. 207), with or without a partition inside the uterine cavity.

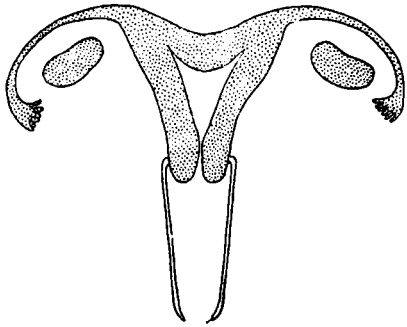

Fig. 207. Uterus arcuatus

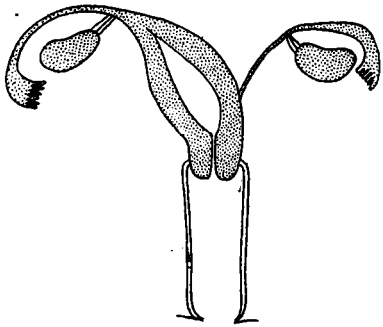

Fig. 208. Uterus unicornis (the second horn is rudimentary)

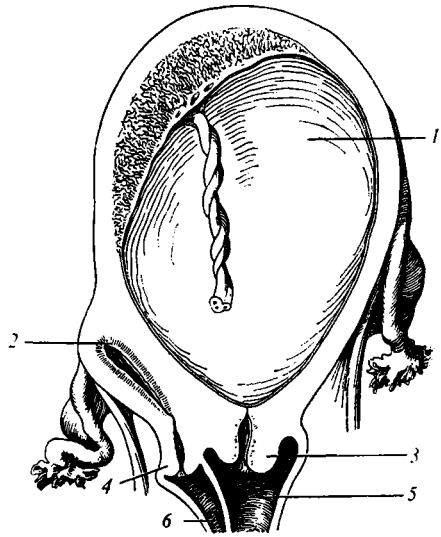

Fig. 209. A pregnant double uterus: *1* — pregnant uterus; *2* — non-pregnant uterus; *3* — cervix of the pregnant uterus; *4* — cervix of the non-pregnant uterus; *5*— left vagina; *6* — right vagina

Fig. 210. A pregnant uterus arcuatus

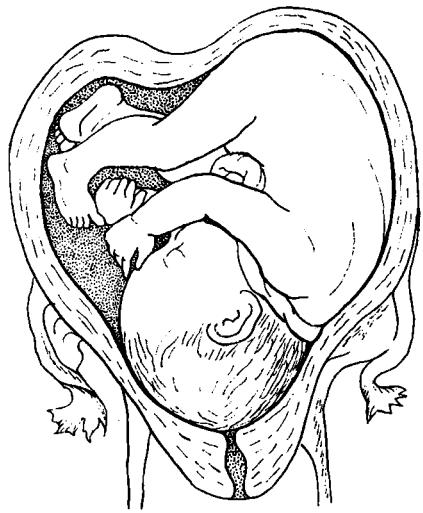

A partition may also be formed in the vagina. Sometimes only one horn develops (uterus unicornis) while the other remains rudimentary (Fig. 208).

The doubling of the uterus is not an obstacle to conception. Pregnancy usually develops only in one part of the uterus (in very rare cases in both); the second non-pregnant uterus slightly enlarges and softens; the decidual reaction occurs in the endometrium (Fig. 209). Pregnancy in women with a double uterus often ends in spontaneous abortion; labour is characterized by uterine atony, and bleeding in the placental and postpartum periods.

If the uterus is not underdeveloped or underdevelopment is not marked,

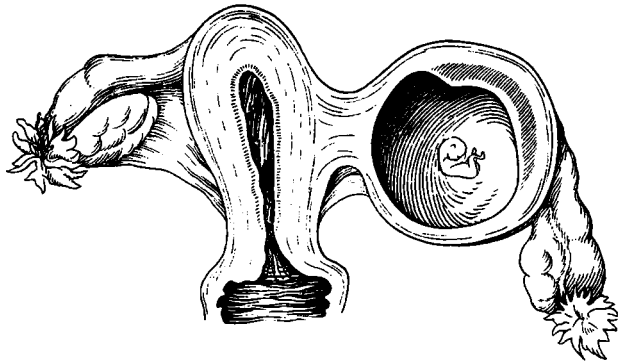

Fig. 211. Foetus developing in a rudimentary horn

pregnancy ends by normal labour at term.

Transverse and oblique presentations often occur in uterus arcuatus, but otherwise the pregnancy and labour may be normal (Fig. 210).

Pregnancy very rarely occurs in the rudimentary uterus (horn) which communicates with the adequately developed horn through a narrow canal. Cases were reported with pregnancy in a rudimentary horn which did not communicate with the uterus (Fig. 211). The spermatozoa penetrate the isolated uterus from the normally developed one through the tube and the abdominal cavity, from which they enter the tube of the rudimentary horn where the ovum is fertilized. The fertilized egg enters the rudimentary horn and implants here. The walls of the rudimentary horn are underdeveloped and the chorionic villi therefore grow through the endometrium and the myometrium of the uterus. The uterine wall is thus destroyed with a rupture of the rudimentary horn which is manifested by bleeding into the abdominal cavity with a subsequent shock. The symptoms of the ruptured rudimentary horn are similar to those of the extrauterine pregnancy. Urgent laparotomy and removal of the rudimentary horn are indicated. In rare cases pregnancy in the rudimentary horn progresses which is also fraught with danger because spontaneous labour is impossible. The life of the woman can be saved by laparotomy during which the foetus and the rudimentary horn are removed.

Partitions of the vagina are usually distended and do not interfere with delivery. If however the partition imposes an obstacle to the progress of the presenting part, it should be dissected.

Abnormal position of the uterus can be the cause of sterility. Pregnancy however occurs in certain cases with prolapsed uterus and its pathological displacements such as the uterine retroflexion, retroversion, etc.

Pregnancy in women with prolapsing uterus may cause temporary improvement of their condition. When the uterus increases in size and rises above the small pelvis, the prolapse is remedied, but the disease recurs (and even aggravates) after delivery.

Among pathological displacements of the uterus its retroflexion deserves special discussion. The bending of the uterus posteriorly does not limit its mob-

lity, but in some cases it becomes immobilized by commissures formed after inflammatory processes. Mobile retroflexion does not interfere with normal pregnancy. A pregnant uterus rises above the small pelvis by the fourth month of pregnancy and the retroflexion is thus corrected. If the uterus is retroflexed fixedly, pregnancy often softens or even resolves the commissures and pregnancy then continues normally. If the commissures are strong, the uterus remains immovably fixed to the neighbouring organs and the peritoneum of the posterior Douglas pouch. The growing pregnant uterus remains in the small pelvis and its thrust on the bladder and the rectum increases with time. The pregnant develops urinary disorders and constipation. she complains of abdominal pain. The urine discharge may be completely stopped.

If the immobile uterus is strangulated (Fig. 212), a spontaneous abortion may occur. In missing abortion an operative intervention is needed. If there are no dangerous symptoms that make the artificial abortion inevitable, the physician should undertake an attempt to correct the position of the pregnant uterus under anaesthesia.

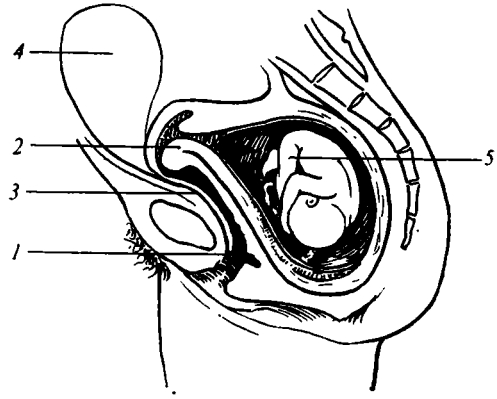

Fig. 212. Strangulation of a retroflexed pregnant uterus in the small pelvis:
1 — vagina; *2* — cervix; *3* — urethra; *4* — distended bladder; *5* — strangulated pregnant uterus

A pregnant with a strangulated uterus should be hospitalized.

New growths of genitalia do not always interfere with conception. Fibro-

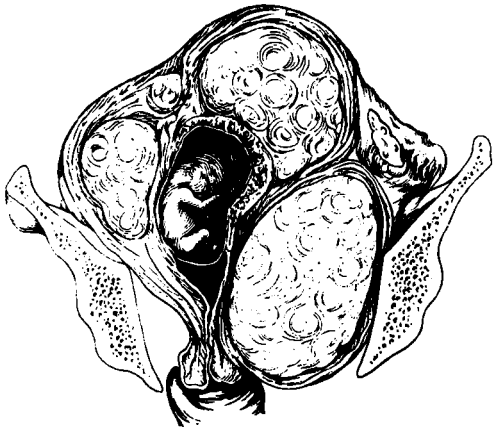

Fig. 213. Pregnant fibromyomatous uterus. The node is located in the small pelvis and presents an obstacle to expulsion of the foetus

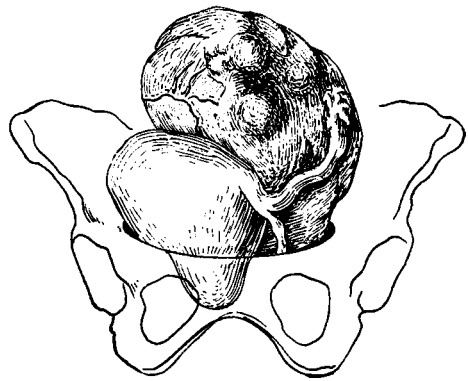

Fig. 214. Pregnancy and cystoma of the ovary

myoma becomes the cause of sterility or abortion only if the tumour develops into the uterine cavity. If the tumour develops inside the uterine wall or under the peritoneum the pregnancy may develop to full term. Labour is often characterized by uterine atony, bleeding in the placental and early postnatal period; prophylactic measures should therefore be taken to prevent the development of these complications in such patients.

Large tumour nodes located in the small pelvis or near the pelvic inlet are an obstacle to normal pelvic delivery (Fig. 213). A caesarean section is then indicated. When the nodes are revealed in due time, they may be removed surgically.

A woman with cystoma of the ovaries may get pregnant (Fig. 214). Small movable cystomas on pedicles do not interfere with the development of pregnancy while large ones are an obstacle to growth of the uterus and may cause abortion. Moreover, necrotic affections may develop in cystoma walls due to the thrust of the pregnant uterus. Cystomas that develop stationary in the small pelvis are a physical obstacle to the passage of the foetus through the birth canal. Small movable cystomas do not interfere with normal development of pregnancy to term and labour is usually normal as well, but the pedicles are often twisted after delivery to cause necrosis and purulence of the tumours which then becomes a real danger to the woman.

Treatment consists in laparotomy and removal of the tumours despite pregnancy. Pregnancy can be saved provided the operation is performed skillfully and the postoperative period is uneventful.

Cancer of the cervix does not rule out the possibility of getting pregnant. Pregnancy aggravates the course of the disease which becomes especially malignant. The tumour develops very rapidly and propagates onto the parametrial connective tissue, the vagina, the bladder, and other organs. All pregnant women (not only gynaecological patients) should therefore be given specular examination.

Cancer of the cervix is treated surgically: the pregnant uterus with the appendages, the parametrium, and the upper portion of the vagina should be removed with subsequent radiotherapy.

Chapter Eighteen

ABORTION AND PREMATURE LABOUR

Abortion (Miscarriage)

Abortion is the termination of pregnancy prior to the 28th week of pregnancy. Premature labour refers to the termination of pregnancy in the period between the 28 and 39th weeks of gestation.

The foetus born before the 28th week is not viable (except very rare cases), while a foetus delivered in premature labour can survive if treated properly (even if its weight is as small as 1000 g and the length is 35 cm).

An abortion during the first 14 weeks of gestation is called early and after 14 weeks to 28 weeks, late.

According to the Regulations of the Ministry of Health (1939) the termination of pregnancy prior to the 28th week with delivery of the foetus is referred to as abortion. The foetal length is 35 cm, the weight, 1000 g and below. If a foetus born before the 28th week of pregnancy survives to the time when the mother is discharged from the lying-in hospital, the termination of pregnancy is defined as premature labour irrespective of the length or weight of the newborn, which is registered officially as a neonate.

Artificial and spontaneous abortions are differentiated. A *spontaneous abortion* occurs without extraneous interference and contrary to the woman's wish. Repetitive abortions in women are identified as *habitual*.

An *artificial abortion* is the deliberate termination of pregnancy.

Spontaneous Abortion

Causes of spontaneous abortions are varied. These may be infectious diseases, such as typhus, influenza, toxoplasmosis, infectious hepatitis, malaria, dysentery, etc. Pregnancy can also be terminated in pneumonia, pleuritis, appendicitis and other diseases attended with elevated temperature and intoxication. Syphilis is another cause of abortion (or premature labour).

Among commonly encountered causes of abortion are underdevelopment of the genitalia (infantilism), chronic inflammatory diseases of the uterus (endometritis, metritis) and also affections of the circular muscles of the isthmus and the internal os arising after abortions and operative delivery in past history. The cervical os will then open and the conceptus fails to be retained in the uterus. A spontaneous abortion often occurs in dysfunction of the endocrine organs (ovaries, adrenals, thyroid and other glands of internal secretion).

Women with repetitive abortions often have ovarian hypofunction connected with infantilism of the genitalia or due to artificial abortions in past history, inflammatory diseases of the genitalia, or other pathological processes. Various adrenal disorders (often in ob-

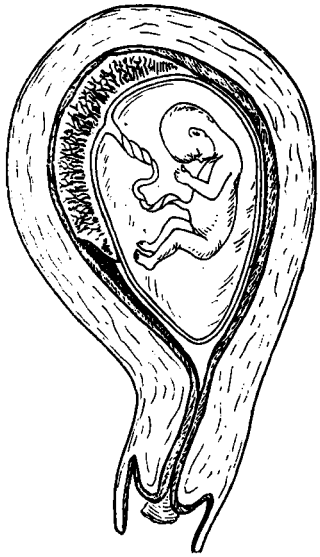

Fig. 215. Threatened abortion

literated forms), hypo- and hyperthyreosis, diabetes and other endocrine disorders may be the cause of abortion.

Various heart diseases attended with circulatory disorders can provoke abortion. Lack of vitamins in food leads to intrauterine death of the foetus with subsequent abortion. Deficiency of vitamins E, C, A and B is especially dangerous.

Various injuries (contusions, bone fractures, etc.) can cause an abortion provided any predisposing factor is present (such as infantilism, inflammatory disease, etc.), while healthy women often remain pregnant even after grave injuries (contusion, fracture of the pelvic bones or extremities). A strong emotional stress (distress, fears, etc.) may provoke an abortion in women with an unbalanced nervous system. Poisoning with mercury, lead, carbon monoxide, alcohol, morphine and other substances may cause an abortion. X-rays and other harmful radiation may become the cause of an abortion as well.

In abortion the conceptus is separated gradually from the uterus. The blood vessels of the decidual membrane are broken. The separated ovum perishes and becomes impregnated with blood. The uterus develops contractions, the endocervical canal dilates and the conceptus is expelled from the uterus in one movement or by two parts. The woman feels pains in the abdomen, their intensity increasing with the gestational age. Thus in an early abortion the pain is not marked or may be absent altogether. An abortion is, as a rule, characterized by bleeding, the intensity depending on the stage of abortion and the gestational age. Excessive bleeding occurs in most cases in an early abortion.

The mechanism of a late abortion is like that of labour: the cervix is effaced and dilated, the amniotic fluid is discharged, the foetus is delivered, and the delivery is followed by the discharge of the placenta. Bleeding occurs if placental separation and delivery are abnormal.

The following stages of abortion are distinguished: (1) threatened abortion; (2) imminent abortion (abortus incipiens); (3) inevitable abortion, or abortion in progress (abortus progrediens); (4) incomplete abortion; (5) complete abortion.

Threatened abortion. The conceptus remains attached to the endometrium and its connection with the uterus is only disrupted over small areas (Fig. 215). Bleeding is absent or insignificant, the cervix is closed, the uterus size agrees with the gestational age. The pregnant feels lower abdominal discomfort; in late abortion the pains are like those in labour.

If the woman is treated properly her pregnancy can be saved. The pre-

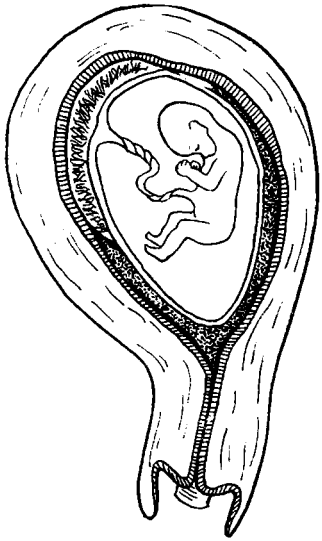

Fig. 216. Incipient (imminent) abortion

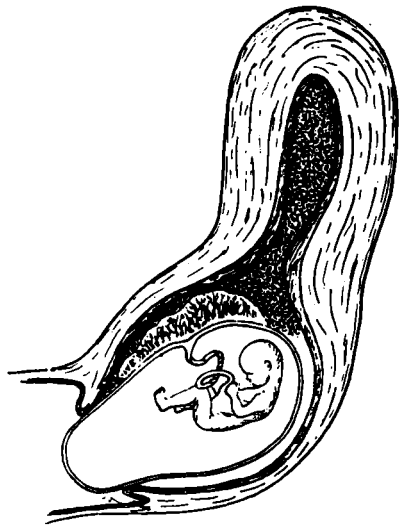

Fig. 217. Inevitable abortion (abortion in progress)

quisite condition is abstention from sexual intercourse and bed rest for two or three weeks. Progesterone is recommended (daily 5-10 mg intramuscular injections during ten days). If indicated (infantilism, ovarian hypofunction) small doses of oestrogens (oestrone, microfollin, oestradiol dipropionate) can also be given. Papaverine suppositories (0.02-0.015 g) can be given once or twice a day. Belladonna extract is not used because it stimulates dilation of the uterus. Vitamin E is recommended (one teaspoonful 3 or 4 times a day). Haemostatics (ergot preparations, pituitrin, etc.) should not be used since they induce uterine contractions and promote separation of the conceptus from the uterus. Vaginal syringing, hot-water or ice bags on the abdomen are contraindicated for the same reason.

Imminent (incipient) abortion. Uterine cramps are not strong, bleeding is not considerable but more intense than in a threatened abortion. The conceptus has separated from the uterus over a small area (Fig. 216) but still remains inside the uterus and the uterus size therefore corresponds to the gestational age. The endocervical canal is closed or only slightly dilated. Measures should be taken to discontinue the incipient abortion. The treatment is the same as in a threatened abortion. If bleeding intensifies, the abortion passes to its next stage and the conceptus is expelled from the uterus.

Inevitable abortion (abortion in progress). This stage is marked by profuse bleeding during which the conceptus is expelled from the uterus through a dilated endocervical canal (Fig. 217). The vaginal examination shows that the cervix is dilated and the lower pole of the foetus protrudes into the vagina. An inevitable abortion, especially an early one, can be treated by a surgical removal of the separated

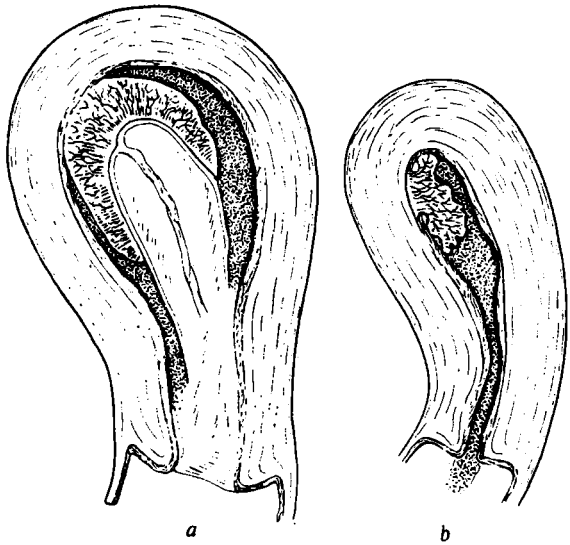

Fig. 218. Incomplete abortion:
a — all membranes are retained in the uterus; *b* — remnants of the conceptus are retained in the uterus

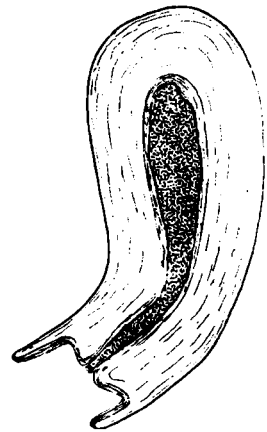

Fig. 219. Complete abortion.

egg. If the abortion is late, a spontaneous expulsion of the foetus should be allowed. If however the bleeding is very intense, the membranes should be punctured; after the foetus is delivered, the placenta should be removed either manually or by tools.

Incomplete abortion. If only part of the conceptus has been expelled while its portion still remains in the uterus, the abortion is incomplete. A chorion, amnion, decidua or placenta, or their parts, may be retained in the uterus (Fig. 218). An incomplete abortion is marked by haemorrhage. The bleeding may be prolonged, moderate, or profuse; blood clots, parts of the retained membranes can often be discharged together with the blood. The endocervical canal passes a finger, both the internal and external os being open. The size of the uterus does not correspond to the term of pregnancy: since the uterus is partly emptied, its size is smaller than at the corresponding gestational age. The uterus is soft.

Instrumental removal of the remnants of conception products is indicated in an incomplete abortion. If foetal or membranous remnants are retained in the uterus a fatal bleeding and infectious diseases may develop. Women with an incomplete abortion should therefore be immediately hospitalized. If the condition of the woman is grave, she should be given medical assistance at home.

Complete abortion. An abortion is complete if the entire conceptus has been expelled from the uterus (sometimes by a single movement) (Fig. 219). If an abortion is complete, the uterus contracts, the endocervical canal closes, and the bleeding stops. In early

pregnancy the incidence of a complete abortion is lower than at later terms. The decidual membrane is usually retained in the uterus in an early abortion, even if an intact foetus has been expelled. The retained decidua is the cause of lengthy bloody discharge from the uterus and infection (decidual endometritis). Curettage is therefore recommended after a complete early abortion to remove the decidual membrane. Curettage is unnecessary in a late complete abortion.

Septic abortion. If a spontaneous abortion is prolonged, microbes often penetrate the uterus from the vagina. A criminal abortion is especially dangerous in this respect. Microbes that enter the uterus during an abortion find favourable conditions inside the uterus where they propagate in the blood and the separated parts of conception products.

The microbes infect the elements of the foetus, but later they may spread onto the uterus, the tubes, the ovaries and the pelvic peritoneum and connective tissue. The infection can initiate general sepsis which may be fatal to the woman. Whether the microbes develop only in the foetus or spread onto the uterus and beyond its limits depends on the virulence of a particular microbe and resistance of the woman.

Depending on the degree of the infection spreading all cases can be subdivided into the following: (1) uncomplicated, (2) complicated, and (3) grave sepsis. In an uncomplicated infectious abortion the infection does not propagate beyond the uterus; palpation of the uterus is painless, the appendages, the pelvic peritoneum and connective tissue are not affected. The body temperature is elevated, the pulse accelerated (but agrees with the temperature), and the general condition is satisfactory. A complicated infectious abortion is marked by spreading of the infection beyond the uterus. Examination reveals painfulness of the uterus, affection of the appendages, peritoneum and the pelvic connective tissue (painfulness, infiltration, etc.). The general condition of the woman is unsatisfactory, the body temperature is high, she complains of pain and other disorders.

The clinical picture of a septic abortion is marked by grave disorders. The condition of the woman is grave, sleep is deranged, the appetite is absent, the tongue is dry, the skin is pale, sometimes with a yellowish or greyish tint. Early symptoms of sepsis are shivering, high temperature, and high pulse rate (which does not agree with the temperature). Thrombophlebitis and metastatic abscesses of the lungs, kidneys, and subcutaneous connective tissue often develop. Marked inflammatory processes in the small pelvis may be absent.

Treatment of infectious abortions is a complicated problem for an obstetrician-gynaecologist. Each woman with an infectious abortion should be hospitalized. If the abortion is uncomplicated, antibiotics or sulpha drugs shall be given; in five or six days after the temperature has normalized, the remnants of the foetus should be removed by a curette or a vacuum extractor. At some obstetrical clinics this operation is performed immediately on the admission of the patient.

If an abortion is complicated or septic, the patient is treated conservatively (antibiotics, sulpha drugs, general tonics, analgesics, adequate nutrition and care). Remnants of the foetus and the membranes are allowed to be delivered spontaneously since curettage may provoke spreading of the infection. Curet-

tage is only resorted to in cases with profuse bleeding which may become fatal to the patient. To intensify uterine contraction and accelerate expulsion of the remnants of the infected conceptus quinine or pituitrin should be given.

Artificial Abortion

An artificial (or induced) abortion is done in a hospital.

If, by some reason, a woman is not prepared to bear a child she consults a doctor who decides if there are any contraindications to the termination of her pregnancy (inflammatory diseases of the genitalia, etc.). If contraindications are revealed, the pregnancy is saved and the woman is given the necessary medical aid.

An abortion is performed by a single surgical operation with observation of all aseptic requirements. The operation can only be performed by a specialist in the hospital.

If the gestational age is over 12 weeks, pregnancy may be terminated only for special medical indications (in the presence of diseases which can be aggravated by pregnancy and may endanger the life of the pregnant). Among diseases which indicate an abortion are cardiac diseases, hypertension, active pulmonary tuberculosis and tuberculous affection of other organs, diseases of the kidneys, liver, gastroduodenal ulcer, and also operations on the abdominal organs in past history.

Diseases which can be inherited from the parents, such as syphilis, psychic disorders, etc. indicate an abortion. There may be other indications for the termination of pregnancy, such as the absence of extremities in the mother, ankylosis, deafness, blindness, and other conditions that make the woman unable to give her future infant the necessary care.

Curettage in late pregnancy is prohibited because the danger of perforation of the uterus or other grave injuries exists. In the presence of medical indications, a pregnancy over 12 weeks should be terminated by giving oxytocin, prostaglandin or other preparations. Whenever necessary, a sterile hypertonic solution of table salt (10 per cent) should be injected intramembranously. Dilation of the uterine cervix by a metreurynter or transvaginal section can also be used.

A criminal abortion, self-induced or otherwise (outside the hospital), still unfortunately occurs. In order to terminate the unwanted pregnancy the woman sometimes takes various medicinal preparations, or allows intrauterine injections of chemical substances, insertion of a bougie, or some other extraneous objects. All these methods are fraught with great danger to the woman's health. The main danger resides in the possible infection of the uterus with pathogenic microbes that may cause inflammatory diseases and even general sepsis. Bleedings often persist to result in an acute blood loss which may be fatal to the woman. When a bougie or other tools are inserted into the uterus the danger of uterine perforation arises; the intestine or other organs can also be perforated with a fatal outcome. Inflammatory diseases and injuries of the uterus can also occur when an abortion is performed in a hospital.

Post-abortion inflammatory diseases may persist over long time and induce unfavourable sequelae. Abortions complicated with infection often become the cause of subsequent sterility, ectopic pregnancy, spontaneous abortion, etc. Placenta praevia, adherent placenta.

uterine atony, considerable bleeding in the placental and puerperal stages can develop in women with an abortion in past history. Post-abortion inflammatory diseases of the uterus may become a predisposing factor to the rupture of the uterine wall during labour.

Prevention of Abortion

Prophylaxis of abortion is the duty of the medical personnel of lying-in hospitals and other obstetrical institutions. An obstetrician plays an important role in abortion control.

Prophylactic measures against spontaneous abortion comprise the removal of factors that might interfere with normal course of pregnancy. All pregnant with signs of infantilism or those with habitual abortion or premature labour should be specially observed. These women are recommended a reasonable way of life (abstention from sexual intercourse or fatiguing exercises, adequate nutrition, etc.); when signs of a threatened abortion appear, the woman should be hospitalized. Safeguarding the pregnant from infection and timely treatment of possible diseases (malaria, influenza, tonsillitis, etc.) are very important. Adequate nutrition, sufficient supply of vitamins are especially important measures to prevent an abortion. Labour hygiene is another important prophylactic factor: the pregnant should be protected from possible exposure to noxious chemicals, high ambient temperatures, overstrain, vibration, etc.

Prevention of induced abortions includes health education (and use of contraceptives). Women should be acquainted with the risk they undertake by resorting to an artificial abortion (in press, reports, talks, and the like).

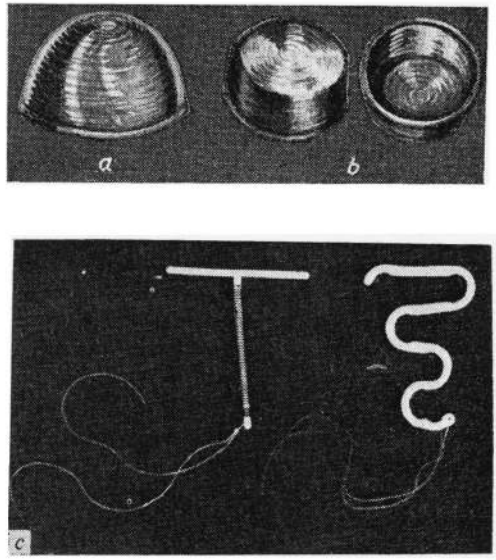

Fig. 220. Contraceptives:
a — vaginal cap; *b* — cervical caps; *c* — intrauterine contraceptives

Contraceptives

Mechanical, chemical, endocrine and other contraceptives are now available. Mechanical contraceptives diminish the likelihood of or prevent conception by imposing an obstacle to the entrance of the spermatozoa into the uterus. Chemical contraceptives suppress the vital functions of the spermatozoa. Good results may be obtained with the combined use of both mechanical and chemical contraceptives simultaneously.

Contraceptive measures must be harmless. Intrauterine instillations of iodine solution or some other chemicals, such as corrosive sublimate or the like, are detrimental to the health of the

woman. Coitus interruptus should be avoided as well.

Mechanical contraceptives are condoms for men and caps for women; the latter are inserted into the vagina or put on the cervix.

A rubber condom prevents penetration of the semen into the vagina which remains in it after an ejaculation.

Female caps also prevent penetration of the spermatozoa into the uterus. Various caps are available. An efficacious cap is the one shown in Fig. 220, *a*. This is a rubber sheath attached to an elastic ring, which is compressed by the fingers before the introduction into the vagina. The cap is moved by the fingers into the vagina along its posterior wall until the lower end of the ring reaches the posterior fornix of the vagina. The ring is then released and its upper margin is directed by the finger to the anterior fornix. When positioned correctly, the cap tightly fits the vaginal walls.

Caps may also be put on the cervix (Fig. 220, *b*). These are made of latex, rubber, aluminium, silver, etc. The caps can only be used in the absence of erosion, inflammatory or other diseases of the cervix.

The caps should be sterilized by boiling and kept in a weak disinfectant solution before use. They should be removed after an intercourse (in any case they may not remain in the vagina for more than two or three days). A contraceptive paste should be better applied to the cap margins before use.

Caps differ in size and should therefore be prescribed by a doctor or an obstetrician.

Various devices made of synthetic materials are now used as intrauterine contraceptives (Fig. 220, *c*). These may be small rings, spirals and so on, provided with a thread by which the device can be pulled out of the uterus. These devices are sterilized and introduced into the uterus (using a special tool) for considerable lengths of time.

The contraceptive effect of these devices is attributed by some authors to the intensified motor activity of the uterine tubes by which the egg is expelled from the uterus before or soon after its fertilization.

The mechanism of action and possible sequelae of using intrauterine contraceptives are now being studied.

Sponges and *tampons* (plugs) soaked in weak acid or some other substances suppressing the vital activity of spermatozoa are also used as contraceptives. Tampons can be made of cotton wool (the ball size should correspond to the width of the vagina) by tying up a thread round the cotton wool, whose end should be long enough to facilitate the removal of the tampon after coitus. Sponges or tampons should be soaked in boric acid or vinegar (a tablespoonful in a glass of water) or a 1 per cent quinine solution. The plug is inserted into the vagina before an intercourse so that it covers the cervix. After coitus the plug should be removed by the thread and the vagina irrigated with a disinfectant solution.

Syringing is usually used as an additional measure, but in the absence of other contraceptives syringing alone can be used as an independent measure to prevent conception.

A solution of acetic or boric acid may be used for syringing (2-3 teaspoonfuls per litre of water). Syringing is effective if done immediately after coitus.

Chemical contraceptives include special pastes, balls, tablets *containing substances producing a toxic action on spermatozoa* (quinine, quinosol, gramicidin, weak acids, etc.).

Pastes or tablets should be introduced

into the vagina before coitus where they melt and coat the cervix and the vaginal walls. It is not recommended to use one contraceptive for long periods of time; contraceptives should be better alternated. A suitable contraceptive and its substitution by another one should be prescribed by the physician. The obstetrician should instruct the woman how to use a given contraceptive.

Pills inhibiting the ovulatory function have been used in recent years. These contain oestrogens and gestagen (progestational action). The pills are taken daily, from the 5th till the 25th day of the menstrual cycle, to inhibit the ovulatory function or to kill the fertilized egg at the early stage of its development. Side effects sometimes occur (vomiting, blood smearing, etc.). Long use of one contraceptive (over one year) is not recommended.

Undesired pregnancy can also be prevented by abstention from sexual intercourse in the period from the 11-12th till the 19-20th day of the cycle.

Premature Labour (Partus praematurus)

Premature labour is the termination of pregnancy after the 28th till the 39th weeks of gestational age. The foetus born by premature labour is immature but viable.

The degree of labour prematurity and foetal dysmaturity can be determined by the anamnestic data and objective findings of the examination of the pregnant and the delivered infant. Weight and length of the neonate, and also other signs characterizing the gestational age of the foetus are important.

Aetiology. Premature labour may occur in connection with the same causes as in spontaneous abortion (diseases, intoxication, infantilism, etc.). Predisposing factors are abortions in past history, late pregnancy toxaemia (nephropathy, pre-eclampsia, eclampsia), endocrine and nervous disorders.

Premature Labour. Premature labour has the same stages as labour at term: uterus develops regular contractions, the cervix is effaced and dilated, the amniotic fluid is discharged, and finally the foetus is delivered followed by the delivery of the placenta. But complications occur more likely in premature labour than in labour at term. The most frequent complication of premature labour is premature (or early) escape of the amniotic fluid and uterine atony.

Breech, oblique and transverse presentations often occur in premature labour; bleeding is not infrequent, in the puerperal period in particular.

The incidence of asphyxia, intracranial labour injuries and stillbirths is higher in premature labour.

Prophylaxis and Treatment. Since premature labour is unfavourable to the mother and the foetus, measures should be taken to prevent it. The prophylactic measures comprise normal way of life and adequate nutrition of the pregnant, her protection from infection or intoxication, timely revealing and proper treatment of diseases that may develop in pregnancy.

When signs of premature termination of pregnancy are detected (abdominal discomfort, blood smearing) the woman should be hospitalized. She should be placed in a special pathology department (provided such a department is available). The pregnant is prescribed bed rest, progesterone, analgesics, and vitamins.

During conducting labour special attention should be paid to the general condition of the mother and the foetus. Whenever necessary uterine contractility should be stimulated medically; steps should also be taken to prevent asphyxia of the foetus; medical assistance, whichever required, should be given to the parturient. The foetal head should be handled with special care in manual assistance to prevent perineal laceration. The born foetus should be protected from infection and cold.

The puerpera and her premature infant require special observation.

Chapter Nineteen

ECTOPIC PREGNANCY

Normally, the fertilized egg moves along the tube to enter the uterus and to implant in its mucosa. But the conditions for the movement of the egg may by some causes be upset and the fertilized ovum may implant elsewhere to cause extrauterine, or ectopic, pregnancy (graviditas extrauterina).

Ectopic pregnancy includes those implanting in the uterine tubes (tubal pregnancy), the ovary (ovarian pregnancy) or the abdomen (abdominal pregnancy) (Fig. 221). Tubal pregnancy is 99 per cent of the total incidence of ectopic pregnancy, the terms 'ectopic' and 'extrauterine' being thus almost synonymous.

Aetiology. Changes caused by inflammation of the tubes are the most common cause of extrauterine pregnancy. Flexures, narrowings, commissures and other changes develop in the tubes due to inflammatory processes which interfere with the migration of the egg. The egg may thus settle in the tube and implant here. The inflammation impairs the peristalsis of the tubes which also deteriorates the conditions for the advancement of the egg into the uterus.

Ectopic pregnancy is often due to infantilism (underdevelopment of the genitalia). The tubes in an infantile woman are long and sinuous, their lumen is narrow and peristalsis is weak. A fertilized egg has to pass a long way but its progress in the tube is slow (due to inadequate peristalsis). During this time of travel, the fertilized egg grows to the stage when it becomes prepared for implantation (due to the developed trophoblastic properties). The egg therefore precipitates inside the tube and implants into its wall.

Ectopic pregnancy may occur after intrauterine application of iodine solution which deteriorates the tubal patency. Excessively long breast-feeding decreases contractility (peristalsis) of the tubes and if an impregnated egg migrates at a slow rate along the tube, it can implant in its wall.

Changes in the tubes. In ectopic pregnancy a fertilized egg precipitates in the depth of the proliferated tubal mucosa; the chorionic villi do not grow farther than the compact layer of the mucosa, which is very thin and is therefore quickly destroyed by the chorionic villi. When the tubal mucosa is destroyed, the villi grow into the muscular coat of the tube to destroy the muscle fibres and the blood and lymph vessels. Extrauterine pregnancy usually terminates in 5 or 6 weeks, and less frequently at the end of the second or the beginning of the third month. The tubal pregnancy may terminate either by a tubal abortion or rupture of the tube.

In a *tubal abortion* the conceptus is separated from the tubal wall (Fig. 222, *a*), dies, becomes soaked in blood and disintegrates gradually. The tube de-

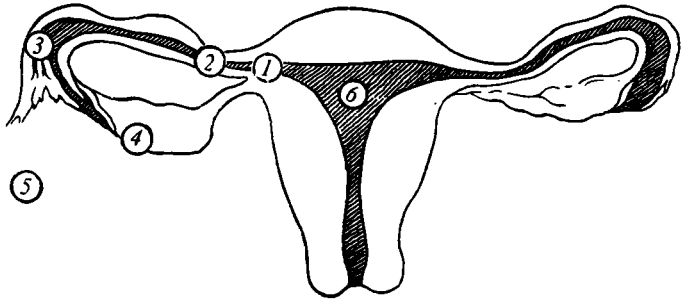

Fig. 221. Egg implantation in ectopic pregnancy:
1 — interstitial portion of the tube; *2* — isthmic portion of the tube; *3* — ampullar portion of the tube; *4* — ovary; *5* — abdomen; *6* — uterus

velops intense contractions by which the conceptus is extruded from the open end of the tube into the abdominal cavity (Fig, 222, *b*). The separation of the conceptus is attended with bleeding; the blood is accumulated round the tube or inside it. If haemorrhage is intense, the blood is accumulated in the cul-de-sac (Douglas' pouch) to form a haematoma. In very rare cases the foetus does not die and implants in the abdominal cavity thus causing abdominal pregnancy.

Rupture of the tube. The tube ruptures when all its layers (mucosal, muscular and peritoneal coats) are destroyed by the chorionic villi (Fig. 223). The mechanical distention of the tube by the growing foetus is not decisive; it is the chorion that destroys all tissues of the tube and the blood vessels. The rupture of the tube is usually attended with profuse bleeding into the abdominal cavity and development of acute anaemia. The loss of blood in a tubal abortion is rarely so acute.

Clinical picture. The symptoms of ectopic pregnancy are varied and depend on the pregnancy term, the type of pregnancy termination (tubal abortion or the rupture), the intensity of the internal bleeding, and the response of the body to the blood loss.

As ectopic pregnancy occurs it is first manifested as normal pregnancy, i.e. signs characteristic of normal early pregnancy develop: change in tastes, nausea, engorgement of the breasts, the absence of menstruation, cyanosis of the vaginal mucosa and the uterine cervix. The uterus consistency is usually soft and its size slightly enlarged: a slightly thickened pregnant tube can sometimes be palpated.

Diagnosis of progressing extrauterine pregnancy is difficult. Signs characteristic of ectopic pregnancy become only marked in a tubal abortion or in the rupture of the tube. The clinical picture of disorders of extrauterine pregnancy also varies: the symptoms are more marked and vivid in the rupture of the tube than in a tubal abortion.

The *rupture of the tube* is characterized by an abrupt onset and rapid progress of a grave clinical picture: the patient develops attacks of severe lower abdominal pain that may be attended with syncope. The pain irradiates into the shoulder, the shoulder blade and the anus. Due to the increasing blood loss the skin and the visible mucosa become pallid, the pulse accelerates, and the arterial pressure drops. The respiration rate increases. Grave cases are characterized by vomiting, sweat-

ing and fall of body temperature. The abdomen swells, the palpation becomes painful, the Shchetkin-Blumberg sign is positive. Percussion sounds are dull in the areas of accumulation of the blood (in the sloping areas of the abdomen and the areas adjacent to the groins); when the patient is turned to her side, the percussion tones change because the blood inside the abdomen flows to the lower regions.

The clinical picture of a *tubal abortion* is less dramatic. The skin and the visible mucosa are usually pale too, but the pulse and the arterial pressure do not drop so markedly. Unilateral pain resembling that of labour and attended with nausea and dimness of vision is typical. The pain irradiates into the shoulder blade, the neck, the anus, and the vagina.

Scanty bloody discharge, sometimes tar-like in appearance, is characteristic of terminated extrauterine pregnancy; the vaginal discharge often contains particles of disintegrated endometrium which turns into the decidua during extrauterine pregnancy; the entire decidua is sometimes discharged from the uterus.

Cyanosis of the vaginal mucosa and the cervix are common signs; the cervix usually protrudes anteriorly and palpation of the posterior fornix is often painful. The uterine body is slightly enlarged and softened.

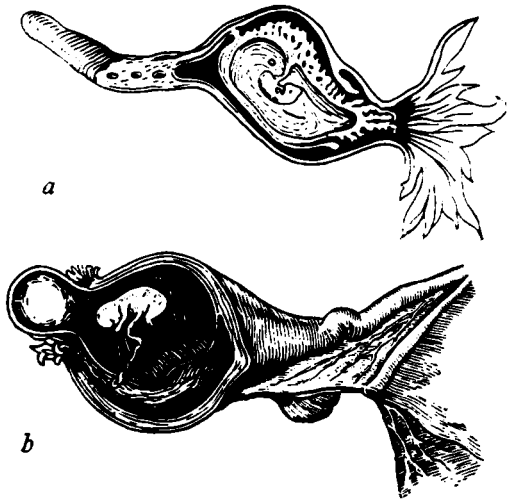

Fig. 222. Tubal abortion:
a — separation of the egg from the tube wall;
b — extrusion of the conceptus

If blood clots are formed inside or round the tube, a tender formation of irregular and indistinct shape can be palpated. If haematoma develops in the cul-de-sac, the posterior fornix becomes effaced or protruded and the uterus is displaced anteriorly. When the tube ruptures, the blood is discharged into the abdominal cavity and the preg-

Fig. 223. Rupture of the tube

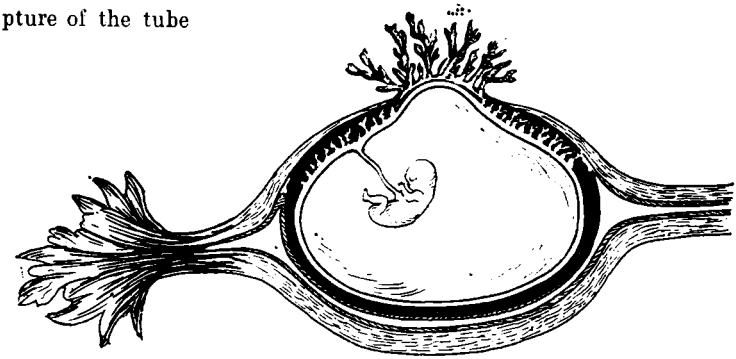

nant tube becomes impalpable or palpable with difficulty.

If the symptoms are pronounced the diagnosis of extrauterine pregnancy is not difficult to establish, but when the clinical picture is not marked and the condition of the patient is not grave, diagnostic difficulties arise. Thus a tubal abortion is sometimes difficult to diagnose if the blood loss is insignificant. Extrauterine pregnancy should then be differentiated from inflammatory diseases, abortion, appendicitis.

The study of the history is important in differential diagnosis of extrauterine pregnancy. In contrast to an inflammatory process, appendicitis and other diseases, extrauterine pregnancy is characterized by attacks of pain and blood smearing (dark bloody discharge) which appear after a missed period (in a few days following the expected menses). A detailed objective examination of the patient is very important. In doubtful cases additional diagnostic methods, such as the puncture of the cul-de-sac through the posterior fornix, immunological tests, etc., should be used. The blood obtained by puncture confirms the diagnosis of extrauterine pregnancy, but the negative result does not rule out extrauterine pregnancy because blood often clots round the tube and does not enter the cul-de-sac.

Treatment. Extrauterine pregnancy is treated surgically by removing the pregnant tube. The patient is operated immediately after the diagnosis has been established, even if the condition of the patient is only satisfactory, because the haemorrhage into the abdominal cavity may recur at any moment. If the clinical picture is grave, the patient is operated urgently, with transfusion of blood; cardiac drugs and other means to control anaemia and shock are used.

Bearing in mind the special danger to which the woman is exposed during extrauterine pregnancy, she should be examined by a specialist immediately when suspicion arises. If signs of terminated extrauterine pregnancy appear, the patient should immediately be delivered to the hospital by any possible means (by air, car, etc.). An obstetrician should accompany her to the hospital.

Ovarian and abdominal pregnancies occur rarely. The clinical picture of an ovarian pregnancy is similar to that of the tubal pregnancy. Abdominal pregnancy usually does not continue for considerable periods of time, but still cases have been reported on full-term abdominal pregnancy. The foetus, inside the membranes, grows in the space between the internal organs, the placenta being attached to the tube, the peritoneum or the inner organs. The pregnancy is pathological and the foetus would normally die. The dead foetus macerates and undergoes aseptic disintegration or mummification. Cases have been reported in which the dead foetus was macerated and necrotized due to the entrance of infection from the intestine. Considerable intra-abdominal haemorrhage may occur in connection with separation of the placenta.

Ovarian and abdominal pregnancies are treated surgically.

Prophylaxis of extrauterine pregnancy consists in control of infantilism (protection of children's health), inflammatory diseases, and abortions (contraceptives, health education which often provoke inflammatory diseases.

The patient operated for extrauterine pregnancy requires treatment aimed at prevention of its recurrence.

Chapter Twenty

PLACENTA PRAEVIA. PREMATURE SEPARATION OF NORMALLY IMPLANTED PLACENTA

Placenta praevia develops when the impregnated egg implants on or near the isthmic part of the uterus. The growing placenta thus covers a portion of the lower uterine segment to close (partly or completely) the internal os of the uterus and underlie the presenting part.

The following types of placenta praevia are distinguished:

1. Marginal placenta praevia. The placenta does not extend beyond the margin of the internal os. When the endocervical canal opens to pass two or three fingers, smooth membranes and a narrow margin of the placenta can be palpated (Fig. 224, *a*).

2. Lateral placenta praevia. The placenta covers the internal os by its margin and can be palpated by the examining finger (with the cervix dilated to pass 2 or 3 fingers) along almost the entire area except a small portion where the membranes show (Fig. 224, *b*)

3. Complete, or central, placenta praevia. The centre (or almost the entire central part) of the placenta covers the internal os. When the cervix is dilated to pass 2 or 3 fingers, the placenta alone can be palpated (Fig. 224, *c*) It is impossible to establish with certainty by the vaginal examination if the centre of the placenta lies over the internal os. The diagnosis of central placenta praevia is always stated in cases where the placenta alone can be palpated through the cervix dilated to pass 2 or 3 fingers.

4. Low attached type is also distinguished. The placenta is attached in the lower uterine segment but its margin is impalpable by the examining finger even if the cervix is fully dilated. (Low implantation of the placenta.)

One type of placenta praevia sometimes passes to another during labour. For example, when the internal cervix is only slightly dilated (to pass 1 or $1^1/_2$ finger) a small margin of the placenta can only be palpated (the marginal placenta praevia), but as the cervix is further dilated, a considerable portion of the placenta becomes palpable, i.e. the marginal placenta praevia turns into the lateral placenta praevia.

Since this classification is only schematic and conventional, some authors suggest that *total* and *partial placenta praevia* should only be differentiated. If the placental tissue alone is palpable through the cervix dilated to pass 2 or 3 fingers, the placenta praevia is referred to as total, and if both the placenta and the membranes can be palpated through the cervix, this would be referred to as partial placenta praevia.

In very rare cases implantation occurs in the *cervix*, and the placenta grows and develops in the endocervical canal of the uterus (or in the upper cervix and the isthmus)*.

* *Cervical pregnancy* is a rare and grave complication. The fertilized egg grows in the cervix which becomes softened, cyanot-

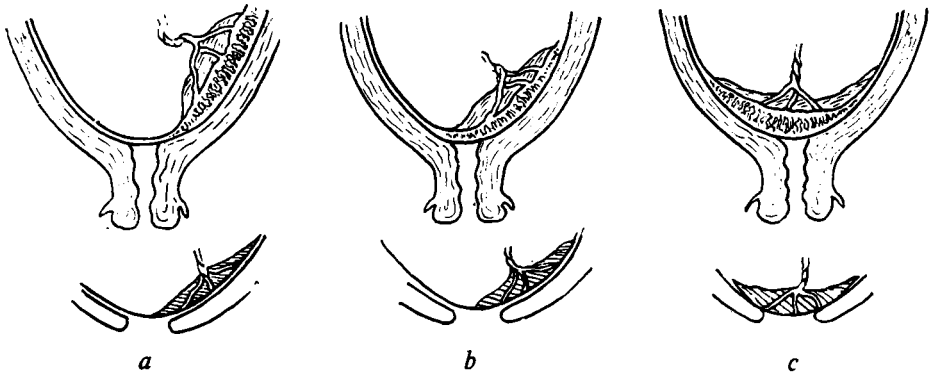

Fig. 224. Placenta praevia:
a — marginal; *b* — lateral; *c* — central

Aetiology. The egg would usually implant in the endometrium in the upper uterine segment at the level of the tube insertion. Placenta praevia develops when the egg implants in the lower uterine segment.

Inflammatory, atrophic and other pathological processes favour the implantation of the egg in the lower uterine segment and the development of placenta praevia. When the endometrium is affected by pathology, the conditions for normal implantation are impaired and the egg descends to the lower uterine segment, and implants near the internal os. Placenta praevia may develop as a result of septic or gonorrhoeal endometritis; abortions, especially repetitive, and abortions complicated with inflammatory diseases also predispose the patient to placenta praevia. Chorionic villi may develop over a considerable area and occupy the region adjacent to the decidua basalis, extending over the region of the decidua capsularis. This propagation of the chorionic villi will stimulate the growth of the placenta to reach the internal os and cover it.

Sequelae of placenta praevia. The condition is unfavourable for both the mother and the foetus. The central (total) placenta praevia is especially dangerous.

The blood vessels of the lower uterine segment in patients with placenta praevia are markedly dilated, elongated, and contain much blood. The uterine cervix is richly permeated with blood vessels so that the cervical tissue becomes very much like cavernous. It is now very soft and can be easily injured by careless manipulations. The broken vessels begin bleeding and the haemorrhage may become profuse and fatal to the woman. In the latter months of pregnancy the lower uterine segment widens to accommodate the lower pole of the foetus with the presenting part. The wall of the lower uterine segment is distended and misaligned with the placental surface so that parts of the placenta are separated from the uterine wall and the uteroplacental vessels thus break and begin bleeding.

Bleeding in placenta praevia may

ic and flask-shaped. The cervical pregnancy usually terminates prematurely and this is marked by profuse bleeding. The patient is treated by the extirpation of the uterus.

begin in late pregnancy and intensify during labour. Haemorrhage sometimes begins with the onset of regular contractions. Due to muscular retraction the lower uterine segment and the margins of the cervical os are pulled off from the placental surface to cause its separation from the site of attachment (Fig. 225). The stronger contracts the uterus and the wider opens the cervix the higher the degree of placental separation will be. The blood vessels break in the region of the placental separation and fatal bleeding may sometimes develop. The foetal blood circulation is not however affected since these are the maternal vessels that break, but the foetus still can develop asphyxia due to the decreased area of the placenta involved in the gas exchange of the foetus. Prognosis for the foetus in placenta praevia is always aggravated because an operation may often be necessary and this adds to the danger.

Placenta praevia favours the development of infectious diseases. Blood coagulated at the site of placental separation is a good nutrient medium for the propagation of microbes that may enter from the vagina. Anaemia, which weakens the body resistance to infection, is also harmful.

The villi of placenta praevia can sometimes grow very intensely to complicate the course of the placental stage of labour (the separation of the placenta is delayed and blood loss increases).

Placenta praevia is encountered in approximately one out of 500-600 parturients. This pathology is more likely to occur in multiparas with post-abortion or post-partum inflammatory diseases in past history. The central placenta praevia occurs much less frequently than the marginal or lateral placenta praevia.

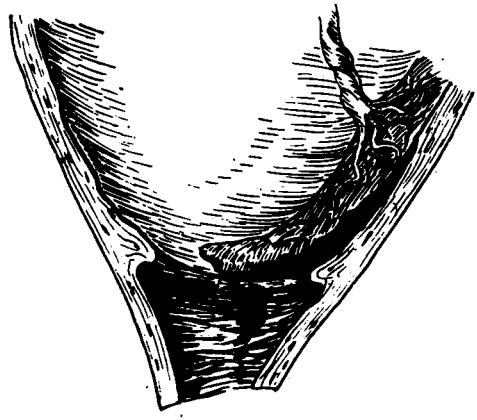

Fig. 225. Retraction of the uterine muscles always causes separation of placenta praevia and bleeding

Clinical picture. The main sign of placenta praevia is vaginal bleeding. In the central placenta praevia bleeding begins during the last two or three months of pregnancy; in the lateral attachment bleeding begins at the end of pregnancy or at the beginning of labour, and in the marginal placenta praevia, during the first stage of labour. In low attachment type of placenta praevia bleeding begins also during the dilation stage and is usually not pronounced.

Bleeding in late pregnancy usually begins unexpectedly, without any visible cause, sometimes during night rest. The bleeding is painless; sometimes it appears as lengthy smearing, and sometimes as a single bloody discharge (with clots) followed by cessation of bleeding and unwarned recurrence in an uncertain lapse of time. Intermittent bleeding may persist till labour. Bleeding is sometimes rather intense and urgent labour is then indicated.

In central placenta praevia bleeding intensifies with the onset of regular contractions; the blood is bright and

liquid, sometimes containing clots; it is discharged in large portions or continuously. The blood loss may amount to one litre and over, and the bleeding may become fatal provided the patient is not given timely aid. If bleeding in lateral placenta praevia begins during pregnancy, it intensifies during labour as well and its character may become fatal. Bleeding is not usually dangerous in marginal placenta praevia; it begins during the dilation stage of labour. When the membranes rupture, the separation of the placenta discontinues, the head becomes engaged in the pelvis to compress the placenta, and the bleeding thus stops.

A pronounced symptom of placenta praevia is anaemia, the degree of which depends on the intensity of the vaginal bleeding. The skin and the mucosa turn pale, the pulse accelerates; if bleeding is excessive, the arterial pressure falls, vertigo, noise in the ears and dimness in the eyes develop, and the woman may die should the medical aid be delayed.

Placenta praevia interferes with the descent of the head into the lower uterine segment. The head therefore remains floated high above the pelvic inlet till the end of pregnancy or it may deviate to the either side of the vertical line. Placenta praevia contributes to the incidence of abnormal presentations (breech, oblique, transverse). Premature labour, uterine inertia, and changes in the foetal heart tones are not infrequent.

Diagnosis. Late pregnancy bleeding, as well as bleeding during the first stage of labour, may be the sign of placenta praevia. Painless bleeding without warning and in the absence of trauma is in most cases caused by placenta praevia. The high level of the presenting part in a normal bony pelvis confirms the suspected diagnosis.

The diagnosis should be verified by a careful vaginal examination which should be performed by a physician in the hospital with strict observation of the aseptic requirements. Careless examination may provoke further separation of the placenta and intensify bleeding. When the cervix opens, soft tissue can be palpated by the examining finger in the immediate vicinity of the internal os margin; in partial placenta praevia the membranes can be palpated together with the placenta through the cervix. The examining finger should not reach beyond the margin of the internal os because this may intensify separation of the placenta and bleeding.

In order to establish a definite diagnosis and to rule out other sources of bleeding (cancer, polyps, rupture of a varicosity, trauma) the woman with bleeding should be given a speculum examination.

Vesicography is sometimes used to confirm the diagnosis: a contrast substance is introduced into the bladder and the distance from the bladder to the foetal head is measured on an X-ray pattern. The distance increases in placenta praevia.

Treatment. Bleeding during the second half of pregnancy is an indication for an *emergency hospitalization of the pregnant.* Even if the bleeding is not prolonged or intense, the pregnant should be delivered to the hospital under observation of the obstetrician since bleeding may at any time recur and become fatal.

Various obstetrical manipulations and other medical measures should be undertaken in placenta praevia. The most suitable method of treatment should be selected in each particular case, taking into consideration the fo-

lowing factors: the amount of the blood shed, the degree of the anaemia developed, preparedness of the birth canal for delivery, and the status of the foetus (viability, asphyxia, etc.). Depending on these factors some women may be treated conservatively while others should immediately be given an urgent surgical aid, the caesarean section included.

Conservative treatment is indicated during pregnancy with insignificant blood loss (which does not evoke anaemia). Bed rest. repetitive transfusion of small doses of blood and diet rich in vitamins are prescribed. The status of the pregnant should be strictly observed: her pulse rate and arterial pressure should be taken regularly, her vaginal discharge inspected, and the blood samples analysed to prevent anaemia which can develop in scanty but prolonged haemorrhage.

If bleeding persists and haemoglobin and erythrocyte counts fall, operative delivery is indicated. In cases with profuse haemorrhage the patient should be operated on immediately for vital indications.

One of the following operations should be used depending on the bleeding intensity, the status of the patient, the type of placenta praevia, etc.

Rupture of foetal membranes. The foetal membranes are recommended to be ruptured in marginal placenta praevia with longitudinal presentation and with the cervix dilated to pass 2 or 3 fingers. If intense bleeding, or other indications for urgent delivery are absent, the membranes can also be ruptured in lateral placenta praevia as well.

After the rupture of the membranes the placental separation discontinues, the head descends into the pelvis to compress the placenta praevia and thus

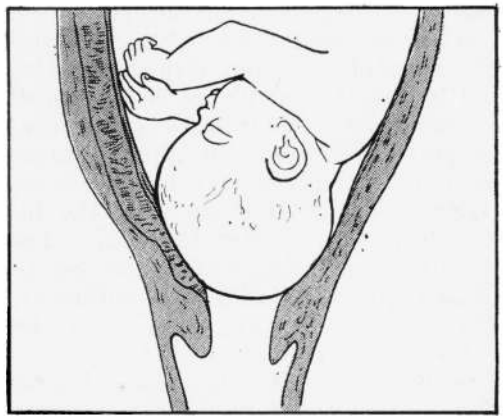

Fig. 226. After the rupture of the membranes, the head descends into the pelvis to compress the placenta praevia and the bleeding vessels

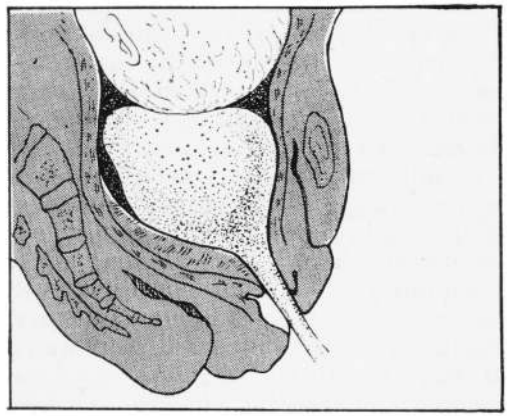

Fig. 227. Placenta praevia compressed by a metreurynter

to stop bleeding (Fig. 226). The further labour is spontaneous. The membranes are often ruptured as a preparative step to some other operation (metreurysis, application of forceps, etc.).

Metreurysis. After the membranes have been punctured, a sterile pear-shaped rubber bag, known as a metreurynter (or Voorhees' bag), is introduced

into the uterus (in the coiled state). The bag is then inflated with a physiological saline solution through a tube, and a weight (200-400 g) is suspended by the tube. The inflated metreurynter presses by its weight the separated portion of the placenta to the lower uterine segment thus ensuring the intrauterine tamponade (Fig. 227). The bleeding discontinues and the cervix dilates. When the dilation is sufficient, first the metreurynter and then the foetus are delivered.

Metreurysis is usually used in lateral (less frequently in marginal) placenta praevia when, after the rupture of the membranes, the head fails to descend and bleeding persists. This situation may occur in placenta praevia concurrent with uterine inertia.

Forceps delivery. If the head does not descend after the rupture of the membranes in marginal and lateral placenta praevia and the bleeding persists, obstetric forceps can be applied. The skin fold on the foetal head is taken by the forceps of special design and a small weight (200-400 g) is hanged by the forceps handle to pull the head down into the pelvis. The engaged head presses the placenta against the lower uterine segment and the pelvic walls to stop bleeding. After the head is engaged and bleeding stopped, the forceps are removed and labour is continued spontaneously.

Podalic version with incomplete dilation of the cervix (Braxton Hicks' version). The Braxton Hicks version was often performed in past years when the cervix was dilated only enough to admit 2 or $2^1/_2$fingers. The foot of the foetus was extracted from the pudendal cleft to the knee level with subsequent traction by a small weight (200-400 g). The pelvic end of the foetus would descend to press the placenta against the lower uterine segment and the pelvic bones to discontinue bleeding (Fig. 228). The Braxton Hicks version is now rarely used with incomplete dilation of the cervix (only if the foetus is dead or premature, or if other obstetrical operations cannot be performed) because of its complexity: the cervix may be easily injured, or the foetus may be born dead.

The cervix may be ruptured in placenta praevia even by a moderate effort with development of fatal bleeding. The version should therefore be performed very carefully without traction by the foot or extraction of the leg above the knee. Extraction of the foetus by the leg is prohibited: the cervix will rupture and fatal bleeding develop.

Caesarean section. Placenta praevia is frequently an indication for an abdominal hysterotomy. This operation is performed in urgent cases with profuse bleeding which usually occurs in the central (total) and sometimes lateral placenta praevia.

Caesarean section is indicated also in placenta praevia concurrent with malpresentation of the foetus, and also in 'elderly' primiparous women (provided they insist on delivery of a live infant).

Patients with placenta praevia should be treated during labour and post partum by blood transfusion, subcutaneous administration of physiological saline solution with glucose in order to prevent anaemia; cardiac drugs should also be given.

The puerperium in patients with placenta praevia is often complicated: the placental stage is prolonged because the placenta is attached in the lower uterine segment whose contractions are not intense. The placenta may be partly adherent. The abnormal separation of the placenta provokes more intense

bleeding which may endanger the mother.

The general status of the woman, her pulse and arterial pressure should therefore be constantly observed and the amount of the blood lost strictly accounted. If the blood loss exceeds the allowable limit and anaemia develops, manual separation of the placenta should be performed immediately. After the placenta has been removed, the uterine cervix should be examined with specula and lacerations, if any, sutured.

Infectious diseases may develop post partum because the placental site is close to the vagina and the resistance of the woman is impaired after loss of blood. The puerpera reguires careful attendance and observation. General tonics and repeated blood transfusion are prescribed if necessary. Diseases of infectious aetiology should be appropriately treated.

Premature Separation of the Normally Implanted Placenta

In normal pregnancy and labour the placenta remains attached to the wall of the upper uterine segment till the third stage of labour; it begins only separating after the foetus has been expelled and the uterus begins contracting with the fall of the intrauterine pressure.

In certain pathological conditions the normally implanted placenta begins separating before the foetus is delivered (premature separation). This usually occurs during the first (dilation) stage of labour; it rarely occurs during the second stage or else during pregnancy.

Aetiology. The most frequent cause of premature separation of the placenta is associated with diseases attended

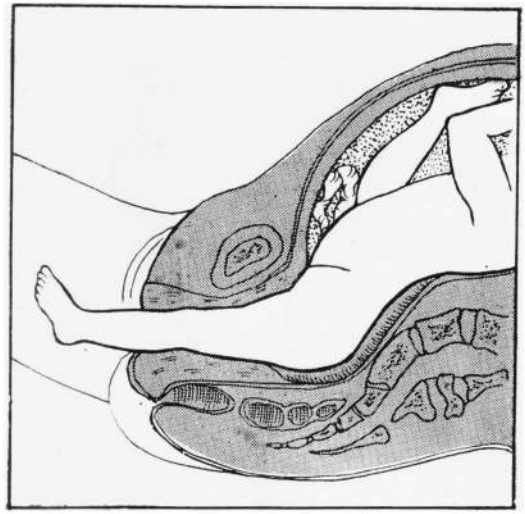

Fig. 228. Placenta praevia is compressed by the foetal pelvis (after podalic version with half-dilated cervix)

with vascular disorders. These are late pregnancy toxaemia, nephritis, hypertension, heart diseases, lack of vitamin C, etc. Changes in the placental vessels induced by these disorders provoke haemorrhage in the placenta. Blood accumulates in the space between the uterine wall and the placenta to initiate its separation from the attachment site.

Endometritis in the pre-conception history is a predisposing factor. The placenta may be separated during the second stage of labour either because of a short umbilical cord that pulls the placenta down during the expulsion of the foetus, or because of strong membranes (delayed rupture): the delivered membranes pull the placenta. The placenta may be separated prematurely in twin birth after the delivery of the first foetus.

Injuries of the abdomen can be regarded as a rare cause of premature placental separation.

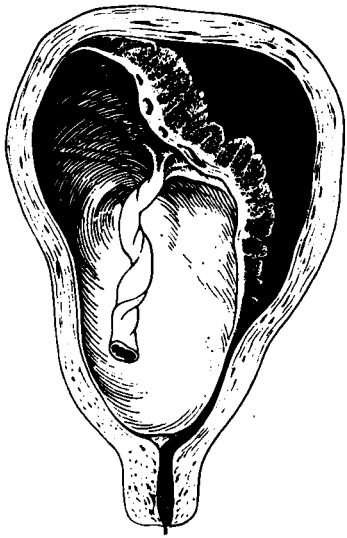

Fig. 229. Premature separation of the normally implanted placenta (internal and external bleeding)

Disorders associated with premature separation of the placenta. Complete and partial premature separation of the placenta are differentiated. If the placenta is separated before labour or over a small area (partial separation) it does not evoke severe disorders in the woman, and the pregnancy can be saved. The premature separation of the placenta will then be diagnosed only after the delivery of the placenta: the maternal surface of the placenta bears an old clot of coagulated blood.

In complete or partial (but over a considerable area) separation of the placenta, a rapidly growing haematoma, which develops between the uterine wall and the separated portion of the placenta (Fig. 229), promotes its further separation. The uterine wall protrudes in the region of the haematoma. As bleeding continues the blood penetrates the space between the uterine muscles and reaches the serous coat of the uterus. Premature separation of the placenta is attended with intrauterine bleeding. but as the retroplacental haematoma develops, the blood finds the way out between the uterine wall and the membranes in the direction of the uterine cervix and premature separation of the placenta is therefore manifested in the external bleeding as well. The vaginal bleeding is however not intense even with considerable retroplacental haematoma and acute anaemia.

Complete and partial separation of the placenta endanger the mother and the foetus: the woman may die from excessive blood loss and shock associated with overdistention of the uterus, while the foetus often dies from asphyxia. The danger of the foetal distress arises when a third of the placenta separates. If half of the placenta (to say nothing of the entire placenta) has been separated, the intrauterine foetus quickly dies.

The clinical picture of complete or partial separation of the placenta is characterized by some severe symptoms:

1. The woman complains of strong and persistent abdominal pain; the skin and the mucosa are pale; the pulse is soft and accelerated; the arterial pressure falls. Vertigo, noise in the ears and other symptoms of acute anaemia may develop though external bleeding might be insignificant.

2. The growing retroplacental haematoma increases the intrauterine pressure and causes excessive distension of the uterine walls. The uterus grows in size, its consistency becomes firm (may be as hard as wood), and the shapes become ovoid or irregular. In complete placental separation the uterus may become asymmetrical because of protrusion of its wall at the site of haema-

toma. The palpation of the uterus is very painful.

3. Small foetal parts become impalpable because of the excessive strain of the uterine muscles; the foetal heart tones become irregular or discontinue; the motion of the foetus is absent.

4. If the woman is in labour, the foetal membranes are very tense both during the contractions and in the pauses.

The separated placenta is delivered immediately after the foetus. Large amounts of liquid blood and clots are discharged together with the placenta.

The overdistended uterus shrinks slowly and the bleeding therefore often continues during the first hours post partum due to uterine atony.

Haemorrhage in the placental and early puerperal periods may be due to disorders in the blood coagulating system (penetration of substances decreasing coagulability of blood from the placental tissues).

Treatment. Urgent obstetrical aid is required. The following main principles underlie the treatment of premature placental separation: (1) sparing stimulation of complete vaginal delivery; (2) control of acute anaemia and shock.

The choice of the method of delivery depends on the degree of anaemia and the conditions for obstetrical operations.

If the placenta is separated during pregnancy or in the beginning of labour (dilation stage), a caesarean section is indicated because the foetus cannot be born rapidly by normal delivery through the natural birth canal.

If the cervix is fully dilated, the foetal membranes should be ruptured, the foetus turned (podalic version) and extracted from the birth canal. The placenta should then be immediately removed.

If the foetal head has entered the pelvic cavity and the foetus is alive, obstetrical forceps should be applied. If the foetus is dead, the head should be perforated and the foetus extracted quickly using a cranioclast.

If the cervix is not fully dilated, the blood loss is not considerable, and the condition of the mother and the foetus is satisfactory, the foetal membranes are ruptured. After the rupture of the membranes further separation of the placenta may discontinue and the labour may end by normal delivery. If the contractions are not strong enough, metreurysis is indicated to stimulate the uterine contractions and thus to accelerate labour.

Along with obstetrical aid, the woman should be treated from blood loss and shock. To that end blood transfusion and infusion of a physiological saline solution with glucose are prescribed. The woman is also given cardiac drugs and is warmed. Strong tea or coffee should be given as well. The condition of the woman is watched during the first hours post partum, the uterus is inspected, the amount of blood discharged from the vagina is counted. If uterine atony (or hypotony) develops, steps should be taken to stimulate uterine contractions and cessation of bleeding (see Ch. 25).

The obstetrician should reveal in due time diseases that predispose the pregnant to premature separation of the placenta (late pregnancy toxaemia, diseases of the kidneys, etc.) and send the woman to the doctor.

Chapter Twenty-one

DYSTOCIA AND ABNORMALITIES IN SOFT TISSUES OF BIRTH CANAL

Functional Dystocia

Dystocia, or difficult labour, is usually associated with uterine inertia. Extremely forceful labour occurs in rare cases. *Primary* and *secondary uterine inertia* are distinguished.

Primary uterine inertia is characterized by inefficient contractions from the very beginning of labour. The contractions are weak and short, while the pauses between them are long. Frequent but ineffective contractions may also occur.

Secondary uterine inertia develops as a result of fatigue of the parturient and exhaustion of the contractile force of the uterus in prolonged labour, though the contractions might be quite forceful at the beginning of labour.

Primary Uterine Inertia

Uterine inertia may be caused by the lack of oestrogen, pituitrin, acetylcholine and other substances that initiate and intensify uterine contractions. Decreased reactivity of the uterus, which is associated with the altered function of the nervous system, is also important. Primary uterine inertia occurs in general asthenic conditions, endocrine disorders, infantilism, malformations of the genitalia (uterus bicornis, uterus unicornis), myoma of the uterus, and in obesity.

Previous abortions and inflammatory diseases of the genitalia can also be the cause of uterine inertia. Ineffective contractions of the uterus can also be due to overdistention of the uterus in multiple pregnancy and polyhydramnios. Uterine inertia often occurs in premature discharge of the amniotic fluid in the absence of the amnion which stimulates the nerve elements of the uterine cervix and intensifies the uterine contractions.

Primary uterine inertia may last to the second stage of labour to become responsible for ineffective abdominal contractions. Labour thus becomes markedly prolonged. Complications often develop during labour and post partum: foetal asphyxia, considerable bleeding in the placental and early puerperal period, retention of the placenta or its separate parts in the uterus. If uterine inertia develops against the background of premature (early) discharge of the amniotic fluid, endometritis of labour and puerperal diseases connected with the spreading of uterine infection often develop.

Treatment. Primary uterine inertia is difficult to manage. First of all the cause of uterine inertia should, if possible, be established and the appropriate treatment then given.

The condition of the amnion is very important in selecting the method of conducting labour. If the amniotic fluid is not discharged, treatment may be conservative. The patient may be treated conservatively with the discharged

amniotic fluid as well, but conditions necessitating abdominal delivery often arise.

The usual supportive measures are very important in the management of uterine inertia: high-calory food, tea, coffee, fruit juice, etc., timely evacuation of the bowels and the bladder, favourable stimulation of the parturient psyche (removal of fears and other distressing emotions). If the membranes are intact, the parturient is allowed to leave her bed and walk. If the contractions fail to become more intense, the uterus is stimulated by drugs. The stimulants usually intensify the uterine contractions and normalize labour. But after stimulation of uterine contractility, the parturient is often fatigued and the contractions weaken. The woman should then be given rest for several hours provided there are no indications for urgent delivery.

In considerable fatigue the parturient is given subcutaneously promedol (2 per cent solution, 1 ml) or pantopon (1 ml of a 1 per cent solution). After an injection the patient is given rest for several hours which favours intensification of the uterine contractions. If uterine inertia is due to overdistention of the uterus (multiple pregnancy, polyhydramnios), amniotomy is indicated with dilation of the cervix (to admit 2 or 3 fingers). After the discharge of the amniotic fluid, excessive distention of the uterus disappears, its walls thicken and the uterine contractions are intensified.

Uterine contractions can be stimulated by different methods. The following schemes are usually used.

Scheme One (Kurdinovsky and Shtein). Castor oil, 50-60 g per os; a cleansing enema in two hours. Quinine, 0.2 g, six times at 30-minute intervals (after enema). In 15 minutes after the 3rd, 4th, 5th and 6th dose of quinine follow pituitrin injections (subcutaneously 0.25 ml, four times).

If the membranes are intact, 40 000-50 000 units of folliculin or sinestrol intramuscularly may be given at the very beginning of labour. Sinestrol and folliculin increase sensitivity of the uterus to quinine, pituitrin, and other uterine stimulants. Castor oil is given in an hour after the administration of folliculin, then given are cleansing enema, quinine and pituitrin (in the above specified doses).

Scheme Two (A. P. Nikolaev). Castor oil (60 g) per os, then (in an hour) quinine, five 0.2 g doses at a 30-minute interval. After the 5th administration of quinine, a cleansing enema is given followed by an intravenous injection of 50 ml of a 40 per cent glucose and 10 ml of a 10 per cent calcium chloride solutions. Vitamin B_1 (60 mg) should be given simultaneously (intramuscular injection).

Scheme Three (V. N. Khmelevsky). A mixture of 50 g of glucose, 2 g of calcium chloride, 0.5 g of ascorbic acid, 0.03 g of vitamin B_1, 10 drops of dilute hydrochloric acid, and 150 ml of water are given per os in a single dose. The mixture can be given in three hours again.

Oxytocin and prostaglandin have been recently used as uterine stimulants.

Oxytocin is given intravenously with a glucose solution (5-10 units of oxytocin in 500 ml of 5 per cent glucose by instillation).

Proserine together with atropine hydrochloride can be given. Proserine (0.003 g) and atropine (0.002 g) should be given in powder form at an hour interval (4-5 times a day); pachycarpine (3-5 ml of a 3 per cent solution, intramuscularly), prostaglandins, and other stimulants are used as well.

Secondary Uterine Inertia

Secondary uterine inertia develops during the second (expulsive) stage of labour or at the end of the dilation stage following normal or satisfactory uterine contractions. The causes are varied. These are all pathological processes and special conditions that may cause primary uterine inertia (systemic and gynaecological diseases, infantilism, etc.). Secondary uterine inertia often develops in prolonged labour due to the general fatigue of the parturient and exhaustion of the contractile power of the uterus. Prolonged labour and secondary uterine inertia occur often in contracted pelvis, large foetus, malpresentations, rigid os, cicatricial narrowing of the vagina, or delayed rupture of the membranes. Secondary uterine inertia may be reflectory in connection with a full bladder or bowels.

Secondary uterine inertia often occurs after the discharge of the amniotic fluid and it is therefore often attended with intrauterine infection and foetal asphyxia. After the uterine contractions weaken or discontinue, the soft tissues of the birth canal, the bladder, the urethra, and the rectum will be compressed between the foetal head and the body pelvis. Prolonged compression interferes with normal circulation of blood and causes necrosis of tissues with subsequent formation of the vesicovaginal or rectovaginal fistulae.

Secondary functional dystocia requires careful observation of the woman (signs of infection, compression of soft tissues of the birth canal, etc.) and the foetus. Measures should be taken to control foetal distress and to intensify the uterine contractions.

If uterine inertia is due to delayed rupture of the membranes, amniotomy is indicated. When the cervix is fully dilated and the foetal head is engaged, 1 ml of pituitrin or 0.25 ml of oxytocin may be given subcutaneously which will rapidly stimulate uterine contractions. These stimulants should however be given with great precaution because they sometimes induce very forceful contractions to increase the risk of foetal distress. Therefore, when these drugs are given to the parturient, obstetrical forceps and scissors should simultaneously be prepared to perform perineotomy if the necessity arises. Pituitrin or oxytocin must not be used if the dilation of the cervix is not full, the foetal head stands high above the pelvic inlet, or the lower uterine segment is distended, because a sudden intensification of the uterine contractions may cause the rupture of the cervix or the thinned lower uterine segment.

If the head is engaged or descended into the pelvic outlet, or else in the presence of contraindications to the use of pituitrin (high arterial pressure), the patient should be delivered by forceps.

If labour becomes prolonged because of a rigid perineum, perineotomy is indicated. If the foetal head stands high and the condition of the mother and the foetus permits, uterine contractility should be stimulated by sweet tea or coffee, fruit juice, or 50 ml of a 40 per cent glucose solution and 10 ml of a 10 per cent calcium chloride solution (intravenously). Quinine (in divided doses) can be given per os.

If the parturient is fatigued and there are no indications for rapid parturition, the woman is allowed rest. She is placed in an isolated room and promedol or pantopon is given. The uterine contractions usually intensify after rest. If the effect is insignificant, the uterine contractions are stimulated.

Timely emptying of the bladder and the rectum is important to remove uterine inertia.

Dystocia and a prolonged expulsive period are often connected with defects of the prelum. Flaccid abdominal muscles, pendulous abdomen, obesity, hernia of the white line and other defects of the abdominal wall are responsible for the sluggishness of labour efforts. The Verbov bandage (Fig. 230) should be used in these cases. An obstetrician and her assistant assume their position on both sides of the parturient and pull on the bandage during uterine contraction to compensate for the lacking effort of the abdominal prelum (Fig. 231). The tension on the bandage is relaxed in the intervals between contractions.

A wide towel or a sheet may be used instead of the bandage (Fig. 232).

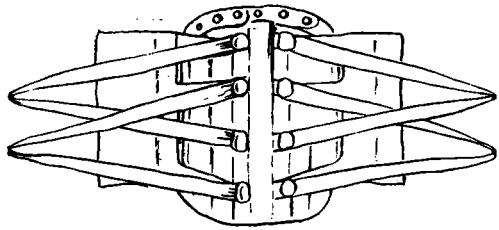

Fig. 230. Verbov's bandage

Desultory Labour

Uterine contractions may begin in its lower and not the upper segment. Regardless of regular and painful contractions, the cervix dilates at a slow rate and the progress of the presenting part is delayed. Desultory labour can be differentiated from uterine inertia by the study of clinical data and hysterography. Uterine stimulants should not be given in desultory labour. Sedatives (e.g. trioxazin) and spasmolytics (actozine, 2 ml of a 2 per cent solution) which promote dilation of the cervix, and also lydase or procaine hydrochloride injections into the cervix are recommended.

Precipitate Labour

Excessively forceful contractions occur less frequently than uterine inertia.

Fig. 231. Using Verbov's bandage

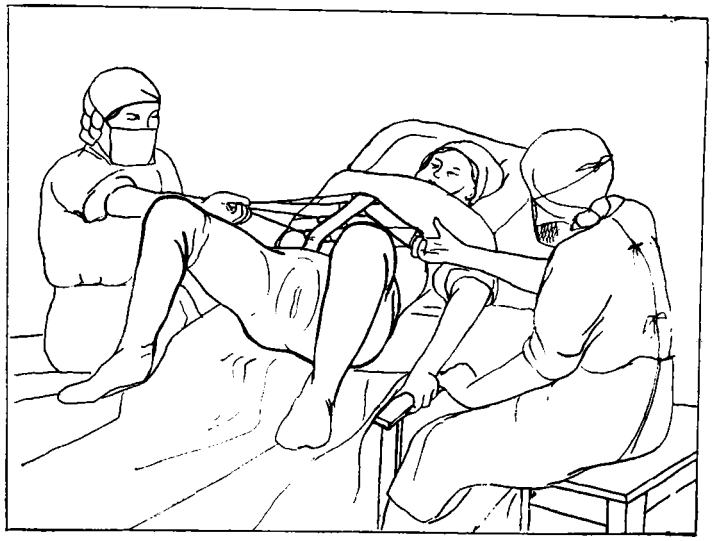

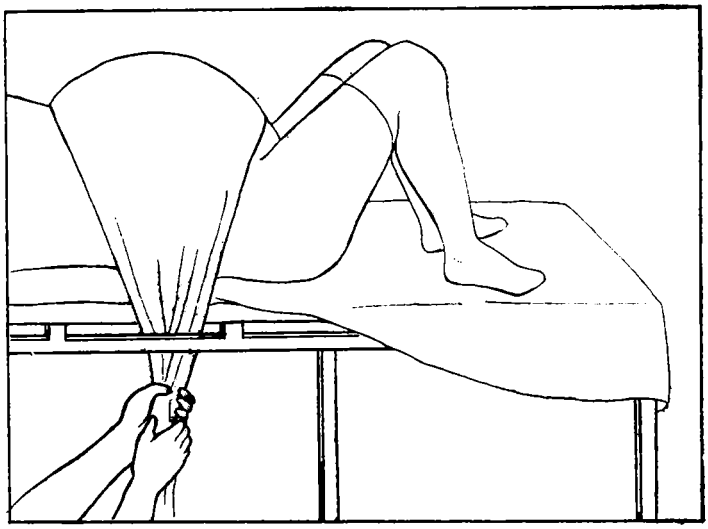

Fig. 232. Using a wide towel instead of Verbov's bandage

Violent and painful uterine contractions at short intervals develop in women with easily excitable nervous system, in patients with exophthalmic goitre and other neuroendocrine disorders. Violent contractions may develop in the presence of mechanical obstacles to the propulsion of the foetus through the birth canal, such as contracted pelvis, malpresentation of the foetus, etc. Under the impact of convulsive contractions the uterus may rupture. Secondary uterine inertia sometimes develops following excessively forceful onset of labour.

In the absence of cephalopelvic disproportion excessively forceful contractions may result in *precipitate labour*, which lasts only from one to three hours and therefore often occurs outside the hospital (at home, on the way to the hospital, etc.).

Precipitate labour outside the hospital ends in foetal asphyxia due to convulsive contractions of the uterus interfering with normal placental blood circulation. Intracranial injury may occur in connection with the rapid propulsion of the foetal head through the birth canal.

In excessively forceful labour the parturient should be placed on her side and pantopon (1 ml of a 2 per cent solution) or morphine (1 ml of a 1 per cent solution) should be given subcutaneously. Steps to prevent foetal asphyxia should be taken. In tumultuous contractions, which increase the risk of the uterus rupture (see Ch. 26), ether anaesthesia should be given. The perineum, the vagina and the uterine cervix should be inspected thoroughly after precipitate labour so that possible lacerations be not overlooked.

Abnormalities of Pelvic Soft Tissues

Normal labour is sometimes upset in connection with certain changes in the uterine cervix, vagina and the perineum. Scar tissue in the cervix and the vagina may present an obstacle to the passage of the foetus.

Changes in the cervix. The uterine cervix is often lacerated during labour, especially in pathological (operative) labour. When non-sutured lacerations heal, scars are formed which may interfere with dilation of the cervix in subsequent labour. Scar tissue is also formed after cauterization and plastic operations on the uterine cervix. The cervix with scars dilates slowly; painfulness and frequency of uterine contractions increase. If cicatricial changes are not pronounced, the cervix opens spontaneously though slowly, while considerable narrowings due to scar tissue will prevent dilation and impede labour; a recourse to the incision of the cervical os should therefore be made. The incisions should be remedied by suturing after delivery.

Cervix rigidity. Rigidity of the cervix is not infrequent, in 'elderly' primipara in particular; this condition occurs also in women with previous inflammatory diseases of the cervix.

The loss of elasticity and high resistance to distention slow down the dilation of the cervix and sometimes impede labour. When the cervix is dilated with difficulty, the frequency and painfulness of the uterine contractions increase. The dilation is very slow, the os margins are firm and the dilating fingers meet high resistance.

The rigid cervix should be dilated by the fingers or (if the amniotic fluid has escaped) using a metreurynter. If these measures fail, lateral incisions should be made.

Rigidity and firmness of the cervical os depend on the spastic state of the circular cervical muscles. Rectal administration of anaesthesizing suppositories with belladonna (0.02 g) or pantopon (0.015 g) is helpful.

Procaine hydrochloride solution injected into the uterine cervix (0.5 per cent solution) successfully removes the cervical spasms. The solution should be injected into the thick cervical tissue at 5-6 points; the total dose 50-60 ml.

Changes in the vagina and perineum. Defects of the vagina, such as congenital partitions or scar tissue which narrow the vagina, sometimes occur. The causes of these defects are varied: diphtherial vaginitis of childhood, accidental burns and other injuries are among possible causes.

Small partitions and scars are distended during labour and do not interfere with the expulsion of the foetus and the placenta. If scars are considerable, caesarean section is indicated. Partitions that may present an obstacle to the propulsion of the foetus are dissected.

Rigid perineum, which often occurs in 'elderly' primipara, sometimes interferes with the progress of the foetal head through the birth canal. The firm perineal tissue distends with difficulty and imposes obstacles to the head crowning. Labour is thus slowed and the risk of foetal distress increases. Tissues of the perineum that have lost their elasticity and distensibility undergo a higher risk of rupture. If a rigid perineum interferes with normal delivery, it should be incised. Perineotomy is especially indicated in the development of signs of threatened rupture of the perineum and in impairment of the foetal heart tones.

Chapter Twenty-two

TRANSVERSE AND OBLIQUE PRESENTATIONS. PROLAPSE OF EXTREMITIES AND UMBILICAL CORD

Transverse and Oblique Presentations

Presentation of the foetus in labour in which the long axis of the foetal body forms a right (or almost right) angle with the long axis of the uterus is called transverse. In oblique presentation the long axes of the foetal and maternal bodies intersect at an acute angle. The position of the foetus in transverse and oblique presentations is determined by the foetal head. The left and the right positions are thus distinguished (Figs. 233 and 234, respectively). The anterior or posterior presentation is differentiated by the position of the foetal back: if the back is turned anteriorly, the presentation is anterior, and vice versa (Figs. 233 and 234, respectively).

Oblique and transverse presentations are called malpresentations because spontaneous labour becomes infeasible with misalignment of the maternal and foetal long axes, and their lives are endangered unless proper medical assistance is given.

The causes of malpresentation are varied.

1. The conditions that facilitate *mobility* of the foetus in the uterus contribute to the risk of transverse or oblique presentation. These are polyhydramnios, flaccid abdominal wall, multiple pregnancy, especially in combination with polyhydramnios.

2. Transverse (oblique) presentation may occur in contracted pelvis, placenta praevia, and other conditions that interfere with the descent of the foetal head into the lower uterine segment and subsequent engagement.

3. Malformations of the uterus, for example, uterus arcuatus.

Diagnosis of transverse or oblique presentation is in most cases not difficult. The shape of the uterus is not ovoid but elongated in the transverse or oblique direction; the uterine bottom is lower than in longitudinal presentation. The foetal head and podalic pole can be identified by palpation in the lateral ends of the uterus (the head in the left side and the pelvis in the right side, and vice versa). There is no presenting part over the pelvic inlet. The foetal heart tones can be clearly heard at the level of the navel, closer to the head end of the foetus.

Vaginal examination during pregnancy and at the very beginning of labour fails to give positive evidence of transverse presentation. X-ray pelvimetry is therefore used in cases of doubtful diagnosis (uncertain palpation findings, polyhydramnios, etc.). Vaginal examination will only be useful in identification of oblique (transverse) presentation in labour after the rupture of membranes: a shoulder, rib, clavicular bone (in posterior position) or the shoulder blade or vertebral spines (in anterior position) can be palpated through the dilated cervix.

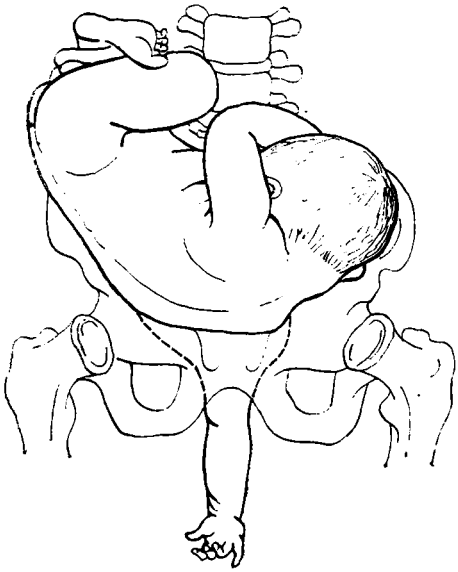

Fig. 233. Transverse left anterior presentation

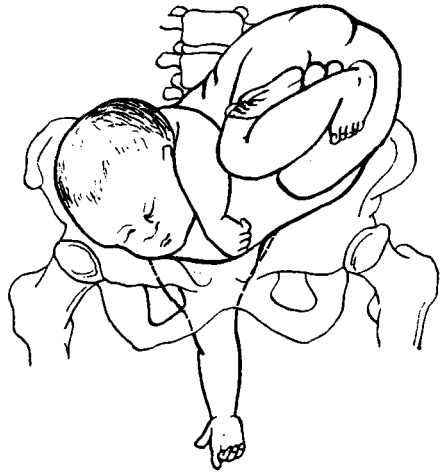

Fig. 234. Transverse right posterior presentation

The arm or the umbilical cord often prolapses in transverse or oblique presentation. When the arm prolapses, the armpit can easily be palpated, which will help determine the position of the foetal head: the head will be found in the direction where the armpit closes. If the armpit closes to the left, the presentation is anterior, and vice versa.

It is important to make sure what particular part of the foetal body has prolapsed into the vagina, the arm or the leg. The leg can be identified by the knee pan and the heel; all toes are about equal length and the first toe cannot be pulled aside. The hand is continuous with the forearm without pronounced flexures, the fingers are longer than the toes and the thumb can be easily separated and flexed on the palm. It is also necessary to determine whether the left or the right arm has prolapsed. To this end, it is necessary to try to 'shake hands' with the prolapsed arm. If it fails, the arm is left, and vice versa. Or the arm can be turned the palm up and the direction of the thumb will indicate whether the arm is left or right. Thus the prolapsed arm will help the obstetrician determine the presentation.

The prolapse of the right hand in the left position of the foetus indicates anterior presentation, and of the left, posterior presentation. The prolapse of the right arm in the right position will indicate posterior, and of the left arm, anterior presentation.

Labour in transverse (oblique) presentation is pathological. It is only in rare cases that the foetus changes its oblique or transverse position to the longitudinal one during the beginning labour (spontaneous version). In the overwhelming majority of cases the transverse (oblique) presentation per-

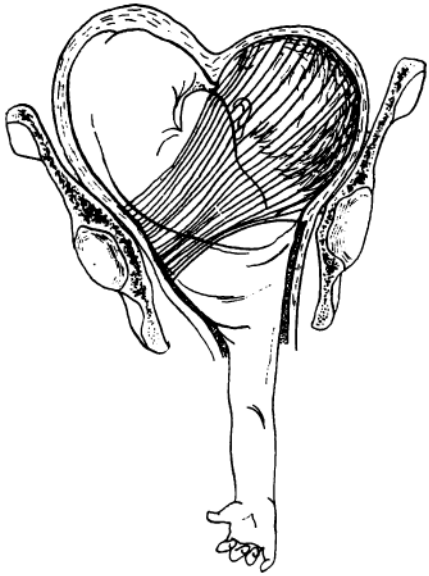

Fig. 235. Persistent transverse presentation (overdistention of the lower uterine segment)

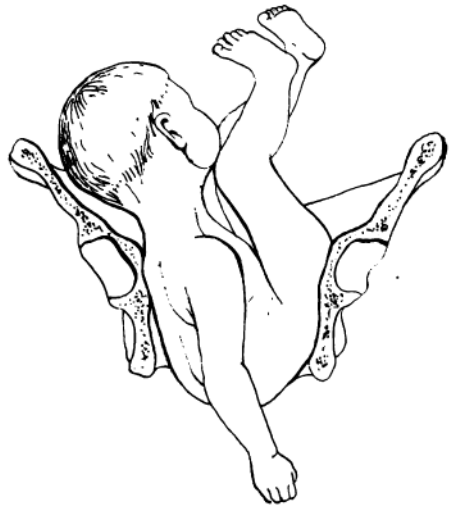

Fig. 236. Spontaneous version of the foetus

sists and complications, dangerous for both the mother and the foetus, develop.

No part is presenting in transverse (oblique) presentation and the amniotic fluid is not separated into two portions. As the uterus contracts, the whole bulk of the amniotic fluid rushes toward the lower pole of the conceptus and the *membranes rupture prematurely*. All, or almost all, amniotic fluid is discharged at once and its gush entrains the arm or the umbilicus.

Fig. 237. Labour in folded position

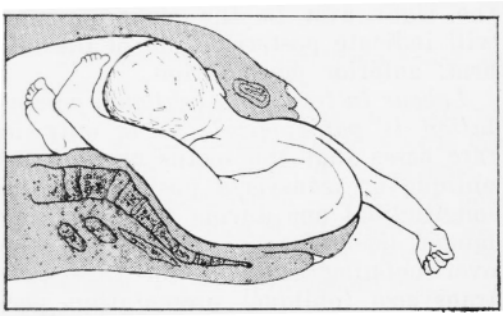

The uterus contracts after the escape of the amniotic fluid to 'grasp' the foetus and immobilize it. The contractions may be strong enough to interfere with the placental circulation and to provoke intrauterine asphyxia of the foetus.

Labour forces propel the foetus to the lower uterine segment which is overdistended and the uterine walls are thinned. The foetal spine flexes, in the region of the neck in particular, and the shoulder is forced into the maternal pelvis (Fig. 235). The prolapsed arm becomes oedematous and bluish.

Immobility of the foetus, engagement of the shoulder, oedema and cyanosis of the prolapsed arm are signs of *per-*

sistent transverse presentation. This is a grave complication fraught with danger of maternal (uterine rupture) and foetal death unless an effective and timely medical aid is given to the parturient.

Less frequently, secondary uterine inertia develops with subsequent sepsis.

In rare cases a premature dead foetus macerates and is delivered in the transverse presentation through *spontaneous version* (Fig. 236). The shoulder of an easily compressed foetus enters the pelvis and is delivered from under the pubic arch; the spinal column is strongly flexed, the trunk, the pelvis, and the legs pass through the maternal pelvis and the second shoulder and the head are finally delivered.

Also in exceptionally rare cases, a dead premature foetus is delivered in the *folded position* (Fig. 237). After delivery of the shoulder, the trunk of the dead premature foetus is sharply flexed in the thorax, the head is impressed into the foetal abdomen and the foetus is propelled in this position through the birth canal.

Conduct of pregnancy and labour. Transverse (oblique) presentation diagnosed at relatively early terms (on the 7th or 8th month) may change spontaneously to longitudinal position. Version of the foetus can be promoted by lying on the side where the large underlying part of the foetus (the head or the pelvis) is found. For example, if the head is located in the left iliac region, the pregnant is recommended to sleep on her left side. The uterine bottom and the pelvic end of the foetus will thus be deviated to the left, and the foetal head to the right, towards the pelvic inlet. Oblique presentation can thus be transformed into longitudinal. If the head is in the right iliac region, the pregnant should sleep on her right side. If the pelvis of the foetus assumes lower position in oblique presentation, podalic version is easier to perform. Sometimes malpresentation can be remedied by special exercises (alternate lying for ten minutes on the right and the left side in the course of an hour, 3 or 4 times a day).

If malpresentation persists till the 35th or 36th week of pregnancy, the woman should be hospitalized till delivery. The physician should attempt external version to convert the transverse or oblique presentation into the longitudinal one.

If external version fails, the foetus is turned internally during labour with subsequent extraction of the foetus. The recourse to internal version should be made with fully dilated cervix and intact membranes (the membranes are ruptured during version). Or the foetus may be versed immediately after the drainage of the amniotic fluid. It is therefore very important that the membranes remain intact till the end of the first stage of labour, i.e. till the cervix is fully dilated. The parturient is prohibited to get up from her bed; she is recommended to lie on that side where the foetal head (or the buttocks, if they are closer to the pelvic inlet) is found. Early loss of the amniotic fluid can be prevented by introducing a colpeurynter into the vagina.

As soon as the cervix is fully dilated, the membranes are ruptured and the foetus is turned in the required position and extracted.

If the amniotic fluid escapes spontaneously, the parturient should be given an immediate vaginal examination: if the cervix is fully dilated, the foetus is turned and extracted; if dilation is incomplete, a metreurynter is

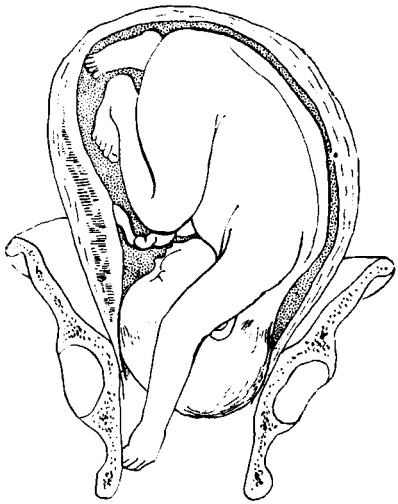

Fig. 238. Prolapse of the arm in cephalic presentation

introduced into the uterus to preclude escape of the remaining amniotic fluid and to accelerate the dilation of the cervix.

In some cases when transverse or oblique presentation is concurrent with some other pathology (contracted pelvis, 'elderly' primipara), caesarean section is indicated soon after the onset of labour.

The foetus often dies in persistent transverse presentation, and the foetus is extracted by its parts. If the foetus is alive and there are no contraindications (infection) to abdominal hysterotomy, a caesarean section should be made. Version is contraindicated in persistent transverse presentation because of the danger of the uterine rupture: the uterus can rupture at the very first attempt of version.

Labour in transverse and oblique presentations is a grave pathological process and it should therefore be conducted in hospital only. If, for some reason, labour began at home, the parturient should immediately be delivered to the hospital by any convenient means under watchful observation of the obstetrician.

Morphine (0.01 g) or pantopon (0.02 g) should be given to the parturient and a doctor should be immediately sent for. No attempts should be made to remedy the prolapsed arm because it will prolapse again and because this manipulation is fraught with danger of uterine rupture.

Prolapse of Small Parts and Umbilical Cord

Presentation and prolapse of small parts of the foetus are differentiated. If the membranes are intact and small parts of the foetus, such as its arm, foot or umbilicus, are found by side or underlying the large presenting part, the condition is referred to as presentation of small parts.

The presence of small parts and the umbilicus beneath the large presenting part after the escape of the amniotic fluid is classified as their prolapse.

The *prolapse of the arm* occurs most frequently in transverse (oblique) presentation but is a rare phenomenon with longitudinal presentation (Fig. 238). The arm may only prolapse in longitudinal presentation if free space is found between the head and the pelvis. This complication occurs in premature labour, multiple birth (small head), flat pelvis, polyhydramnios (high level of the head over the pelvic inlet at the moment of the amniotic fluid escape).

The prolapse of the arm in transverse presentation is not classified as an independent pathology. During podalic version the arm is pulled into the birth

canal by itself. During destructive operations on the foetus in persistent transverse presentation, the prolapsed arm is used as a handle by which the foetus is pulled down and its trunk is extracted (with decapitation).

The prolapse of the arm in longitudinal presentation is a dangerous complication of labour. The arm lying by side of the head narrows the pelvic aperture and hinders the propulsion of the head; the expulsion of the foetus thus becomes difficult or even impossible. Labour may end successfully only on condition that the head is small (premature delivery, twin birth), or only the hand rather than the entire arm has prolapsed. In the latter case labour may be prolonged; it may be complicated by endometritis and foetal distress. Secondary uterine inertia, or convulsive contractions of the uterus attended with strangulation of soft tissues of the birth canal often develop. The rupture of the uterus is also possible.

Presentation and prolapse of the arm are diagnosed in a vaginal examination (the presenting arm is palpated through the membranes). If the arm is presenting, the parturient is placed on her side (other than the presenting arm): the uterine bottom and the foetal pelvis move in the same direction and the arm is thus moved upwards. After the escape of the amniotic fluid, the head engages the pelvis and this precludes the repeated prolapse of the arm.

If the arm is prolapsed, the lying on the side fails to remedy the situation. If the head is movable, it is displaced upwards and the prolapsing arm is put beyond the head. If it fails and the arm prolapses again, a recourse to podalic version should be made if the amniotic fluid has only recently escaped and the foetus is movable. Caesarean section is performed in some cases.

If the head has engaged the pelvis, the expectant treatment is recommended. If any complication develops (foetal distress, secondary uterine inertia), forceps delivery is indicated.

Prolapse of the umbilical cord. This often occurs in transverse (oblique) presentation, when the lower uterine segment is not occupied by the presenting part. The umbilicus can also prolapse in longitudinal presentation as well, if the presenting part does not occupy the pelvic inlet (Fig. 239). This complication therefore occurs in contracted pelvis, deflexed positions of the foetus, when the head is not engaged for long time, in multiple birth (small head) and also in breech presentation. In polyhydramnios the umbilical cord may be carried away with a violent gush of amniotic fluid. Excessive length of the umbilical cord is another predisposing factor.

Fig. 239. Prolapse of the umbilical cord

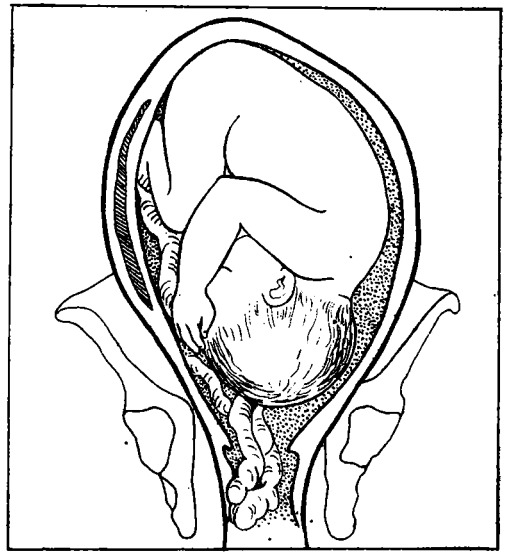

The prolapsed umbilical cord is easily compressed so that it does not interfere with the delivery of the presenting part, but this complication is very dangerous for the foetus. The prolapsed umbilical cord is usually compressed between the presenting part and the pelvic wall to interfere with normal blood circulation. Unless the appropriate aid is given, the foetus dies from asphyxia.

Foetal death can be prevented by timely diagnosis of prolapsing umbilicus and proper selection of the method to conduct labour.

The cord usually prolapses with the escaping amniotic fluid and vaginal examination is therefore necessary after the loss of the fluid for timely diagnosis of this complication. The examination is especially necessary in conditions predisposing to the prolapse of the cord (transverse presentation, contracted pelvis, polyhydramnios, etc.).

The prolapsed umbilical cord should be examined carefully because stimulation of the umbilical vessels causes their spasms and impairment of the foetal circulation. If the umbilical vessels pulsate, the foetus is alive; the absence of pulsation during the uterine contractions and in the intervals between them indicates that the foetus is dead.

If the umbilical presentation has been diagnosed (by palpation or amnioscopy), the parturient should be placed on her side opposite to that where the umbilicus is presenting: the umbilical cord may move upward while the head, after the amniotic fluid has escaped, will descend into the pelvis and engage.

Urgent medical aid is necessary in prolapsed umbilical cord of a live foetus. If the cervix is fully dilated and the foetus is movable, podalic version should be made to change the transverse presentation to the longitudinal one with subsequent extraction of the foetus. If the umbilical cord has prolapsed soon after the escape of the amniotic fluid and the foetus head is movable, the version with subsequent extraction of the foetus (if the cervix is fully dilated) is indicated. In breech presentation if the cervix is fully dilated and signs of foetal asphyxia develop, labour should be ended by extraction of the foetus by its leg or the groin. If the buttocks or the feet of a small foetus enter the pelvis of the mother the umbilicus may remain uncompressed. Expectant treatment is then recommended on the part of the medical personnel: the heart function of the foetus should be carefully observed. If the head of the foetus is engaged (cephalic presentation) and the foetus is alive (the vessels of the prolapsed umbilicus pulsate), an urgent forceps delivery is indicated.

If the cervix is not fully dilated, the umbilical cord should be replaced and its repeated prolapse prevented by using a metreurynter. Otherwise a caesarean section should be performed.

Labour in umbilical presentation or prolapse should be conducted in the presence of a physician since various obstetrical operations may be needed.

Version of the foetus and its extraction are the only obstetrical operations that can be performed by the obstetrician in the absence of a physician.

Chapter Twenty-three

ABNORMAL LABOUR

Normal mechanism of labour occurs in anterior occiput presentation when the flexed head passes the pelvis by its smallest (suboccipitobregmatic) diameter. Labour in posterior occiput presentation (with the head flexed) is another mechanism of normal labour.

Deviations from the normal mechanism often complicate labour to a smaller or greater extent. These deviations comprise: deflexed or extended head, asynclitism and high straight or low transverse position of the head.

Deflexed (Extended) Vertex

The forthcoming part of the flexed head in occiput presentation is the occiput, the posterior fontanelle being the leading point. The head passes through the female pelvis with its smaller (suboccipitobregmatic) diameter (with the suboccipitofrontal diameter in posterior presentation).

But sometimes the vertex deflexes as it passes the pelvis and the chin is separated from the upper chest upon which it was flexed; the vertex, sinciput (brow) or face (mentum) become now the leading point. The vertex is thus said to be extended.

Three types of extension are distinguished (Fig. 240):

1. The smallest degree of extension is characterized by deflexion of the chin from the chest, the anterior fontanelle being the leading point of the forthcoming vertex. This is classified as *vertex presentation* (Fig. 240, *a*).

2. The second degree of extension characterized by the sinciput (brow) becoming the leading point is classified as *brow presentation* (Fig. 240, *b*).

3. The third degree of extension is the greatest: the face of the foetus becomes the lowermost point. This is the *face (or mentum) presentation* (Fig. 240, *c*).

Causes of extended presentations are quite varied. All obstacles that interfere with the flexure of the head are among them. Deflexed presentations will mostly occur in contracted pelvis (flat pelvis, in particular). Cephalopelvic disproportion is another cause: the occiput is the widest portion of the head and its descent is delayed. Excessively large head is another possible cause. Furthermore, if the head is small it can pass the pelvis unobstructed in the extended position.

The vertex may deflect due to premature loss of the amniotic fluid (in polyhydramnios, in particular); if the head tends to deflect at the moment of fluid escape, it may remain fixed in this position. Tumours of the neck, which interfere with normal flexion, and dolichocephalism (posterior extension of the head), which slows down the descent of the occiput, are rare causes of deflexion. The mechanism of la-

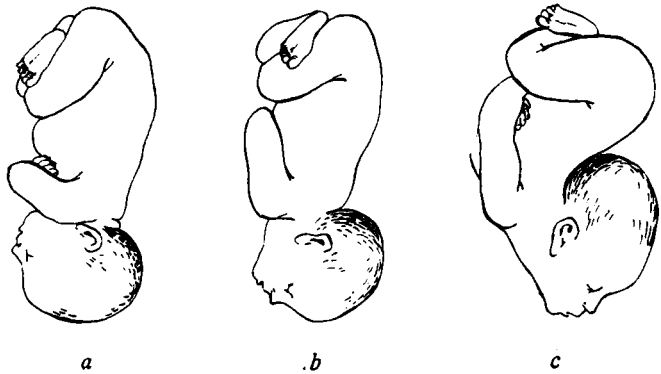

Fig. 240. Degrees of head extension:
a — vertex presentation; *b* — brow presentation; *c* — face presentation

bour in all types of deflexed vertex is characterized by the following movements:

1. The first movement of labour is extension (deflexion) of the vertex (in contrast to flexion in normal occiput presentation in labour).

2. When inside the pelvic cavity, the head is usually turned with its occiput posteriorly (internal rotation) in all types of vertex extension. The occiput turns anteriorly only in exceptional cases to make normal labour impossible.

Vertex Presentation

It is usually impossible to identify vertex presentation by external obstetrical examination. The vaginal examination during the dilation stage reveals the presence of both the anterior and posterior fontanelles at the same level. As the expulsive stage begins, the anterior fontanelle descends to a lower position and becomes the leading point, while the posterior fontanelle lags behind in its progress and is therefore difficult to palpate. The upper end of the frontal suture, which passes from the anterior portion of the frontal fontanelle, is palpable. The vertex and the anterior fontanelle are the lowermost part of the head.

Mechanism of labour. As the head enters the pelvis its sagittal (partly frontal) suture aligns with the transverse or slightly oblique diameter; the anterior and posterior fontanelles are found at the same level.

The *first movement*: the extension is small; the chin is separated from the upper chest; the vertex lowers; the anterior fontanelle descends below the posterior fontanelle and becomes the leading point. The head enters the pelvic cavity in this position.

The *second movement* (internal rotation): the vertex turns posteriorly inside the pelvic cavity and the sagittal suture aligns with the oblique diameter.

The internal rotation is completed at the outlet from the pelvis and the anterior fontanelle now turns to the symphysis, while the posterior fontanelle faces the sacrum. The sagittal suture aligns with the anteroposterior diameter of the pelvis.

The *third movement* (coincident with

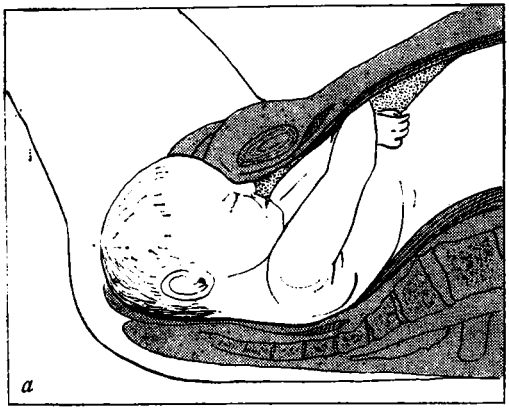

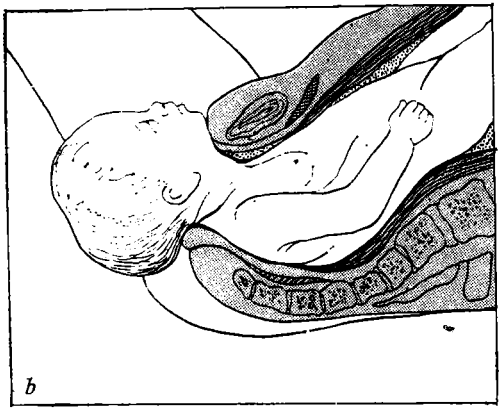

Fig. 241. Delivery of the head in vertex presentation:
a — rotation of the head about the symphysis;
b — rotation of the head about the perineum

disengagement) consists in: (a) flexion and (b) extension of the disengaging head. The vertex and the anterior fontanelle first appear at the pudendal cleft, then the sinciput and the nose bridge are delivered over the lower edge of the pubic arch. The nose bridge area (glabella) becomes the fulcrum (Fig. 241, *a*), about which the head is *flexed*. The occiput is now delivered to the occipital eminence, which rests against the sacrococcygeal joint to form

Fig. 242. Molding of the foetal skull in vertex presentation

another fulcrum about which the head is *deflexed*. During extension of the head the face is delivered from under the symphysis (Fig. 241, *b*).

The *fourth movement*: external restitution (rotation) of the vertex and the internal rotation of the shoulders. The head passes the pelvis and is delivered through the vulvar ring, its girth being 34 cm which corresponds to the occipitofrontal diameter of the skull (12 cm). The swelling (oedema) on the head is formed in the region of the anterior fontanelle; the skull molding is pronounced and the head is elongated in the vertical direction to resemble a dome (Fig. 242).

The mechanism of labour in vertex presentation is like that in posterior occiput presentation, but the likeness is only outward (both presentations are posterior). In all other aspects the mechanism of labour is different. In posterior occiput presentation the flexed head passes through the pelvis with its suboccipitofrontal diameter (the girth is 33 cm). In the vertex presentation the extended head passes through the pelvis and the perineum by its girth of 34 cm. In posterior position the

leading point is the area between the anterior and posterior fontanelles, while in the vertex presentation the leading point is the frontal fontanelle. The margin of the haired part of the head is the first fulcrum in posterior occiput presentation while the second fulcrum is the posterior cranial fossa. The first fulcrum in vertex presentation is the nose bridge and the second the occipital eminence.

Labour in vertex presentation. The expulsive period is prolonged because the extended head passes the pelvic cavity by its comparatively large (occipitofrontal) diameter and has to overcome the resistance of the birth canal.

If the pelvis is contracted or the foetus is large, convulsive contractions may develop along with overdistention of the lower uterine segment or secondary uterine inertia; this may be followed by the discontinuation of the foetal progress through the birth canal, compression of soft tissues and the bladder, and intrauterine asphyxia of the foetus. If the pelvic architecture, the foetus size and the labour are normal, labour ends spontaneously.

Conduct of labour is expectant. The obstetrician should carefully watch the parturient condition, the character of labour, the progress of the foetus, and should regularly listen to the foetal heart and count its beats. Steps to prevent asphyxia should be taken. The delivering head should be flexed anteriorly (toward the pubic bone); as soon as the occiput has been delivered, the head should be taken carefully by hands and deflexed posteriorly. Surgery is only indicated in complications of labour (secondary uterine inertia, foetal asphyxia, etc.). Labour should be conducted under the supervision of physician.

Brow Presentation

Brow or frontal presentation may only be transient and as the head is extended during labour the brow presentation often changes to face (or mentum) presentation. If the head is not extended to the full, brow presentation may persist.

The incidence of brow presentation in labour is low (about one per 2000-3000 births). Labour is prolonged. Complications often occur in the expulsive stage to endanger the mother and the foetus. Labour in brow presentation may only end spontaneously if the pelvis is normal or large, the foetus is small (premature), and labour efforts are effective.

Brow presentation is difficult to *diagnose* by external examination. The vaginal examination will only be effective if the sinciput with its frontal suture can be palpated on the engaged head.

Brow presentation can be diagnosed by palpation of the nose root and the superciliary arches on one side of the frontal suture, and the anterior angle of the frontal fontanelle on the other side. If the head is movable, the brow presentation may change to face presentation.

Mechanism of labour. The *first movement*: extension of the vertex. The head is engaged in the pelvis with its occipitomental diameter, the root of the nose assuming the lowermost position (the leading point). The frontal suture aligns with the transverse pelvic diameter. The head descends into the pelvic cavity in this position until it reaches the pelvic floor (provided the head is not large and labour efforts are adequate).

The *second movement*: internal rotation of the head with the occiput to-

ward the perineum; the frontal suture aligns first with the oblique and then the anteroposterior diameter of the pelvic outlet plane.

The *third movement* consists of (a) flexion and (b) extension of the head during its delivery. Under the expelling thrust of very forceful abdominal contractions the sinciput, the eyes and the nose show in the pudendal cleft (Fig. 243); the maxilla rests against the lower margin of the symphysis (the first fulcrum), the head is flexed, and the vertex and occiput are delivered over the perineum by flexion. The occipital eminence (the second fulcrum) rests against the sacrococcygeal platform and the head is extended: the mouth and the chin are delivered from under the symphysis.

The *fourth movement* is the external restitution of the vertex which depends on the internal rotation of the shoulders.

The head is markedly molded and elongated in the frontal direction (Fig. 244). The oedema, usually found in the region of the forehead, is large. It is propelled through the birth canal with its girth of 35 cm (which corresponds to the mean of the occipitofrontal and occipitomental diameters).

Labour is usually prolonged and pathological. It rarely ends spontaneously (only with a small foetus, large pelvis and forceful uterine contractions). The expulsive stage is prolonged. Secondary uterine inertia often develops with discontinuation of the progress of the foetal head, compression of the soft tissues of the birth canal and the bladder, and subsequent intrauterine asphyxia. The prolonged compression of soft tissues may result in urogenital fistulae. Excessively forceful contractions may develop with overdistension of the lower uterine segment and the

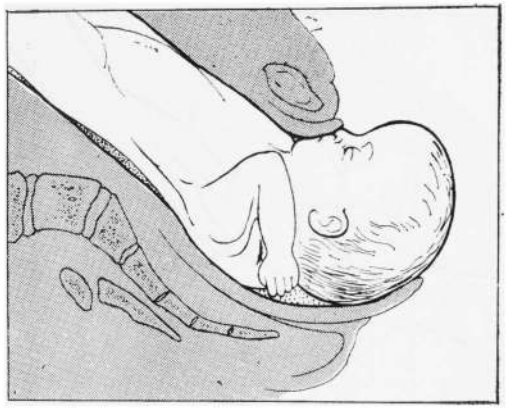

Fig. 243. Delivery of the head in brow presentation

uterine rupture. Deep lacerations of the perineum often occur. The foetus is delivered with signs of intracranial injury. Stillbirths are not infrequent.

Conduct of labour. Labour in brow presentation may only be conducted by a physician. If the head is not yet engaged, expectant treatment is recommended because the head may continue deflecting and brow presentation may change to face presentation. Attempts to artificially transform brow presentation into face one by putting the finger into the foetal mouth are usually unsuccessful and not safe. There-

Fig. 244. Molding of the foetal skull in brow presentation

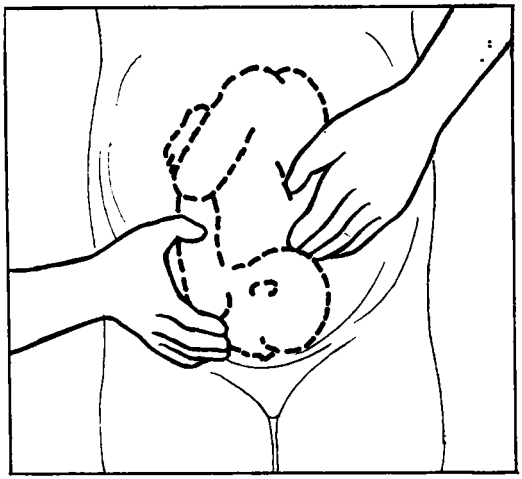

Fig. 245. Identification of face presentation by external palpation

fore, if brow presentation fails to correct spontaneously, podalic version with subsequent traction of the foetus should be attempted if the foetus is movable, the cervix is fully dilated and the head is not yet engaged. If the foetus is mature and the conditions for podalic version are absent, an abdominal delivery should be considered.

If the head has entered the pelvis, expectant treatment is recommended. The condition of the mother and the foetus is observed thoroughly and if any complications develop (uterine inertia, prolonged compression of soft tissues of the birth canal between the head and the bony pelvis, signs of threatened rupture of the uterus), labour should be ended operatively. The foetus usually dies and craniotomy is therefore indicated.

Face Presentation

Face presentation usually occurs during labour, and less frequently during pregnancy. It results from full extension of the head. According to I. F. Zhordania, labour in face presentation occurs in 0.23 per cent cases.

Face presentation can be diagnosed by external and vaginal examination. Because of the maximum extension the head is flexed on the foetal back to form a depression between the occiput and the back. The foetal back flexes anteriorly and is therefore separated from the uterine wall while the chest, on the contrary, approaches the uterine wall. External examination can reveal the following features characteristic of face presentation: (1) depression between the back and the thrown back head (Fig. 245); (2) the foetal heart is distinctly heard not on the foetal back but on the chest (where small parts of the foetus can be palpated).

The sinciput (with the frontal suture), superciliary arches, the nose, mouth and the chin can be palpated during vaginal examination. After the escape of the amniotic fluid, a swelling is formed on the presenting part to interfere with the identification of face presentation. If the swelling is large, face presentation can be mistaken for breech. In order to differentiate between breech and face presentation, it is necessary to remember that the sacrum, the genitalia, and the groin can be palpated in breech presentation and the superciliary arches, the nose, the mouth and the chin in face presentation. If the swelling is large, the foetal mouth is sometimes mistaken for the anus. The examining finger can palpate the jaws, the tongue and the hard palate in the mouth, while the resistance of the constrictor will be felt by the examining finger in the anus. Examination by the finger is not however recommended because of the risk of injury to the foetus. The vaginal exam-

nation in face presentation should be performed with special care for the same considerations.

The vaginal examination is aimed at final diagnosis of the foetal presentation. If the chin is directed to the right, the position is left, and vice versa. The position of the foetus in face presentation is determined by the chin while the back and occiput are the landmarks in all other presentations (although in the opinion of some authors the position of the foetus in face presentation should also be identified by the foetal back). If the chin is turned anteriorly and the back posteriorly, the presentation is anterior, and vice versa.

Mechanism of labour. By the beginning of the second (expulsive) stage of labour the head is at the pelvic inlet or enters the pelvis. The line leading from the frontal suture along the nose to the chin aligns with the transverse or slightly oblique diameter of the pelvis.

The *first movement*: extension. The chin is the lowermost point or the leading point (Fig. 246). The head descends to the pelvic floor in this position.

The *second movement*: internal rotation. The vertex is rotated at the pelvic floor. During rotation the chin usually turns anteriorly; the face line aligns with the oblique and then the anteroposterior diameter of the pelvic outlet plane.

The *third movement*: flexion of the head. The chin begins 'crowning' under the thrust of the expulsive contractions and the hyoid bone rests against the symphysis (Fig. 247). The head is rotated about this point, and the face, the vertex and the occiput are born over the perineum by flexion.

The *fourth movement*: external restitution of the vertex. The swelling is

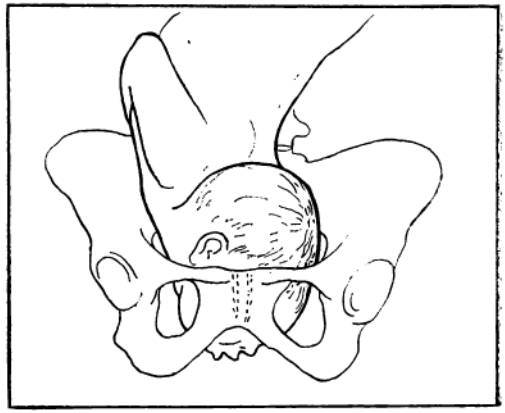

Fig. 246. Face presentation. The engaged head is extended

located on the face (Fig. 248) which is reddish blue; the lips and the eyelids are especially oedematous; oedema of the tongue sometimes develops to make breast-feeding difficult during the first days of the infant's life.

Labour. The head passes the pelvis and is delivered through the vulval ring by its relatively small girth (32-33 cm) which corresponds to the verti-

Fig. 247. Face presentation. Delivery of the head

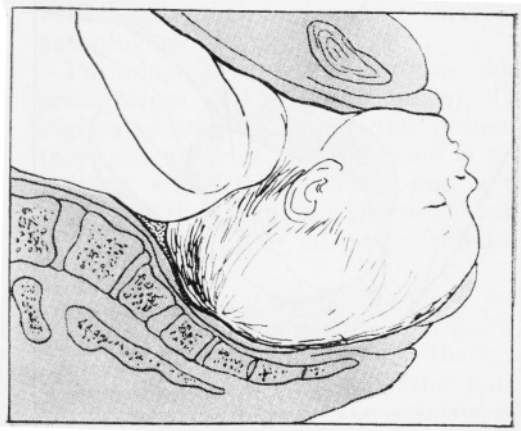

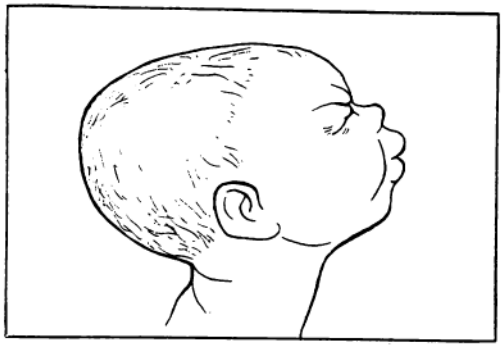

Fig. 248. Molding of the foetal skull in face presentation

cal diameter (9.5 cm). If the pelvic architecture and labour are normal, delivery is spontaneous, but with a large foetus, insufficiently strong contractions, and narrow pelvis labour becomes prolonged and complications develop (compression of soft tissues, asphyxia of the foetus, endometritis, etc.).

A grave complication, persistent face posterior presentation, occurs in rare cases: the chin turns to the coccyx and

Fig. 249. Face posterior presentation (spontaneous delivery is impossible)

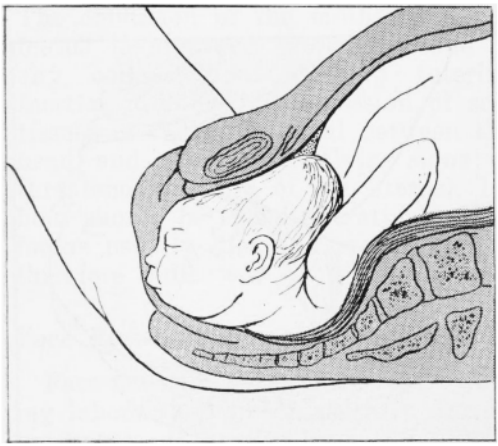

the forehead to the symphysis (Fig. 249). The head progress through the birth canal is arrested because the head has to pass the pelvis together with the chest. The volume of the head and the chest of the infant are incompatible with the size of the female pelvis and a surgical operation is therefore required.

Conduct of labour. Expectant treatment is recommended in conducting labour in face anterior presentation because in most cases labour ends spontaneously.

During the first stage of labour the woman is kept in bed to prevent early drainage of the amniotic fluid. The parturient is recommended to lie on that side where the foetal chin is directed; this position promotes lowering of the chin and labour is facilitated.

During the second stage the obstetrician should observe carefully the status of the mother and the foetus, the character of labour, and the progress of the foetal head. Expectancy is recommended until the chin is delivered, but later careful assistance should be given. The head should be handled with special care to minimize the risk of damage to the face. As soon as the face has been delivered, the head should be turned carefully and slowly toward the symphysis, while the soft tissues of the birth canal should be pulled gently off the delivered head by the more dominant hand. The perineum often lacerates in face presentation and steps to prevent the injury should therefore be taken. Perineotomy is recommended in threatened laceration.

If complications develop, medical aid may be required (to control asphyxia, to stimulate labour, etc.). Abdominal hysterotomy is only performed for special indications on the part of the foetus or the mother. Surgery (usually a

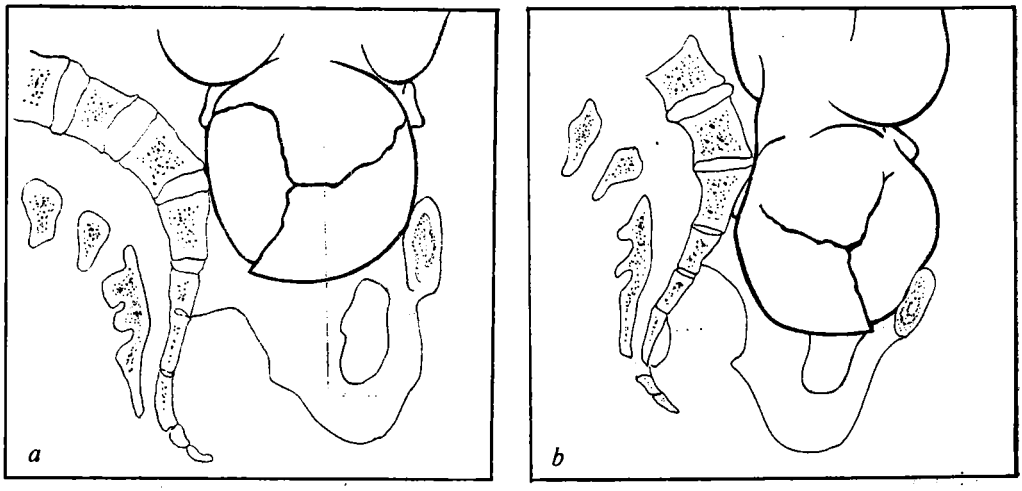

Fig. 250. Pathological asynclitism:
a — pathological anterior asynclitism; *b* — pathological posterior asynclitism

caesarean section or craniotomy) is absolutely necessary in face posterior presentation since spontaneous pelvic delivery is impossible and the mother will die from the rupture of the uterus or sepsis.

Asynclitism

Synclitism denotes parallelism of the sagittal suture of the foetal head with the pelvic axis when the suture is equidistant from the symphysis and the promontorium. In asynclitism the sagittal suture deviates either toward the symphysis or the promontorium. If the sagittal suture is anterior to the parallel plane, that is, nearer the symphysis, the posterior parietal bone is presenting and the condition is referred to as posterior asynclitism. Slight asynclitism occurs in normal labour as a transient phenomenon and when the head descends into the pelvis the asynclitism disappears. This kind of asynclitism in normal labour is physiological.

A more persistent, moderate asynclitism (more often anterior) occurs in contracted, mostly flat pelvis. Moderate asynclitism favours the passage of the head through a contracted flat pelvis (see Ch. 24) and is therefore considered to be a physiological condition.

Pronounced asynclitism interferes with normal delivery and is therefore pathological.

Pathological *anterior parietal bone presentation (Naegele's obliquity)*. The sagittal suture is nearer the promontory; the anterior parietal bone is presenting, while the posterior one is retained at the promontory and the head is flexed on the posterior shoulder (Fig. 250, *a*).

Pathological *posterior parietal bone presentation (Litzmann's obliquity)*. The sagittal suture is closer to the symphysis (or near it); the posterior parietal bone is presenting, the anterior one

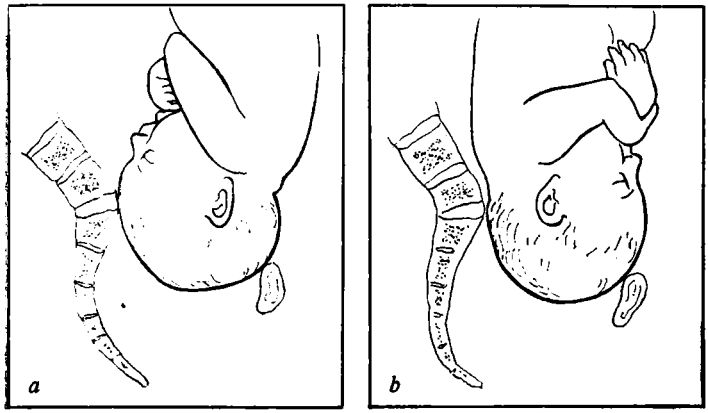

Fig. 251. Straight engagement: *a* — positio occipitalis pubica; *b* — positio occipitalis sacralis

is retained over the symphysis and the head is flexed on the anterior shoulder (Fig. 250, *b*). In pronounced posterior asynclitism the ear of the foetus can be palpated at the promontory.

Contracted pelvis, flaccid abdominal wall (pendulous abdomen), prolapse of the arm by side of the head, and some other causes contribute to the incidence of pathological asynclitism. Asynclitism is diagnosed during vaginal examination by the persistent deviation of the sagittal suture from the pelvic axis toward the symphysis or the sacrum.

Pathological asynclitism hinders the progress of the head and labour can only end spontaneously if the contractions are sufficiently forceful, the foetal head is small, and the pelvis is not markedly contracted. The foetal skull is strongly molded and becomes oblique. If the contractions are strong, the presenting parietal bone becomes further engaged in the pelvis and then the other parietal bone descends from the symphysis or the sacral promontory.

Labour is prolonged and the soft tissues of the birth canal and the bladder often become compressed; secondary uterine inertia, asphyxia, intrauterine injuries, and other complications often occur as well. The prognosis is especially unfavourable in pathological posterior asynclitism: the marked posterior parietal bone engagement often becomes an obstacle to delivery.

Conduct of labour. Labour in pathological asynclitism should be conducted by a physician. Expectant treatment should be recommended in moderate asynclitism, especially anterior asynclitism. Surgery is only indicated if dangerous complications develop. Active obstetrical assistance is recommended in marked posterior asynclitism.

If the foetus is movable, an experienced physician may attempt a podalic version; otherwise an abdominal hysterectomy is recommended (provided the foetus is alive). Destructive operations on the foetus are indicated if the foetus is dead.

Straight Engagement

As a rule, the head enters the pelvis with its sagittal suture aligned with

the transverse or slightly oblique diameter. But in very rare cases the sagittal suture aligns with the anteroposterior diameter (true conjugate). The occiput can be turned toward the symphysis or the sacrum. If the occiput is turned anteriorly, the position is called occiput pubic (Fig. 251, *a*) and if posteriorly, i.e. toward the sacrum, the occiput sacral position (Fig. 251, *b*).

Contracted pelvis, changes in the shape of the foetal head (the biparietal diameter is greater than the suboccipitobregmatic diameter), decreased tone of the uterus and the abdominal wall, etc. are the causes of this complication.

The positioning of the head in the anteroposterior diameter complicates the course of labour. The expulsive period becomes prolonged; uterine inertia with cessation of the head progress through the birth canal, compression of the soft tissues of the reproductive tract, asphyxia, intracranial injury and other complications often develop and indicate surgical delivery. If the pelvic architecture and labour forces are normal, and the foetus is small, labour may end spontaneously.

The prognosis is much better with anterior than posterior presentation. The head is strongly flexed and propelled through the pelvic planes with the sagittal suture aligned with the anteroposterior diameter of the maternal pelvis. When the head reaches the pelvic floor, its suboccipital region rotates about the symphysis and the head is delivered by deflexion.

The foetal skull is molded markedly and the head is flexed in posterior presentation. In this position the head enters the pelvis (if the head is small, the pelvic architecture is normal, and the labour forces are effective). The head may turn through 180° in the pelvic cavity and the head may thus be delivered in the anterior presentation. If the head fails to rotate internally, it will be delivered in the posterior presentation. Spontaneous delivery is however hardly possible in this position and operative assistance will usually be needed (podalic version, caesarean section, forceps delivery, craniotomy, etc.).

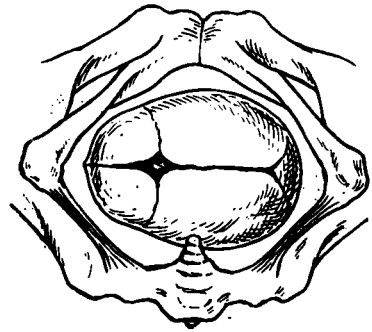

Fig. 252. Low transverse position of the head

Low Transverse Position of the Head

In this deviation from normal labour the head fails to rotate internally and reaches the pelvic floor (and even the pelvic outlet plane) with its sagittal suture aligned with the transverse pelvic diameter (Fig. 252). This would usually occur in contracted or flat pelvis; relaxation of the pelvic floor muscles also contributes to the incidence of this abnormality.

The expulsion of the foetus becomes difficult. Rigid ischial tuberosities interfere with deflexion of the head and it thus fails to be delivered with the sagittal suture in the transverse pelvic diameter. The head will only be disengaged from the pelvis if it performs internal rotation and the sagittal su-

ture aligns with the anteroposterior diameter of the pelvis. The internal rotation may be performed if the labour efforts are strong and prolonged and the pelvic contracture is not marked. If the head fails to rotate, complications dangerous to the mother and the foetus develop (compression and necrosis of the soft tissues of the reproductive tract and the bladder, ascending infection, foetal asphyxia, etc.).

Conduct of labour is expectant. The parturient is recommended to lie on her side (where the foetal occiput is found). Steps to prevent intrauterine asphyxia should be taken, and the status of the mother and the foetus should be carefully observed. If complications arise, operative assistance is required. If the foetus is alive, forceps delivery is indicated. If the foetus is dead, craniotomy should be performed.

Chapter Twenty-four

CONTRACTED PELVIS

Pelvic contracture is one of the most important problems of modern obstetrics. Complications dangerous to the mother and the foetus often develop during labour in women with narrow pelvis. These complications require skillful obstetrical assistance, and the necessity of operations often arises. The problem of contracted pelvis is the subject of much discussion in the literature. The Russian obstetricians, such as A. Ya. Krassovsky, N. N. Fenomenov, A. F. Palmov, and others made an important contribution to the study of this complicated problem.

The *concept of contracted pelvis.* M. S. Malinovsky defines contracted pelvis as follows: "A bony pelvis so modified that a mature foetus, especially its head, meets mechanical obstacles as it passes through it during labour is called contracted". The resistance that the foetus meets during passage through a contracted pelvis varies in its degree. If contracture is only inconsiderable, the difficulties are easily overcome and labour ends spontaneously; in cases of pronounced cephalopelvic disproportion, these difficulties are unsurpassable.

All diameters (anteroposterior, transverse and oblique) or only some of them (for example, anteroposterior or transverse), or else only one diameter, (for example, the anteroposterior diameter of the pelvic inlet plane) may be reduced in a contracted pelvis. For these considerations A. Ya. Krassovsky defines a contracted pelvis as follows: "all diameters of the pelvis, or only some of them, or even only one important diameter, may be reduced in a contracted pelvis".

The main pelvic diameter, which is especially important in contracted pelvis, is the true conjugate. If it measures less than 11 cm (e.g. 10 cm), the pelvis is contracted. The true conjugate may be calculated from the diagonal and the external conjugate. If the external conjugate is smaller than 19 cm (18 cm and below), the pelvis is considered to be contracted.

Thus, a *contracture may be diagnosed* by measuring the pelvis and establishing the diminution of all or only some pelvic diameters.

True, an anatomically narrow pelvis is not obligatory an obstacle to pelvic delivery. If contracture is moderate, the outcome of labour depends not only on the pelvic diameters but also on the labour forces, the size of the foetus and the ability of the foetal head to be molded. If the uterine contractions are effective, the foetus is not large and the head is readily molded, labour may successfully end by spontaneous delivery. In the presence of uterine inertia or if the foetus is large, the same pelvis will become an insurmountable obstacle to spontaneous delivery. With the same degree of contracture (for example, the external conjugate is

18 cm) one woman may be delivered normally while the other will develop complications. Hence, an anatomically contracted pelvis is not always narrow in the clinical (functional) aspect. An anatomically contracted pelvis (narrow with respect to the course and outcome of labour) may or may not be narrow depending on the strength of the uterine and abdominal contractions, the size of the head and its ability to mold, etc.

The diagnosis of a contracted pelvis is established by pelvimetry; whether or not a given pelvis is *narrow in the clinical sense* will be established during labour by estimation of the character of labour forces, the progress of the head, etc.

To summarize, the pelvis that becomes an obstacle to normal delivery of a foetus in the given labour is *contracted.*

If contracture is pronounced, the pelvis will always be classified as narrow in the clinical aspect and the woman cannot be delivered even with forceful contractions and adequate molding of the foetal skull.

Aetiology. The causes of pelvic contracture are varied. A narrow pelvis is one of the main signs of underdevelopment (infantilism). All conditions that may interfere with normal development of the body will become the cause of contracted pelvis. These are unfavourable living conditions, grave diseases in childhood and during sex maturation. Rickets of childhood is especially dangerous in this respect since it softens the bones, including those of the pelvis. Rickets becomes the cause of changes in the bones of the skull, chest, spine, lower extremities, and the pelvis. Tuberculosis of bones and joints is another cause of contracture or other malformations of the pelvis. Tuberculosis of the femur, the knee and the spine in childhood is especially dangerous in this respect. The same holds for fractures of the pelvic bones, dislocations of the joints, improper osteosynthesis in fractures of the lower extremities which then result in lameness and other motor disorders. Tumours of the bony pelvis, anterior dislocation of the 5th lumbar vertebra, and other processes may also become the cause of contracted pelvis.

Classification of Contracted Pelvis

Contracted pelves are classified by the type of distortion of pelvic architecture and by the degree of contraction.

Classification by pelvic architecture. The following main forms of contracted pelvis are distinguished: pelvis aequabiliter justo minor (or simply, justo minor), flat pelvis, and the generally contracted flat pelvis. Rare forms of contracted pelvis also occur.

1. *Pelvis aequabiliter justo minor* is characterized by the general reduction of all diameters (anteroposterior, transverse and oblique); they all are equally shortened, usually by 1-2 cm (Fig. 253).

Pelvis with equally reduced dimensions occurs in short and subtile women and in women with signs of infantilism (underdeveloped breasts, thin pubic hair, infantile external genitalia, etc.).

This type of pelvis also occurs in tall women with massive skeletal bones and developed muscles. The pelvic architecture in these women is characterized by the presence of musculine features, such as narrow sacrum, narrow pubic arch; the pelvis is especially contracted at its outlet (funnel-shaped pelvis).

2. *Flat pelvis.* This is characterized by reduced anteroposterior diameters with normal transverse and oblique diameters. The contracture is dual in its character: (a) all anteroposterior diameters are reduced (a simple flat or platypellic pelvis), and (b) the anteroposterior diameter of the pelvic inlet plane (the true conjugate) is only reduced: flat rachitic pelvis.

(a) In a *simple flat (or platypellic) pelvis* the entire sacral platform is dislocated toward the symphysis and hence the anteroposterior diameters of all pelvic planes are reduced. The bones of the pelvis or the skeleton are not disfigured (Fig. 254). The body build of women with a simple flat pelvis is normal.

(b) *Flat rachitic pelvis* is marked by distorted bones. The wings of the iliac bones are set wide apart and the distance between the anterior superior iliac spines is increased so that the interspinal diameter is almost the same as the intercristal one. If the rachitic distortion is marked, the intercristal and interspinous diameters are equal or the interspinal diameter exceeds the intercristal one (normally the interspinal diameter measures 3 cm less than the intercristal diameter). The sacrum is shortened, flattened and turned about its horizontal axis so that its base is brought closer to the symphysis while the apex with its tip is deflected posteriorly. The sacral promontory is displaced anteriorly to an appreciable extent (Fig. 255). Since the promontory is turned anteriorly the pelvic inlet plane has the shape of a bean; the anteroposterior diameter is reduced, while the transverse and the oblique diameters remain normal. The greater the extent to which the promontory is displaced anteriorly, the shorter the true conjugate. The diameters of the pelvic outlet plane are increased: the anteroposterior diameter becomes longer because the sacral apex is displaced posteriorly, while the transverse diameter increases because of the increased interspinous diameter (compared with the normal pelvis); the pubic angle in a flat rachitic pelvis is wide. The cavity in a flat rachitic pelvis is normal or slightly increased. Thus, the main anteroposterior diameter of the pelvic inlet plane (the true conjugate) is reduced in the flat rachitic pelvis.

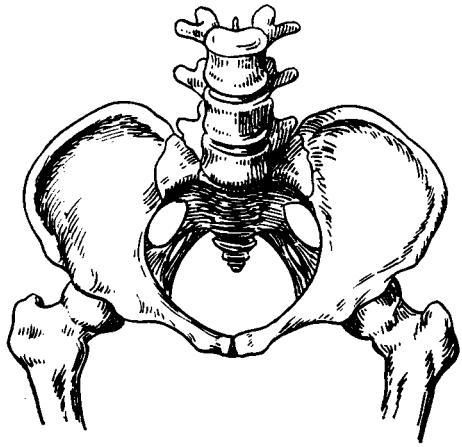

Fig. 253. Justo minor pelvis

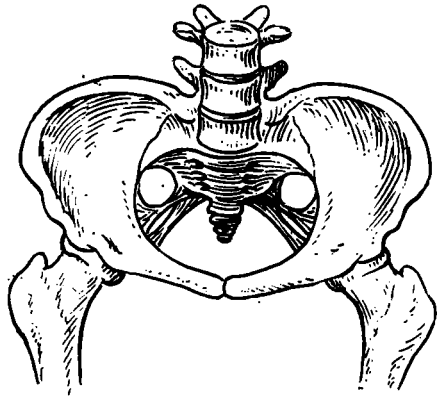

Fig. 254. Simple flat (platypellic) pelvis

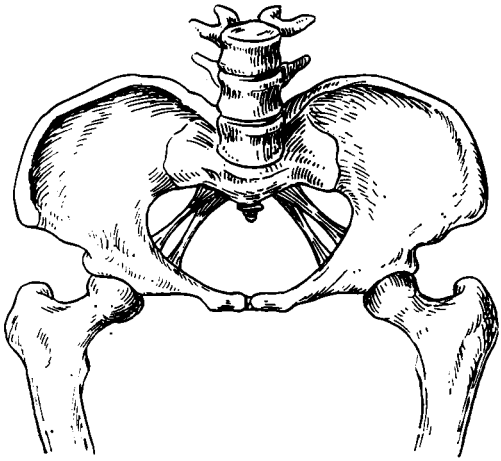

Fig. 255. Flat rachitic pelvis

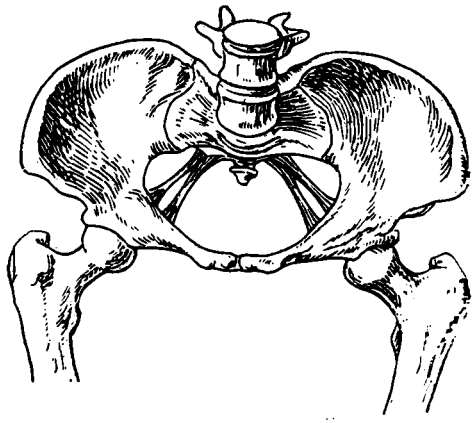

Fig. 256. Generally contracted flat pelvis

Women with rickets in their past history usually have other deviations in their bony structures, such as 'square head', S-shaped clavicles, curved long bones of the legs, distorted spinal and chest bones, etc. These changes may be manifested to various degrees.

3. The *generally contracted flat pelvis* has all its diameters reduced, but the anteroposterior diameters are shortened greater than the others (Fig. 256). The anteroposterior diameter of the pelvic inlet plane is usually shortened to the greatest extent. The generally contracted flat pelvis usually combines with the following two pathologies, viz., infantilism and rickets of the childhood which account for the distortions in the bony pelvis. The pelvis is narrow in general, and moreover, it is flattened because of the greater reduction of the anteroposterior diameters.

The generally contracted flat pelvis is an obstacle to normal delivery; its incidence is lower than that of flat and justo minor pelves. The Table 2 which follows below gives pelvic diameters for various types of contracted pelvis (in centimetres):

Table 2

Pelvic type	Interspinous diameter	Intercristal diameter	Intertrochanteric diameter	External conjugate	Diagonal conjugate	Conjugate vera
Normal obstetric	25-26	28-29	30-31	20	12.5-13	11
Justo minor	24	26	28	18	11	9
Platypellic	26	29	31	18	11	9
Flat rachitic	26	26	31	17	10	8
Generally contracted flat pelvis	24	25	27	16	9	7

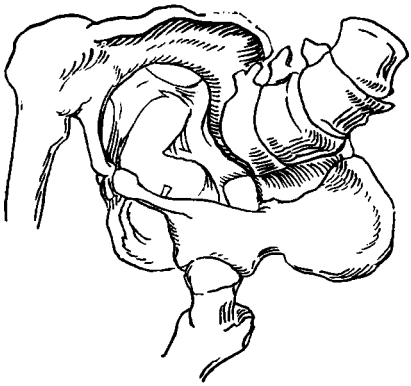

Fig. 257. Otto's pelvis

Fig. 259. Spondylolisthetic pelvis

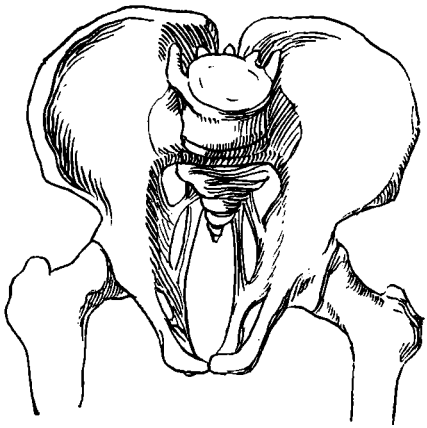

Fig. 258. Beaked (rostrate) pelvis

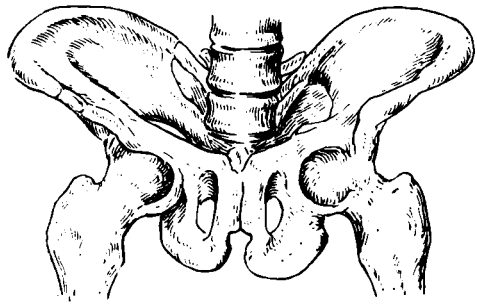

Fig. 260. Osteomalacic pelvis

Rare forms of contracted pelvis. Funnel-shaped, obliquely contracted (Naegele), transversely contracted (Robert) and some other forms of contracted pelvis occur only in rare cases. Coxalgic and Otto's pelvis develop as a result of inflammatory processes in the hip or the knee. The healthy leg carries the main weight of the body and the acetabulum of the healthy hip becomes depressed permitting the head of the femur to protrude intrapelvically and to contract the pelvis (Fig. 257).

Naegele pelvis arises in connection with underdevelopment of one of the sacrum wings. Beaked (rostrate) pelvis is formed in underdevelopment of both sacral wings (Fig. 258).

Spondylolisthetic pelvis is a rare form of abnormal pelvis. It is formed due to partial dislocation of the last lumbar vertebra in front of the first sacral vertebra. The anteriorly dislocated lumbar vertebra hangs over the sacrum to contract the pelvic inlet (Fig. 259).

Osteomalacic pelvis shown in

Fig. 260 is an extremely rare phenomenon.

Classification of contracted pelvis by degree of contracture. The true conjugate is used to judge on the degree of pelvic contracture. The true conjugate is determined by the external and the diagonal conjugate.

Four degrees of pelvic contracture are distinguished:

The *first degree*: the true conjugate is shorter than 11 cm but not shorter than 9 cm. Spontaneous pelvic delivery is possible in most cases with this degree of contracture.

The *second degree*: the true conjugate is 9-7.5 cm. Spontaneous delivery of a mature foetus is possible but complications and obstacles often arise which indicate abdominal delivery. The nearer the true conjugate to 7.5 cm, the more often obstacles to spontaneous pelvic delivery develop.

The *third degree*: the true conjugate measures 7.5-6 cm. Spontaneous delivery of a mature foetus through the natural birth canal is impossible. Forceps delivery or traction by the pelvic end also fail. The foetus can only be extracted through the natural birth canal after a destructive operation on the foetus. A live foetus can be delivered by a caesarean section.

The *fourth degree*: the true conjugate measures 6 cm and below. Spontaneous delivery is impossible. Destructive operations on the foetus also fail to deliver through the natural birth canal: the pelvis is so contracted that it cannot pass even small parts of a dissected foetus. A caesarean section is the only possible way to deliver. This degree of contracture is also known as an *absolutely contracted pelvis.*

This classification concerns the anatomical aspect of pelvic contracture. But it can, to a certain extent, be used to predict whether or not a given pelvis will be narrow in the clinical sense. The third and the fourth degree of contracture indicate that the pelvis is narrow in both the anatomical and clinical sense, since spontaneous delivery of a live foetus is impossible through the natural birth canal and an early abortion is therefore recommended. If the pregnant desires to attempt a delivery a caesarean section should be performed at the end of pregnancy or at the onset of labour.

In the first or the second degree of contracture an anatomically contracted pelvis may be clinically (functionally) narrow or wide enough (the first degree) to pass the foetus. This depends on the size of the foetus, the skull molding, effectiveness of labour forces, etc.

Diagnosis

Timely diagnostication of a contracted pelvis precludes complications that may develop during labour and sometimes at the end of pregnancy. If the degree of contracture is marked. the woman is offered an abortion or is warned that the delivery of a live foetus is only possible through a caesarean section. All pregnant with contracted pelvis should be hospitalized some 2 or 3 weeks prior to the anticipated labour.

Contracted pelvis is diagnosed by the study of the history, examination of the woman, measurement of her pelvis, and vaginal examination.

Information on previous rickets, tuberculosis of bones and joints, infantilism, fractures of the bony pelvis and the lower extremities is very important. An obstetric anamnesis is important for multiparous women. If a multipara with a contracted pelvis had previously normal pelvic delivery, she may at-

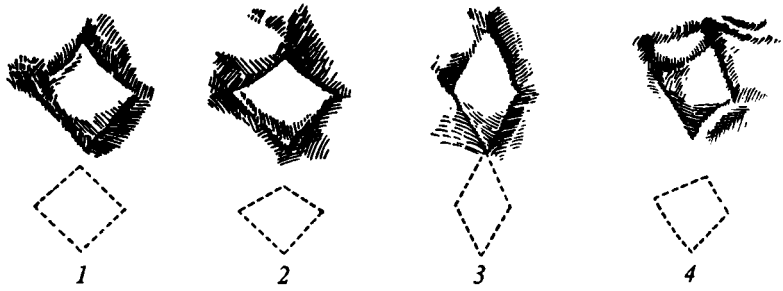

Fig. 261. Michaelis' rhomboid in contracted pelvis:
1 — normal pelvis; *2* — flat rachitic pelvis; *3* — justo minor pelvis; *4* — Naegele's pelvis

tempt a new delivery through the natural birth canal. An unfavourable obstetrical anamnesis (complicated previous labour, obstetrical operations, stillbirths, etc.) helps diagnose both anatomical and clinical contracted pelvis. Short women with signs of infantilism, rachitic changes in the skeleton, ankylosis, and dislocations of the hip joint may have contracted pelvis.

The shape of the Michaelis rhomboid is very important for the diagnosis. The rhomboid is regular with normal pelvis while in flat rachitic pelvis its upper portion is smaller; if the rachitic distortion is marked, the rhomboid al-

Fig. 262. Pointed (acuminate) abdomen

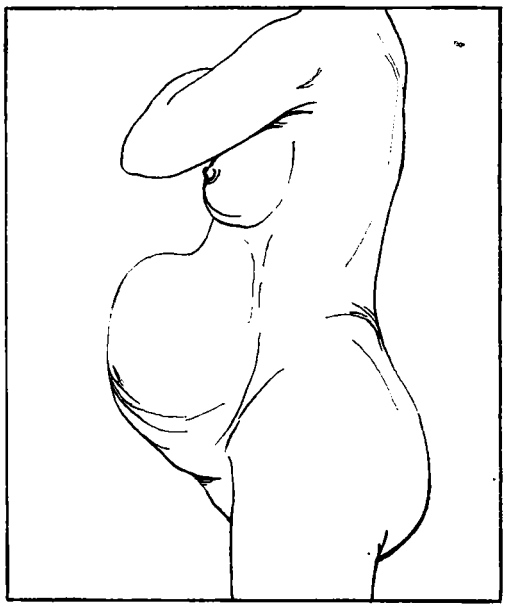

Fig. 263. Pendulous abdomen

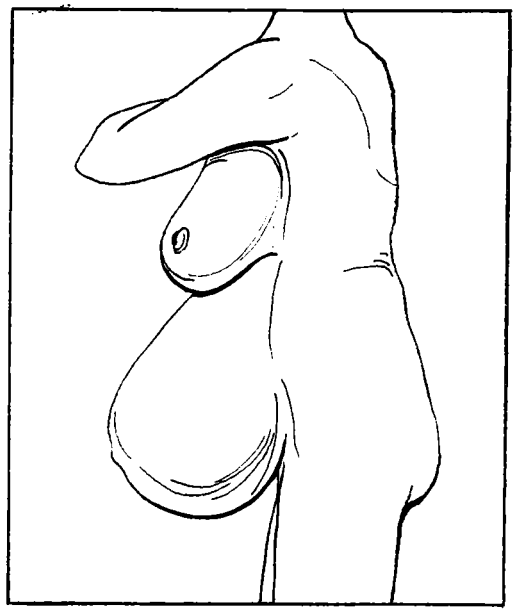

most turns to a triangle. In a generally contracted pelvis the rhomboid is elongated in the vertical direction so that its upper and lower angles are acute while the lateral are obtuse (Fig. 261).

The shape of the abdomen is also changed in marked contracture of the pelvis. The foetal head fails to enter a contracted pelvis at the end of pregnancy and floats high above the inlet till the onset of labour. The uterine bottom does not therefore 'drop' at the end of pregnancy. The growing uterus fails to be held inside the abdominal cavity (which is shorter in short women) annd deviates upward and anteriorly. An acuminate abdomen is thus formed in primigravida in whom the abdominal wall is resilient (Fig. 262), while in multiparous women the abdomen becomes pendulous (Fig. 263). During examination of the pregnant it is necessary to pay attention to the thickness of the pelvic bones. To this end the wrist girth is measured (Soloviev's index). If the girth exceeds 14 cm, the bones of the skeleton, the bony pelvis included, are massive.

Pelvic measurements are especially important. The dimensions of the false pelvis are to a certain measure indicative of the capacity of the true (small) pelvis. The degree of pelvic contracture can more accurately be assessed by measuring the diagonal conjugate. The diagonal conjugate should therefore be obligatory measured in all pregnant women. To this end the pregnant is given a vaginal examination during which the examiner establishes the absence of flattening of the sacrum or other distortions of the bony pelvis, determines approximately the capacity of the pelvis, palpates the sacral promontory (if it can be reached by the examining finger) and determines the diagonal conjugate.

If any suspicion arises that the pelvis might be contracted at its outlet, its anteroposterior and transverse diameters are measured. To prognosticate labour and delivery, it is necessary to know not only the main pelvic measurements but also the size of the intrauterine foetus. To this end, the foetal length and the occipitofrontal diameter of the foetal head are measured by a pelvimeter through the abdominal wall.

Pregnancy

The first half of pregnancy in a contracted pelvis is uneventful, but late pregnancy toxaemia often develops in the second half. The head fails to enter the narrow pelvic inlet and the uterine bottom rises high to displace the diaphragm superiorly. The pregnant often develops dyspnoea, tachycardia and fatigue.

The failure of the head to engage accounts for increased mobility of the foetus. Hence the higher incidence of breech, transverse and oblique presentations. Mobility of the head is the cause of high incidence of face, brow, and vertex presentations. Asynclitism is another cause of a pendulous abdomen.

A mobile head does not form the ring of engagement and the amniotic fluid is not separated into two portions. The whole bulk of the amniotic fluid is therefore pressed by the uterine contractions into the lower pole of the conceptus (Fig. 264 and 265). The amniotic fluid is often discharged prematurely (before the onset of regular contractions) in a contracted pelvis.

All pregnant with contracted pelvis should be specially observed during pregnancy. In the second half of their

pregnancy they should wear a bandage. If any deviations from normal course of pregnancy are detected the woman should be examined by the doctor. Two or three weeks prior to delivery the pregnant should be hospitalized.

If necessary, the pregnant should be examined by X-rays to determine the main diameters of the pelvis and the foetal head.

Labour

Spontaneous pelvic delivery is impossible in contractures of the third and the fourth degree. Unless surgical aid is given, the mother and the foetus die due to the uterine rupture, sepsis, or other complications. In the first and the second degree of contracture the outcome of labour depends on the size and presentation of the foetus, molding properties of its skull, the type of engagement and effectiveness of labour forces. If these requirements combine favourably, labour may end spontaneously, especially in the first degree of contracture. Dangerous complications develop in cephalopelvic disproportion and malpresentation of the foetus. Complications are more frequent in the second than in the first degree of contracture.

Contracted pelvis is often attended with early loss of the amniotic fluid because the forewater is not separated by the engagement ring from the main bulk of the amniotic fluid. The umbilical cord or an arm may prolapse with the gush of the fluid. If timely obstetrical assistance is not given, the umbilical cord will be compressed by the head against the pelvic wall to cause foetal death from asphyxia. The prolapsed arm will even more decrease the capacity of the contracted pelvis and will thus contribute to the difficulties in the expulsion of the foetus.

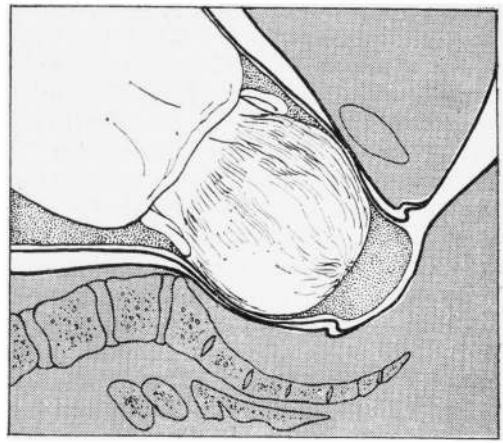

Fig. 264. As the vertex engages a normal pelvis it divides the amniotic fluid into two portions

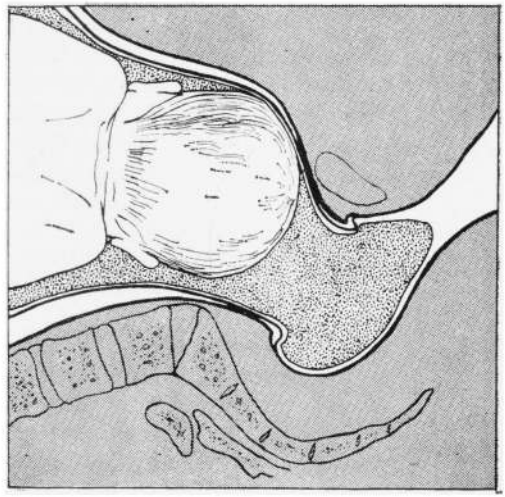

Fig. 265. The vertex floats over the entrance to the pelvis and fails to divide the amniotic fluid.

Early and premature escape of the amniotic fluid usually slows down the dilation of the cervix. Uterine contrac-

tions become more painful and the first stage of labour more delayed (dry labour). If the 'dry' period becomes prolonged, infection from the vagina may penetrate the uterus to cause inflammation of the decidua (endometritis) and other membranes of the conceptus. The body temperature is elevated, pulse accelerates, and a smelling turbid liquid is discharged from the uterus.

Dystocia is a frequent complication of labour in contracted pelvis. Uterine inertia often develops in women with infantilism and previous complicated delivery and puerperal diseases. The contractions are rare and ineffective from the very beginning of labour (primary uterine inertia); or labour may first be forceful but later secondary uterine inertia will develop.

The greatest difficulties arise in the second, expulsive stage of labour. The head remains unengaged for a long time; first it is movable but later becomes fixed against the pelvic inlet and begins slowly descending with its smaller segment (in the absence of cephalopelvic disproportion). Under the thrust of the uterine contractions the engaged head molds considerably to adapt to the narrow configuration of the pelvis.

The expulsive period is as a rule prolonged, and much effort is required on the part of the mother to propell her foetus through the narrow passage of the contracted pelvis. If the foetus meets strong resistance, tumultuous and violent contractions may develop which will overdistend the lower uterine segment. The uterus may rupture in cephalopelvic disproportion. Some women develop secondary uterine inertia after tumultuous labour: the uterus stops contracting, the foetus dies, endometritis develops, and finally grave sepsis will endanger the mother's life.

Other grave complications may also develop in obstructive labour. Prolonged engagement of the head or its presence in the pelvic cavity compresses the soft tissues of the reproductive tract between the bony pelvis and the foetal head. The cervix, the vagina, and also the bladder and the urethra anteriorly, and the rectum posteriorly are compressed. The compression interferes with normal circulation. Cyanosis and oedema of the cervix and the bladder wall, and later of the vagina and external genitalia, develop. Compression of the urethra and the bladder arrests urination. Necrosis develops as a result of prolonged compression. The necrotized tissues are rejected in five or seven days to form urogenital and rectovaginal fistulae. Oedematous cervix and difficult urination indicate soft tissue compression; blood in the urine is another dangerous sign indicating possible fistula. The nerves can also be compressed with subsequent development of paresis of the leg muscles. If the head passes the pelvis with considerable difficulty, the symphysis may be damaged. The puerpera feels pain when she moves her legs, her walk is affected; palpation of the symphysis is painful and a slit can be detected in the point of junction. The same symptoms often develop during pregnancy attended with excessive softening of cartilage and ligaments of the symphysis due to upset metabolism.

Complications on the part of the foetus often develop in contracted pelvis. Prolonged labour and frequently occurring dystocia may interfere with the uteroplacental circulation and cause foetal distress. The developing asphyxia may become the cause of haemorrhage in the brain and other organs of the foetus. Cerebral bleeding intensifies in strong compression of the head and

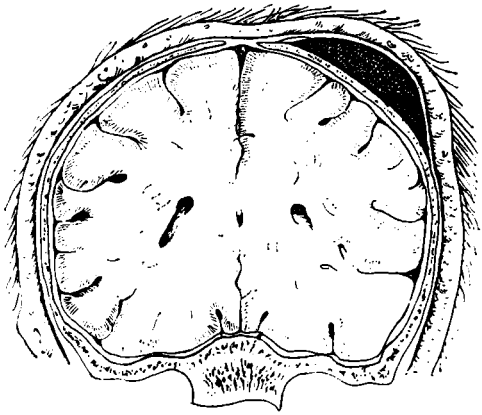

Fig. 266. Cephalohaematoma

excessive dislocation of the skull bones. Blood from the broken vessels can penetrate the space under the parietal bone (or bones) to cause cephalohaematoma (Fig. 266). A large swelling on the head is often formed, and the skull bones may sometimes become indented or fractured (Fig. 267).

The clavicle or the arm may fracture during delivery.

The incidence of stillbirths, perinatal death and puerperal diseases is much higher in contracted pelvis. But these complications may often be absent or are not pronounced. In the absence of cephalopelvic disproportion, or if the disproportion is not marked, pregnancy may end by spontaneous delivery. The mechanism of labour is different for each particular contracted pelvis, and the foetus performs a certain set of rotational movements as it progresses through the birth canal.

Mechanism of Labour

The mechanism of labour in contracted pelvis is different from normal. Furthermore, each type of contracted pelvis accounts for a different mechanism of labour.

Mechanism of labour in justo minor pelvis. The head meets uniform resistance from all bones of the pelvis. This resistance is overcome by a strongly flexed vertex, so that the head enters the pelvis with its suboccipitoparietal diameter, which is smaller than the suboccipitobregmatic diameter by which the foetus enters the pelvis in normal mechanism of labour.

The *first feature* of the mechanism of labour in justo minor pelvis is the *strongly flexed vertex* (Fig. 268); the

Fig. 267. Indentation on the foetal skull (contracted pelvic delivery)

Fig. 268. Engagement of the vertex in justo minor pelvis (strong flexion and molding)

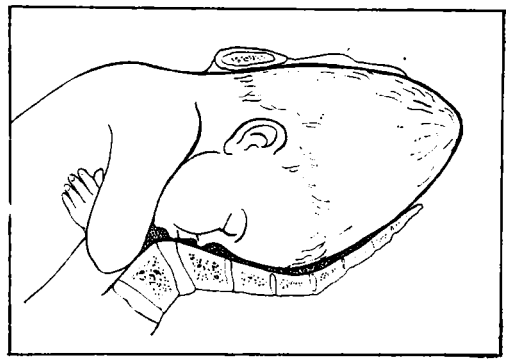

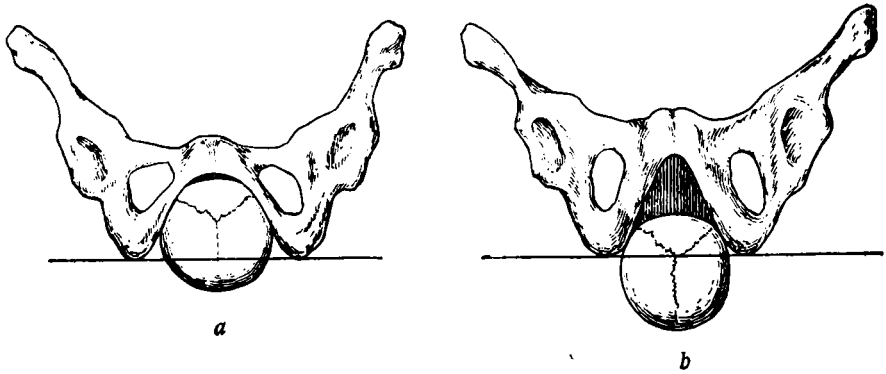

Fig. 269. Disengagement from a justo minor pelvis:
a — normal pelvis; posterior cranial fossa rests over the pubic arch; *b* — justo minor pelvis; an acute pubic angle fails to accommodate the occiput; the head is displaced posteriorly to overdistend the perineum

posterior fontanelle approximates the geometrical centre of the pelvis.

The *second feature* is that the sagittal suture of the engaging head aligns with an oblique diameter of the pelvic inlet plane. The biparietal diameter of the head passes the oblique diameter of the pelvis which is longer than the anteroposterior diameter. A strongly flexed head descends into the pelvic cavity and then performs the same movements as in normal mechanism of labour: the internal rotation, extension, and external restitution (rotation). The only difference is that all rotations are comparatively slow and require much effort on the part of the parturient.

Because of the narrow pubic angle, the posterior cranial fossa cannot come in direct contact with the symphysis as the head passes pelvic outlet plane (Fig. 269). The head is therefore displaced toward the perineum to a greater extent than in normal pelvis; the perineal tissues undergo greater extension and if obstetrical assistance is not given in due time, deep laceration of the perineum may occur. The head of the delivered foetus is elongated in the direction of the occiput and a considerable swelling is formed in the region of the posterior fontanelle.

Mechanism of labour in flat rachitic pelvis. The deviations from the normal mechanism of labour depend on the shortened anteroposterior diameter of the pelvic inlet plane.

The *first feature* is that the sagittal suture aligns with the transverse diameter of the pelvic inlet plane for a long time. Since the anteroposterior diameter is shorter than normal, the head fails to engage, and preserves this position for many hours, even with adequately forceful contractions.

The *second feature* is insignificant deflexion of the vertex as a result of which the anterior fontanelle assumes the position below the posterior fontanelle. With this degree of vertex deflexion, the foetal head will pass the smallest pelvic diameter, the true conjugate, with its smaller transverse diameter (8.5 cm), while the larger biparietal diameter (9.5 cm) deviates

aside towards the greater space.

The *third feature* is asynclitism (Fig. 270). Anterior asynclitism occurs more frequently than posterior one. In anterior asynclitism the posterior parietal bone rests against the anteriorly displaced promontory where it is retained, while the anterior parietal bone descends gradually into the pelvis. The sagittal suture is now situated nearer the promontory. In this position (with the sagittal suture aligned with the transverse diameter, closer to the promontory, and the anterior fontanelle below the posterior one) the head remains engaged until it is sufficiently molded, after which the posterior parietal bone slips off the promontory and the asynclitism disappears; the head is now flexed and the further mechanism of labour is the same as in anterior occiput presentation (internal rotation, extension, and external restitution of the head).

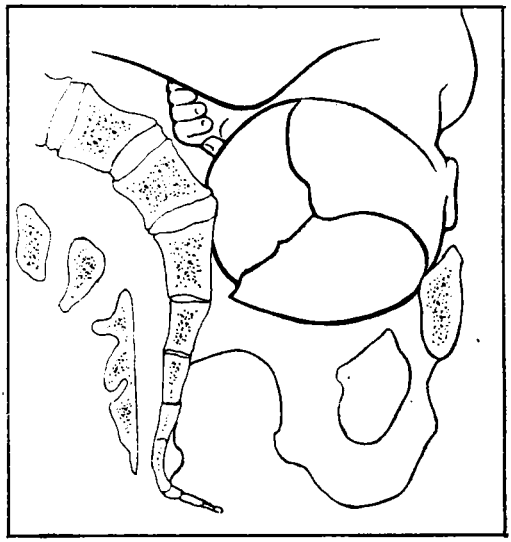

Fig. 270. Engagement of the head in a flat rachitic pelvis. The sagittal suture is in the transverse diameter closer to the sacral promontory (anterior asynclitism)

After the head has passed the contracted inlet plane of the pelvis, the expulsion of the foetus becomes very rapid because the pelvic cavity is normal or enlarged, while the outlet pelvic plane is wider than normal. After a prolonged retention at the pelvic inlet the foetus is then sometimes extremely rapidly propelled through the midpelvic and outlet pelvic planes (precipitate labour). If the obstetrician is not prepared to give assistance, the perineum may lacerate due to the rapid passage of the head through the vulvar ring. The presenting parietal bone of the delivered head bears a large swelling; the shape of the head may be oblique, and an indentation can be found on the posterior parietal bone resulting from a prolonged compression against the promontory.

Mechanism of labour in simple flat (platypellic) pelvis. The head enters the pelvis in the same way as in flat rachitic pelvis. Further it descends into the pelvic cavity and is delivered as in the occiput presentation. But sometimes the head fails to perform the internal rotation because the anteroposterior diameters of the midpelvic and outlet pelvic planes are reduced in the same way as the anteroposterior diameter of the pelvic inlet. The head enters the pelvic cavity and sometimes even reaches the pelvic floor, while the sagittal suture remains aligned with the transverse diameter. In some cases the head rotates with its occiput anteriorly as it reaches the pelvic floor and labour then ends spontaneously. Otherwise complications arise (secondary uterine inertia, foetal asphyxia, etc.), which indicate operative parturition.

Mechanism of labour in generally contracted flat pelvis. It is the same as

in justo minor or flat pelvis (depending on the prevalence of specific features of this or that type of contracture). Labour in generally contracted flat pelvis is usually difficult.

Conduct of Labour

Labour in women with contracted pelvis should be conducted in hospital under observation of a physician. This is necessary because various complications requiring operative parturition may arise. An obstetrician should observe carefully the parturient and receive delivery if it ends spontaneously.

A caesarean section is performed on women with the third and the fourth degrees of contracture at the end of pregnancy or at the beginning of the dilation stage.

Watchful expectancy is recommended in the first and second degrees of pelvic contracture. The obstetrician should observe carefully the condition of the mother and the foetus and the progress of labour. A recourse to surgery is only made if complications develop that endanger the mother or the foetus. This principle is justified because the outcome of labour depends not only on the pelvic diameters but also on the intensity of uterine and abdominal contractions, the size of the foetus, molding of the foetal skull, etc. Whether or not a given contracted pelvis is narrow in the clinical (functional) aspect can be decided only in the course of labour.

The parturient should be thoroughly inspected and examined on admission to the hospital and her history be recorded. Her internal organs are examined, the pelvis measured, the Michaelis rhomboid inspected, and finally the woman is given a vaginal examination. To preclude early escape of the amniotic fluid, the parturient is placed in bed and recommended to lie on the side where the occiput is identified. This will promote the lowering of the foetal occiput and prevent the escape of the fluid. After the discharge of the amniotic fluid, the woman is given another vaginal examination in order to clear out whether or not the umbilical cord or the arm have prolapsed. Labour in contracted pelvis is rather prolonged; the parturient becomes tired, her resistance decreases, and she should therefore be given nutritive and easily assimilable food. The urinary function of the parturient should be observed thoroughly and the external genitalia washed in due time. If urination is difficult, the bladder should be evacuated by catheterization with observation of aseptic rules. Uterine stimulants should be given in uterine inertia. If the parturient is fatigued, she is allowed a rest; to this end promedol (1-2 ml of a 1 per cent solution) or pantopon (1-1.5 ml of a 1 per cent solution) should be given subcutaneously; ether shall be given to enhale for 25-30 minutes. The parturient falls asleep and in a lapse of time her labour forces become more intense.

If uterine inertia develops as a result of the abdomen sagging and thinning of its wall, the use of Verbov's bandage is recommended (in the absence of cephalopelvic disproportion).

If violent contractions develop during the expulsive stage of labour attended with thinning and overdistension of the lower uterine segment and the high position of the contraction ring, the parturient should be given ether anaesthesia (or 1 ml of a 1 per cent morphine solution), since the uterus can otherwise rupture. Anaesthesia comes down the convulsions and the danger

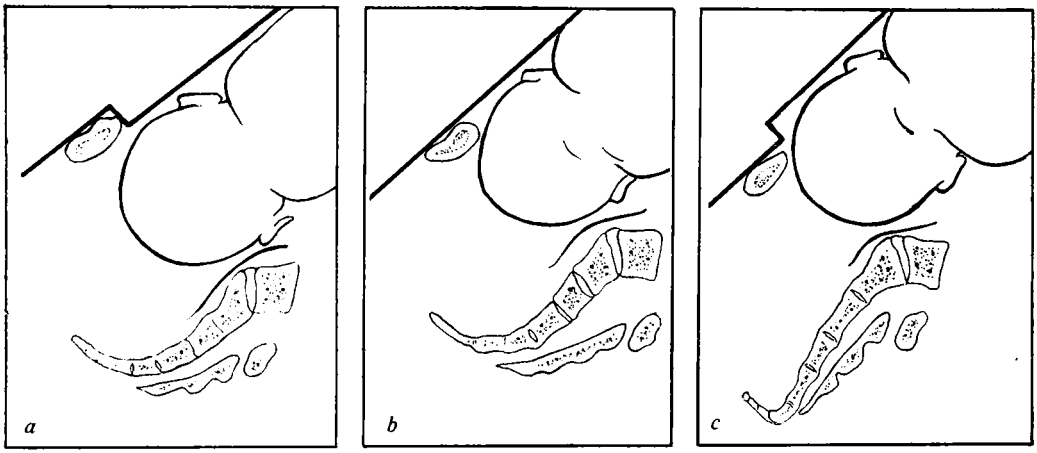

Fig. 271. Vasten's sign:
a — negative sign (absence of cephalopelvic disproportion; *b* — insignificant cephalopelvic disproportion; *c* — positive sign (pronounced cephalopelvic disproportion)

of the uterine rupture is removed; labour is ended operatively.

The obstetrician observes carefully the presenting part: whether it is over the pelvic inlet or descends gradually into the pelvic cavity. The obstetrician may establish cephalopelvic disproportion as well. In addition to commonly used methods of establishing the cephalopelvic disproportion the Vasten sign can also be used (Fig. 271).

The Vasten sign can be used to determine the cephalopelvic disproportion after engagement of the head. The palm of an examining hand is placed on the surface of the symphysis and then moved upwards onto the region of the presenting head. If the anterior surface of the head is above the symphysis plane, it indicates cephalopelvic disproportion (positive Vasten's sign). Labour cannot end spontaneously. If the disproportion is not pronounced, the anterior surface of the head levels with the symphysis. If the labour forces are effective and the head molding is adequate labour can end spontaneously. If uterine inertia develops, spontaneous delivery becomes impossible, especially if the foetal head is large and rigid. In complete absence of any cephalopelvic disproportion, the anterior surface of the head is below the symphysis plane (negative Vasten's sign) and labour would usually end spontaneously.

Zangemeister suggested that the presence and degree of elevation of the anterior surface of the head over the sacrum might be measured by a pelvimeter with the parturient lying on her side. The external conjugate is first measured, and the pelvimeter bulb is then moved from the symphysis onto the most prominent point of the anterior surface of the foetal head (the posterior bulb of the pelvimeter remaining at the former point). Normally the external conjugate exceeds the distance from the head to the suprasacral dimple by 3-4 cm. If there is a cephalopelvic disproportion, the latter distance is greater than the external conjugate. If both distances are

equal, the cephalopelvic disproportion is not manifest and prognosis is uncertain.

The foetal heart function should be observed with special care. In early or premature loss of the amniotic fluid, or in dystocia and other complications of labour, steps to prevent foetal asphyxia should be taken. A persistent change in the heart tones, and discharge of meconium in cephalic presentation indicate that parturition should be accelerated; forceps delivery is often indicated in such cases.

A recourse to a caesarean section is often required. Indications for the abdominal hysterotomy are cephalopelvic disproportion, threatened rupture of the uterus or formation of a fistula, an unfavourable engagement of the head, and other complications that worsen the prognosis. Destructive operations on the foetus are indicated if it is dead.

The conduct of labour in contracted pelvis requires high professional skill and personal qualities on the part of the medical personnel. Considerate attitude to the parturient and care of her psyche are very important for the successful outcome of labour. Possible complications should be revealed and measures to remove them taken in due time.

Chapter Twenty-five

BLEEDING DURING PLACENTAL STAGE OF LABOUR AND IN EARLY HOURS OF PUERPERIUM

Bleeding During the Placental Stage of Labour

Complications in the placental stage of labour are more frequent than during the dilation and the expulsive stages. The most frequent and dangerous complication of the placental stage is bleeding.

Haemorrhage is normal for the placental stage of labour and the loss of 250 ml during the separation and delivery of the placenta is considered physiological. After separation of the placenta, the uterus contracts. This is followed by (a) expulsion of the separated placenta and (b) compression of the bleeding uterine vessels and cessation of the haemorrhage.

If contractions of the uterus are weak, the normal separation of the placenta is upset. The placenta fails to separate completely, but until the entire placenta is separated the uterus does not contract and the vessels at the site of the separated placenta continue bleeding.

If the placenta has separated from the uterine wall but is retained inside the uterus, bleeding develops as well. The uterus fails to contract adequately until the placenta is expelled from it, and the vessels continue bleeding because of the lack of compression. Haemorrhage in the placental period may also be caused by lacerations of the soft tissues of the reproductive tract, the cervix, the vagina, and the perineum (see Ch. 26). But the haemorrhage is mostly connected with the abnormal separation of the placenta from the uterine wall and its expulsion. These causes in turn depend on the following:

1. *Decreased tone and inadequate contractility of the uterus, i.e. uterine hypotony.*

Some authors refer to this condition as atony, but atony is a complete loss of the tone and contractility which occurs much less frequently than hypotony.

Hypotony of the uterus which accounts for the retention of the placenta and haemorrhage may develop on the following occasions:

(a) full bladder and/or the rectum;

(b) underdeveloped uterus (infantilism) which is usually attended with the decreased tone of its muscles;

(c) overdistention of the uterus due to multiple pregnancy, large foetus, or polyhydramnios;

(d) changes in the uterine walls (fibromyoma, sequelae of inflammatory diseases) which decrease the contractile power of the uterus;

(e) excessively forceful uterine contractions causing fatigue of the parturient and exhaustion of the uterine tone.

2. *Incorrect conduct of the placental stage.* The conduct of the placental stage of labour should be expectant; any attempt to accelerate the separation

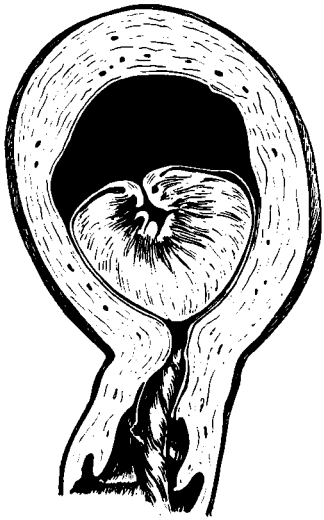

Fig. 272. Incarceration of placenta

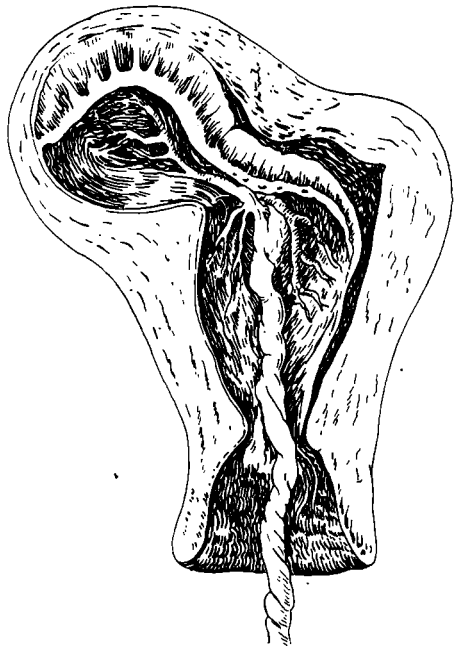

Fig. 273. Retention of part of the placenta in the tube angle

of the placenta (traction by the umbilical cord, stimulation of the uterus, etc.) will upset the rhythm of the uterine contractions and interfere with the normal separation of the placenta. This will involve its incomplete separation, or incarceration of the separated placenta by a spastically contracted cervical os (Fig. 272).

3. *Specific implantation of the placenta.* Implantation of the placenta in the lower segment of the uterus (placenta praevia) or in the tubal angle is often the cause of bleeding in the placental stage of labour (Fig. 273). Insufficiently strong contractions in this portion of the uterus account for the upset mechanism of placental separation and hence bleeding.

4. *Adherent placenta.* Partial adherence of the placenta is the cause of inevitable bleeding in the placental stage. But true adherence of the placenta (placenta accreta) occurs in rare cases, and partial adherence over a limited area is more frequent (see Ch. 16). Part of the adherent placenta is separated from the uterine wall and the disrupted uterine vessels begin bleeding. The haemorrhage continues until the placenta is expelled from the uterus.

Bleeding begins soon after the delivery of the foetus or in a certain lapse of time (30-60 min). Within a short period of time the puerpera may lose from 500 to 1000 ml (and over) of blood. The blood loss is sometimes as high as 1500 ml. Haemorrhage is usually external; all blood freely flows out of the birth canal. But the cervical os may be closed by a spasm or a lot-

of the placenta (or a clot of coagulated blood), and the blood will then accumulate inside the uterus. External bleeding is absent in such cases while the puerpera develops signs of acute anaemia.

Bleeding in the placental stage of labour causes anaemia the degree of which depends on the amount of the blood lost and on the health of the woman. Asthenic women and also women who had hypotension before labour develop an especially negative response to the loss of blood.

Developing anaemia is characterized by pallid skin and visible mucosa, decreased arterial pressure, accelerated pulse, vertigo, noise in the ears; if the blood loss is significant, the pulse becomes thready, the arterial pressure drops, and dyspnoea develops; the patient may die unless medical aid is given in due time.

Prophylaxis of blood loss in the placental stage consists in accurate adherence to the rules of conducting labour (see Ch. 9). The condition of the puerpera, the amount of the blood lost, and the urinary function should be carefully observed; stimulation of the uterus or traction by the umbilical cord is not recommended. Ergot and its preparations, which cause spasms of the uterine muscles, are prohibited. If profuse bleeding is anticipated (polyhydramnios, twin pregnancy, etc.), 1 ml of pituitrin may be given after delivery of the foetus (provided the arterial pressure is not elevated). Pituitrin causes rhythmic contractions of the uterus. Oxytocin is also recommended.

Treatment. Urgent steps to discontinue bleeding and to fight anaemia should be taken.

The uterus may be contracted and bleeding stopped only after the uterus has been emptied. The placenta shall therefore be quickly removed from the uterus. If the placenta has separated, it can be extruded by external manipulations. If the placenta remains attached, the external manipulations may prove ineffective, and manual removal of the placenta is therefore recommended.

When bleeding starts, it is necessary to check immediately if the placenta has separated. If the signs of placental separation are positive, the placenta shall be removed by the Abuladze or Credé manoeuvre (see Ch. 9). In the absence of these signs an attempt should be made to extrude the placenta by the Credé manoeuvre (with anaesthesia). It sometimes fails because of the spasm of the internal cervix os; anaesthesia removes the spasm and the placenta can thus be removed. If the Credé manoeuvre (with anaesthesia) proves ineffective, a recourse to manual separation of the placenta should be made.

An independently working obstetrician cannot give anaesthesia and the placenta should therefore be removed by her manually immediately after the failure to extrude it by the Credé manoeuvre without anaesthesia.

Manual Separation and Removal of the Placenta

The invasion of the uterus by the obstetrician hand for separation and removal of the placenta (or its separate parts that may be retained in the uterus) is always fraught with danger of infection. The microflora of the vulva and the vagina inevitably contaminates the obstetrician hand. The microbes carried into the uterus by the hand penetrate the disrupted blood and lymph

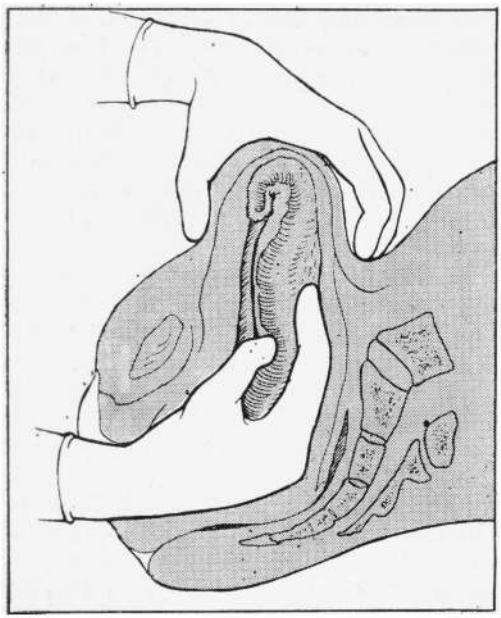

Fig. 274. Manual separation of the placenta

vessels of the uterus. Septic diseases often develop in puerperas after manual invasion of the uterus and this operation should therefore be done only for special indications and with strict observation of the asepsis rules.

Indications for manual separation and removal of the placenta are as follows: (a) bleeding in the puerperium (if the placenta fails to be removed by external manoeuvres); (b) retention of the placenta in the uterus for more than two hours (after failure of its removal by the Abuladze and Credé manoeuvres). If the placenta is retained for a long period of time, it should be removed manually even if the blood loss is inconsiderable.

Indications for the manual intrauterine examination after the delivery of the placenta are (a) retention of parts of the placenta, and (b) if any suspicion arises concerning intactness of the delivered placenta.

Management. The patient is placed on a transverse bed and her bladder is evacuated. The external genitalia are treated as for an obstetrical operation (see Ch. 28). The operator's hands are washed thoroughly, disinfected, and the internal hand is lubricated with ample sterile vaseline oil. The operation is performed on an anaesthetized patient, except in rare cases when the operation is performed by an unassisted obstetrician.

The pudendal cleft is separated by the left hand and a conically shaped right 'obstetrician hand' is introduced into the vagina and further into the uterus. The invading hand should be directed with its palm toward the symphysis. The left hand should then be placed on the bottom of the uterus.

In order not to mistake the oedematous margin of the os for the placental margin, the right hand should follow the umbilical cord as it is introduced into the uterus. As soon as the right hand, guided by the umbilical cord, reaches the placenta, its margin should be examined for the degree of separation. The hand should be inserted in space between the placenta and the uterine wall; while the right hand acts like a saw to separate the placenta, the left hand should press gently on the uterine bottom to aid the internal hand (Fig. 274). As soon as the entire placenta has thus been separated, it should be pulled by the umbilical cord toward the lower uterine segment and extracted from the uterus by the left hand. The internal (right) hand remains in the uterus to examine it for complete removal of the placenta. When the entire placenta has been removed, the uterine walls become smooth except the placental site which

is slightly rough. Remnants of the decidual membrane may remain on the placental site.

After the uterine cavity has been examined thoroughly, the hand should be removed from the uterus, and 1 ml of ergot preparation and 1 ml of pituitrin should be given subcutaneously; an ice bag should be placed on the lower abdomen and blood (plasma, or blood substitute) transfused in case of anaemia. If bleeding persists, further measures to control haemorrhage should be taken.

In the presence of complications (before the manual separation and removal of the placenta) predisposing to puerperal infection (prolonged labour, long 'dry' period, signs of endometritis, etc.), sulpha drugs should be given 4 or 5 times a day (in 1 g doses) during the course of two or three days. Penicillin (50 000-100 000 units), or other antibiotics, may be given at three-hour intervals for two or three days.

The separation of the placenta or its retained parts is usually not difficult. In placenta accreta the placenta fails to be separated, and attemps to separate it manually will cause uterine perforation and death of the patient. The uterus should therefore be extirpated. An independently working obstetrician should pack the uterus with sterile gauze, summon a doctor or deliver the patient to the hospital.

Bleeding During the Early Hours of Puerperium

Bleeding after the delivery of the placenta is a frequent obstetrical pathology. Bleeding in the early hours of the puerperium depends on the following:

1. *Retention of parts of the placenta in the uterus.* Even small portions of the placenta that may remain in the uterus after its delivery interfere with normal contraction of the uterus. The disrupted vessels of the placental site therefore continue bleeding. Parts of the placenta may be retained in the uterus as a result of misconduct of the placental stage of labour and in connection with the adherent placenta. These complications always involve bleeding.

In addition to haemorrhage infection may develop. The retained particles of the placenta should therefore be removed from the uterus immediately after delivery of the placenta (retention of the foetal membranes is not fraught with serious complications since they are delivered spontaneously).

2. *Hypotony and atony of the uterus.* Complete atony of the uterus occurs on relatively rare occasions. Hypotony is more frequent in the early hours of the puerperium. The uterus develops inefficient contractions and its response to stimulation (massage, cold, etc.) is weak. Since the uterus does not contract adequately, the broken vessels of the placental site continue bleeding.

The causes of hypotonic bleeding after delivery of the placenta are the same as of haemorrhage in the placental stage of labour, i.e. infantilism, multiple pregnancy, fatigue after tumultuous labour, changes in the uterine wall after previous inflammatory diseases, etc.

A hypotonic uterus is flaccid, its response to stimulation is inadequate, the size is large. An atonic uterus does not respond to stimulation (cold, massage, etc.), the muscles are flaccid, the uterus body is large, its outlines are indistinct, bleeding is profuse and rapidly causes a collapse.

3. *Lacerations of the soft tissues of the birth canal.* Lacerations of the

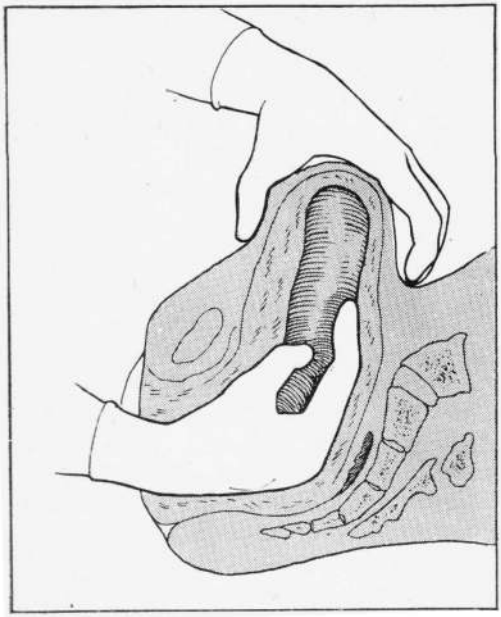

Fig. 275. Manual examination of the uterine cavity

cervix and deep lacerations of the vagina, the perineum and the external genitalia may be the cause of the bleeding in the placental stage of labour and the puerperium (see Ch. 26.)

Bleeding begins immediately after the delivery of the placenta or in a certain lapse of time; the haemorrhage, that begins during the placental stage, sometimes persists in the puerperium. The amount of the blood lost may be as high as 1000 ml and over; an acute anaemia develops (the skin and the mucosa become pallid, the pulse accelerates, the arterial pressure drops, vertigo develops, etc.).

4. *Coagulation defects* are rare causes of intrapartum and postpartum haemorrhage. In cases of hypofibrinogenaemia, afibrinogenaemia the ability of blood to clot decreases sharply or is lost completely, which becomes the cause of persistent bleeding regardless of the massage of the uterus or drugs stimulating its contractions, etc. Coagulation defects may develop in cases of longstanding foetal death in the uterus, amniotic fluid embolism, and in profuse (hypotonic or atonic) bleeding.

The *prophylaxis* of coagulation defects consists in correct conduct of the placental stage of labour, careful inspection of the delivered placenta, and prevention of lacerations of the soft tissues of the reproductive tract. The obstetrician must be prepared for the possible hypotonic haemorrhage (infantilism, polyhydramnios, multiple pregnancy, fibromyoma, etc.). She must prepare beforehand all articles that might be necessary to stop bleeding and control anaemia.

Treatment. The successful control of bleeding depends on the removal of the cause of this dangerous complication. The cause should therefore be first established and then appropriate measures taken.

If the bleeding depends on lacerations of the cervix, vagina or external genitalia, they should be repaired. If the cause of bleeding is the retention of placental remnants, the uterus should be immediately examined manually and the retained placental portions removed. In hypotonic haemorrhage measures should be taken to increase the tone and contractility of the uterus.

The *uterus should be examined manually* if the retention of placental parts is obvious and also in all doubtful cases. (The rules are the same as for manual separation of the placenta.) The examining hand feels thoroughly the uterine walls, its fundus and the tube angles (Fig. 275). An experienced physician can examine the uterus and remove the retained placental parts using a dull curette (provided the uter-

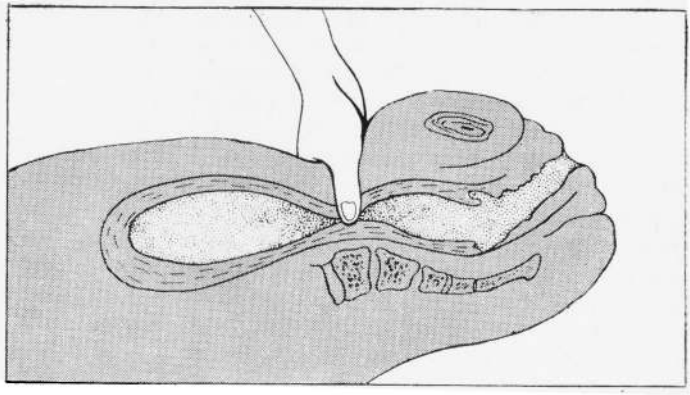

Fig. 276. Pressing the lower uterine segment to the vertebral column

ine tone is adequate). After the placental remnants have been removed, the uterus contracts and bleeding stops. After manual examination of the uterus for special indications (signs of developing endometritis and other complications predisposing to infection), antibiotics or sulpha drugs should be given to the puerpera.

Hypotonic and atonic haemorrhage is controlled as follows:

1. The bladder is evacuated. The uterus is massaged through the abdominal wall: the hand is placed on the uterine bottom and rubs it by slight circular movements (energetic movements fail to give the wanted effect). The massage stimulates contraction of the uterus and it becomes firm. A clot of blood is expressed from the uterus. Simultaneously, 1 ml of a 0.05 per cent ergotal solution or 0.5-1 ml of a 0.02 per cent methylergometrine solution is given intravenously. Oxytocin (5-8 units with 500 ml of a 5 per cent glucose solution) should be injected intravenously.

An ice bag should be placed on the lower abdomen.

If the uterine hypotony is not marked, these measures will do.

2. If bleeding fails to stop, measures should be taken to suspend or decrease the blood flow to the uterus. This will promote contraction of the uterus.

Piskacek's method. Grasp by the left hand the lower segment of the uterus and compress it (the thumb on one side and the four fingers on the other

Fig. 277. Massage of the uterus on the fist

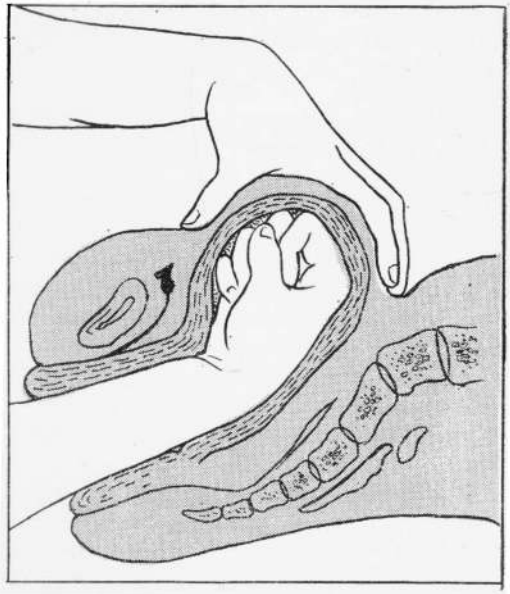

side). This will decrease the lumen of the uterine arteries and veins. At the same time rub the uterine bottom with the right hand.

Genter's method. Lower the head end of the bed, compress the lower uterine segment by the left hand (as in the Piskacek method), pull the uterus strongly upwards and press the lower segment against the spinal column (Fig. 276). To add to the effect, rub the uterus with the free hand. Continue doing so for 10-15 minutes. The uterine vessels are thus compressed, the aorta is pressed against the vertebral column by the lower uterine segment, the blood flow to the uterus is thus decreased, and the uterus contracts.

3. If the bleeding persists, the uterus should be examined manually (if it was not examined earlier) and the blood clots and placental remnants removed, if any. Next, the inner hand is clinched into a fist, and the outer hand rubs the uterine bottom through the abdominal wall (Fig. 277).

4. Compression of the abdominal aorta. If hypotony is marked (atony), the aorta should be compressed to anaemize

Fig. 278. Compression of the abdominal aorta by the fist

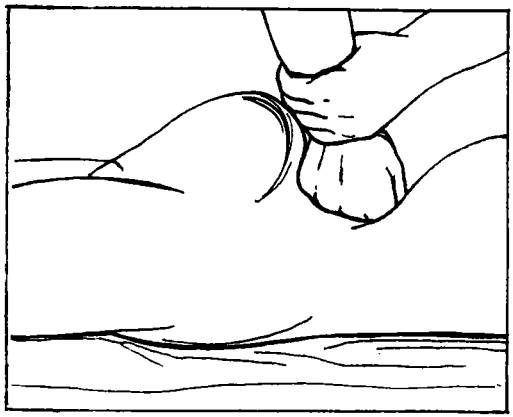

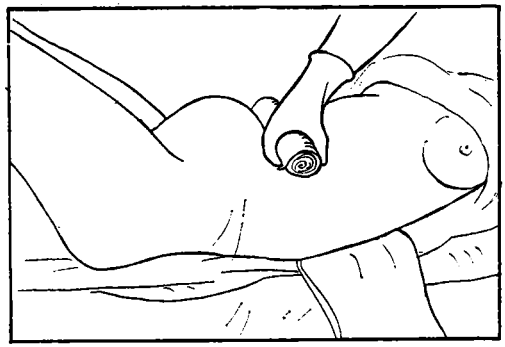

Fig. 279. Compression of the abdominal aorta by a roll

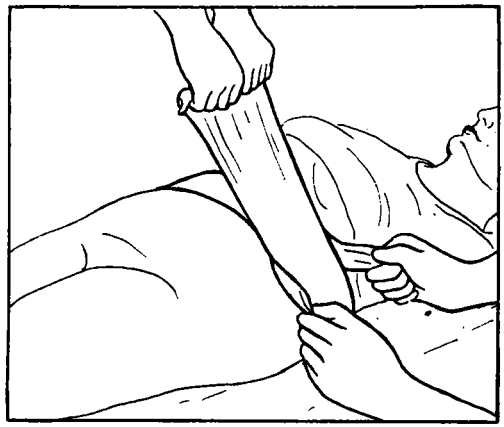

Fig. 280. Tight bandaging of the roll to the abdomen

the uterus. The obstetrician should assume her position by the patient's side and, using the back surface of the main phalanges, press the abdominal aorta to the spinal column through the abdominal wall (Fig. 278). If the hand becomes tired, it should be assisted by the other hand which should grasp the wrist of the pressing hand. The aorta can also be pressed against the spinal column by the fingers of both hands (the Biryukov method), or by a soft roll which should be pulled

tightly to the abdomen by bandaging (Figs. 279 and 280).

5. Packing. If these measures fail or give only temporary effect, the uterus should be packed with a wide strip of sterile gauze. This facilitates formation of thrombi in the blood vessels and contraction of the uterus. The negative aspect of this method is the risk of infection. Asepsis rules should therefore be strictly followed while packing the uterus. The external genitalia should be washed thoroughly (as for obstetrical operations). Wide specula are inserted into the vagina, the cervix is pulled to the vaginal orifice by forceps, and a long strip of gauze is packed into the uterine cavity by a long curved forceps (packer). The entire cavity (from the fundus to the cervix) should be packed. The cervix is then released and the vagina packed as well. The gauze may remain in the uterus for eight to ten hours.

6. If atonic haemorrhage is not stopped by these measures, the uterus should be extirpated or its vessels ligated.

7. If bleeding is due to hypo- or afibrinogenaemia, citrated blood should be transfused; fibrinogen, protamine sulphate, epsilon-aminocaproic acid and other substances increasing blood coagulability should be given intravenously.

Control of Acute Anaemia

Acute anaemia that develops as a result of postpartum haemorrhage upsets the vital functions (blood circulation, respiration, metabolism, etc.), decreases the resistance of the body and may become the cause of puerperal death. In addition to the measures aimed at discontinuation of the bleeding, steps should also be taken to control anaemia.

1. The head end of the bed should be lowered to facilitate the blood supply to the brain.

2. The patient should be warmed up on all sides by hot water bags; the occipital region also needs warming and a hot water bag should be placed under the back of the head. Care should however be taken to prevent burns.

3. Blood transfusion is an important measure to control anaemia. The amount of blood to be transfused should comply with the gravity of anaemia. Blood transfusion rapidly restores the upset bodily functions. In grave shock and agony blood should be administered into the arteries under pressure.

4. In the absence of conditions for blood transfusion, ample amount of liquid should be given to the patient. Coffee, hot tea with wine (or a tablespoonful of pure alcohol per glass of tea) should be given in ample quantity. From 500 to 1000 ml of a physiological saline solution containing from 5 to 8 drops of a 0.1 per cent adrenaline solution per litre should be given subcutaneously. The same quantity of a 5 per cent glucose solution may be given instead of the salt solution.

5. After stopping the bleeding, the patient should be given cardiac preparations (caffeine, camphor).

6. Oxygen should be given to the patient. If oxygen is not available, the window should be open.

If bleeding develops in the placental stage or in the puerperium, the obstetrician should immediately call for a doctor and take first measures to stop bleeding and control anaemia.

Patients recovering from postpartum haemorrhage require thorough care.

Late Postpartum Haemorrhage

Bleeding is considered late if it develops in 24 hours (and later) following

delivery. Sometimes haemorrhage develops in 10-15 days post partum.

The most common cause of late postpartum haemorrhage is retention of placental remnants in the uterus. The remnant gradually assumes the form of a polyp and becomes the cause of inevitable bleeding. Less frequently late haemorrhage is caused by retention of foetal membranes or due to infection.

If postpartum haemorrhage is due to retention of the placenta or foetal membranes, the treatment consists in their instrumental removal (curettage). This operation involves certain difficulties and can only be performed by a physician.

Cure of the infection will stop the bleeding.

Chapter Twenty-six

INJURIES IN LABOUR AND DELIVERY

Lacerations of the perineum, vulva, vagina and the cervix often occur during labour and delivery. Haematomas, separation of the pelvic bones, urogenital and rectovaginal fistulae sometimes occur in pathological labour. The most dangerous complication of labour is the rupture of the uterus.

Lacerations of the Perineum, the Vulva and Vagina

The expulsion stage of labour is attended with a marked distension of the vagina, the vulva, and the perineum. These parts of the birth canal are therefore often injured during labour and delivery. The perineum is especially predisposed to laceration, which is the most common obstetrical pathology, occurring in about 10 per cent of patients.

Lacerations of the perineum. The factors predisposing to lacerations of the perineum are as follows: (1) lack of tissue elasticity in 'elderly' primipara, scars remaining after previous delivery, and high perineum; (2) the foetal head passes through the vulvar ring by one of its diameters other than the smallest one; this occurs with premature extension of the vertex and with excessively large foetal head; (3) operative delivery (forceps delivery, etc.); (4) contracted pelvis, especially flat rachitic pelvis (rapid delivery) and infantile pelvis (narrow pubic angle); (5) ill devised conduct of labour: premature extension of the vertex and rapid delivery of the head.

The injury never occurs without warning and is usually preceded by changes that indicate the approaching laceration. As the thrust on the perineum increases with the progress of the foetal head, it becomes protruded like a dome, cyanotic and oedematous. The skin then turns pale, lustrous, and minor fissures develop on the perineum. These changes (protrusion of the perineum, cyanosis, oedema, pallidness) are signs of threatened laceration of the perineum.

A median perineotomy should then be performed, since the smooth edges of the cut wound will heal sooner than the lacerated tissues.

The following classification of perineal lacerations is offered:

First degree. The posterior fourchette is lacerated (the small area of the perineal skin and the vaginal wall are involved); the perineal muscles remain intact (Fig. 281).

Second degree. The perineal skin, the vaginal walls and the perineal muscles (except the external rectal sphincter) are lacerated (Fig. 282).

Third degree. In addition to the above described lacerations, the external sphincter ani, and sometimes the rectum wall are also involved (Fig. 283).

A rare complication of labour is the central rupture of the perineum, while

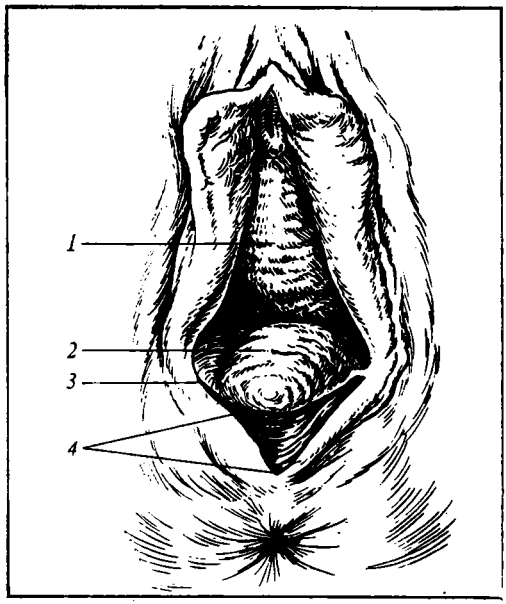

Fig. 281. First degree laceration of the perineum:
1 — anterior wall of the vagina; *2* — posterior wall of the vagina; *3* — posterior fourchette; *4* — perineal skin

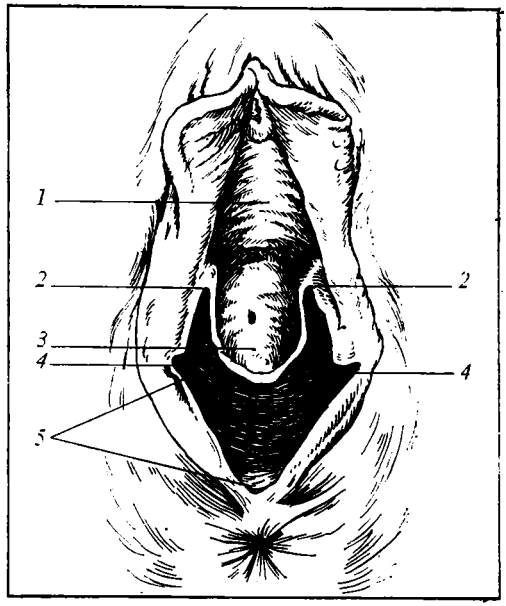

Fig. 282. Second degree laceration of the perineum:
1 — anterior wall of the vagina; *2* — upper margin of lacerated vagina; *3* — posterior wall of the vagina; *4* — posterior fourchette; *5* — perineal skin

the posterior fourchette remains intact. The foetus is then delivered not through the pudendal cleft but through the opening formed by the ruptured central perineum.

As has already been said, injury of the soft tissues of the reproductive tract, the perineum included, is fraught with danger of infection. Furthermore, even insignificant lacerations of the perineum predispose to lowering and prolapse of the reproductive organs.

Faecal and gas incontinence develops in lacerations of the third degree.

All perineal lacerations should be repaired.

Repair of Perineal Lacerations

Perineal lacerations should be sutured immediately after the delivery of the placenta. The sooner the lacerations are repaired the smaller the danger of infection. Suturing is not recommended until the placenta has been delivered because manual invasion of the uterus may become necessary if complications develop in the placental stage of labour.

All rules of asepsis should be observed in the repair of perineal lacerations. The operative field and the surgeon's arms should be treated as for obstetrical operations. An independently working obstetrician is only allowed to repair the first and the second degree lacerations. The third degree perineal laceration should be repaired by a physician.

The following tools are necessary for the repair of perineal lacerations: 2 vaginal specula, 2 elevators, 2 or 3 pair-

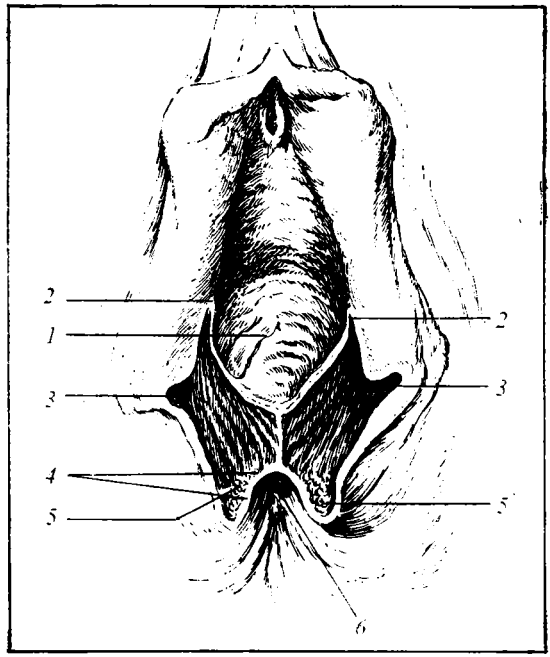

Fig. 283. Third degree laceration of the perineum:
1 — posterior wall of the vagina; *2* — upper margin of the lacerated vagina; *3* — posterior fourchette; *4* — rectal mucosa; *5* — sphincter ani; *6* — anus

ers, 3 or 4 forceps, 4 or 5 haemostatic forceps, scissors, needle holders, 3 or 4 needles of various size, a metallic catheter, and a syringe with needles for giving anaesthesia. Sterile tampons and napkins shall be necessary too. Catgut will be required for buried sutures and silk for superficial sutures. The patient should lie during repair of the perineal lacerations on the end of the operating table; her legs should be flexed on the abducted thighs and the thighs on the abdomen. Before suturing the wound should be inspected thoroughly by specula. If the obstetrician works without assistance, she should use the left hand to open the wound and using the right hand to dry up and suture the wound.

A catgut suture should be placed on the upper angle of the wound in the vaginal wall; the ends of the thread should be pulled upwards by forceps. Two forceps are used to clamp the wound edges in the region where the vaginal mucosa converts into the perineal skin. Using the ligature and two clamps, the wound is opened, dried up, and the character of laceration studied. The torn off wound edges should be removed.

The first degree perineum lacerations are repaired by placing catgut sutures on the vaginal mucosa, and then silk sutures on the perineal skin (Fig. 284). Sutures should be spaced at 1 cm intervals. The needle should be passed under the entire wound surface, since otherwise slits will remain where blood will accumulate to interfere with healing. The wound should be ligated so that its edges tightly contact each other (Fig. 285).

The order of repairing the second degree perineal lacerations is as follows: the upper angle of the wound is first

Fig. 284. Repair of first degree perineal laceration

sutured (Fig. 286), and then the lacerated perineal muscles are repaired by several buried catgut sutures (the sutures should not involve the skin or mucosa). The vaginal mucosa should then be sutured up to the posterior fourchette. The ligature ends (except at the posterior fourchette suture) should be cut off. The latter suture is pulled upward to facilitate suturing of the perineal skin. The perineal skin should be sutured with a silk thread and its ends cut off. (Metal staples can also be used.) The sutured wound should be treated with an iodine tincture.

In repairing the third degree perineal lacerations, the injured wall of the rectum should first be sutured. The separated ends of the lacerated rectal sphincter should then be identified and sutured. Next the order is the same as in repairing the second degree perineal lacerations.

The postoperative care in perineal lacerations consists in keeping the sutures clean. Sterile gauze should be used to cover the wound (renewed at 3-4 hour intervals). The wound may, however, be kept without gauze covers. When the puerpera is washed, the wound should only be dried up by a sterile pad. The suture should also be dried up after washing the external genitalia following defaecation or urination.

In cases with the third degree perineal lacerations 8 to 10 drops of an

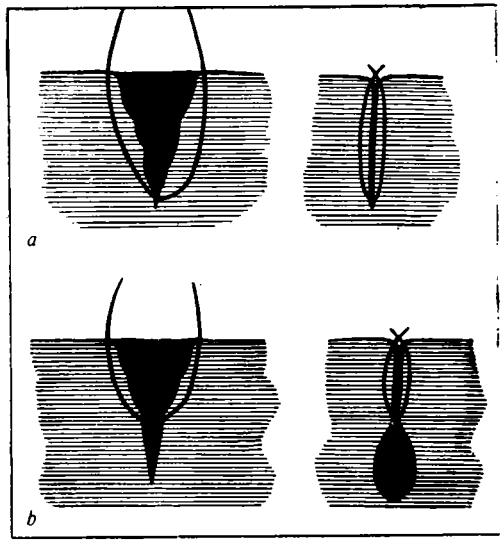

Fig. 285. Placing suture: *a* — correct; *b* — incorrect

Fig. 286. Repair of second degree perineal laceration

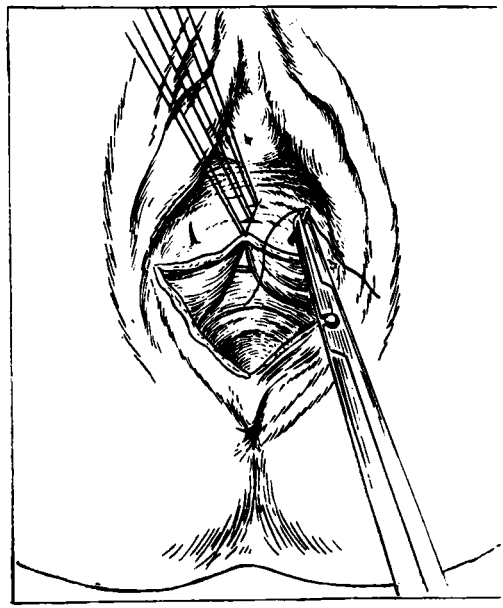

opium tincture should be given to the puerpera twice a day during the course of six days in order to keep away stools. At about the sixth post-delivery day castor oil may be given or a mineral oil enema may be administered.

The patient should be placed on a low residue diet: sweat tea, broth, and other easily assimilable food.

Silk thread should be removed in 5 or 6 days. The patient is allowed to leave her bed on the next day after removal of the sutures.

Lacerations in the region of the clitoris and the lips are often attended with marked bleeding. The laceration of the cavernous body may cause a considerable loss of blood. All lacerations should be repaired. When the clitoral area is repaired, a metal catheter should be inserted into the urethra to preclude its involvement in the suture.

Lacerations of the vagina. Insufficient distensibility of the vaginal walls, infantilism. operative parturition, delivery by extended vertex, large foetal head, etc. are among the causes of vaginal lacerations. The lower third of the vagina is commonly lacerated (along with laceration of the perineum).

Lacerations of the vagina are usually revealed by specular inspection and sutured by catgut. Lacerations of the lower third of the vagina may be repaired with separation of its walls by the fingers of the left hand (Fig. 287).

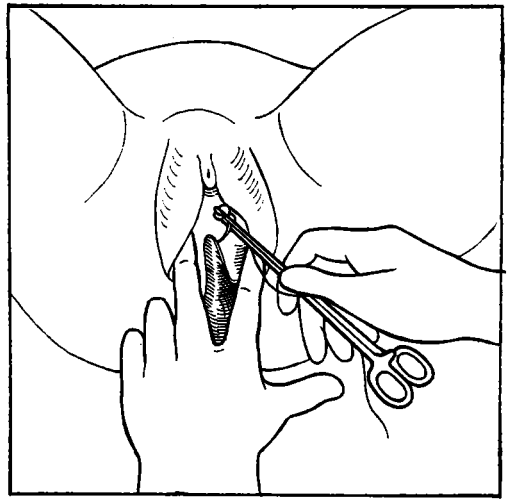

Fig. 287. Repair of lacerated vaginal wall

Haematoma of the Vulva and the Vagina

Blood vessels may rupture during labour and delivery and the subcutaneous connective tissue of the external genitalia or the vaginal submucosa will be effused with the blood. The skin and the mucosa overlying thus formed haematoma becomes red-blue and if much blood is accumulated in the tumour, the tissues becomes strained and painful.

Treatment of small haematomas is expectant. An ice bag is first placed on the affected area but later a careful treatment with warmth should be given. If the haematoma swells rapidly the skin should be incised, the haematoma emptied, and the broken vessel tied up. The incised site should then be repaired.

Rupture of the Cervix

The uterine cervix is effaced during labour and the margins of its os are strongly thinned. Superficial lacerations of the cervical os often do not cause marked bleeding and usually remain unidentified.

But the uterine cervix may also rupture which occurs especially often in pathological labour. The rupture is attended with considerable bleeding and

other unfavourable sequelae. The cervix ruptures on its side, especially the left one (Fig. 288). The rupture may extend to the vaginal fornix, pass onto it, and reach the parametrial tissues. Three degrees of the cervical rupture are distinguished: in the first degree the cervix ruptures to a length not over 2 cm; in the second degree this exceeds 2 cm but does not reach the fornix by 1 cm; in the third degree the ruptured area reaches the fornix and passes onto it (onto the upper part of the vagina).

Blood vessels are injured in the deep rupture of the cervix to cause bleeding which is often profuse and endangers the mother's life. The bleeding is normally external; if the rupture is deep the blood partly accumulates in the parametrial tissues to form a haematoma.

Bleeding usually develops after delivery of the foetus, but it is difficult to locate the source of bleeding until the placenta is delivered. As soon as the placenta has been expelled it is easy to differentiate between bleeding from the lacerated cervix and the placental site. The rupture of the cervix is characterized by persistent bleeding from a contracted firm uterus. In order to establish a definite diagnosis, the cervix should be inspected by specula. The margins of the cervical os are held by the forceps and inspected step-bystep.

Spontaneous and *traumatic* (*surgical*) ruptures are differentiated. A spontaneous rupture is favoured by rigidity of the cervix, in 'elderly' primipara in particular, excessive distension of the cervical os margins (large foetus, extended vertex), precipitate labour, prolonged compression of the cervix in contracted pelvis with violation of normal transport of the nutrients to the tissues.

A traumatic rupture of the cervix develops in operative parturition (forceps delivery, podalic version, extraction of the foetus, destructive operations on the foetus, etc.). The rupture of the cervix is dangerous not only because of bleeding. Unrepaired lacerations or ruptures get infected and a puerperal ulcer is formed in an open rent, which is the source of further spreading of the puerperal infection. As the unrepaired lacerations heal, scar tissue is formed which may become the cause of cervical eversion (ectropion). The eversion later causes chronic inflammation of the mucosa in the endocervical canal and erosion of the uterine cervix.

Treatment. The lacerated or ruptured cervix should be repaired by suturing. The sutures should be placed immediately after inspection of the cervix and discovery of the lesions. The cervix should be pulled by the forceps toward the introitus and moved aside (in the direction opposite to the affected side). Suturing should be begun from the upper angle of the rupture (the first suture should be placed slightly above the rupture) to the margins of the cervical os; the mucosa of the cervix should not be involved in the suture (Fig. 289). If the upper edge of the laceration is difficult to identify, the first suture should be applied slightly below, and the ends of the ligature should be pulled down; the upper angle of the wound will thus be revealed and become accessible for suturing. Catgut should be used to correct cervical lacerations and ruptures. The ends of the ligatures should be cut off.

Rupture of the Uterus

The disruption of integrity of the uterine walls is known as the rupture of the uterus. If all layers of the uterus

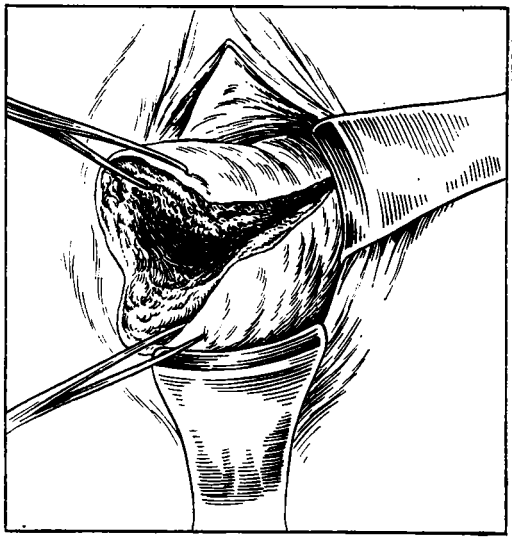

Fig. 288. Rupture of the cervix

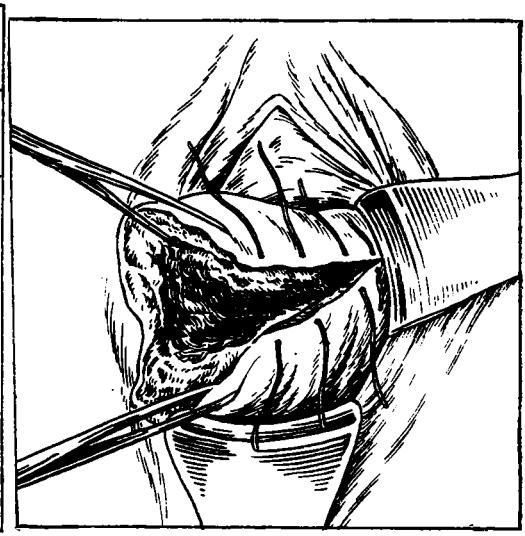

Fig. 289. Repair of ruptured cervix

(the endometrium, the myometrium, and the peritoneum) break, the rupture is *complete* (Fig. 290). The cavity of a completely ruptured uterus opens into the abdominal cavity. If the endometrium and the myometrium are only involved, the rupture is *incomplete* (Fig. 291). A complete (penetrating) rupture of the uterus occurs more frequently than incomplete rupture.

A comparatively thin lower uterine segment usually ruptures, but the upper segment and even the fundus can rupture as well. The rupture may occur along the line of the cervix attachment to the vaginal fornices; this is actually the separation of the uterus from the vaginal fornices.

Spontaneous and *traumatic* ruptures of the uterus are distinguished. A spontaneous rupture arises without any extraneous cause, while a traumatic rupture is mainly due to inappropriate operative intervention.

The rupture of the uterus is *one of the most dangerous complications of labour.* Even with modern obstetrical knowledge the rupture of the uterus

Fig. 290. Complete rupture of the uterus

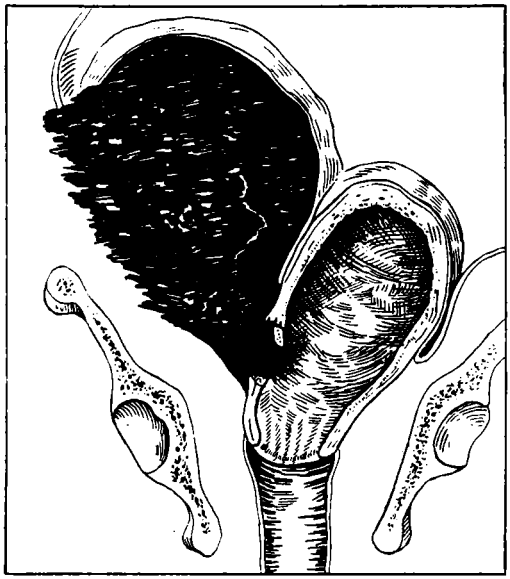

Fig. 291. Partial rupture of the uterus. Formation of infraperitoneal haematoma

not infrequently results in death of the mother and of the intrauterine foetus. The danger depends on acute loss of blood and shock. Blood is lost from the vessels that break together with the uterine wall. The larger the disrupted vessels, the stronger the haemorrhage. Another source of bleeding are the vessels of the placental attachment site. The placenta usually separates in the rupture of the uterus and the vessels of the uterine wall at the site of placental separation begin bleeding. The haemorrhage that attends the rupture of the uterus may be very profuse.

The picture of acute anaemia is aggravated by shock which usually occurs in the rupture of the uterus, complete rupture in particular. The shock develops against the background of strong irritation of the nerve elements of the ruptured uterus (especially of its peritoneal coat). The foetus is often extruded from the ruptured uterus into the abdominal cavity where it acts on the other abdominal organs to add to the danger of developing shock. The foetus would usually very rapidly die because of the placental separation.

The uterus may rupture due to a variety of causes. In the past century (1875) Bandl produced a mechanical theory of uterine rupture. In his opinion (which was supported by many other obstetricians) the rupture occurred due to disproportion between the presenting part and the maternal pelvis. This would be usually explained by contracted pelvis, malpresentation (brow, posterior face presentation), a pathological asynclitism, large (gigantic) foetus, hydrocephaly, or transverse and oblique presentations of the foetus.

Violent uterine contractions develop in obstructed labour; the upper uterine segment contracts even more intensely, and the foetus is propelled gradually toward the lower uterine segment where the walls are thinned by distension. The contraction ring (at the junction of the lower and the upper uterine segments) rises to higher levels to reach the navel (the ring may also be oblique). As the contractions continue, the lower uterine segment becomes overdistended and ruptures.

Early in this century (1911) Ya. F Verbov developed another theory, according to which an intact uterus never ruptures and the rupture may only develop in the presence of pathological changes in the uterine wall which are responsible for the inadequacy of the myometrium. The changes that predispose to the rupture of the uterus are scars resulting from previous caesarean section or other operations on the uterus (enucleation of a myomatous node, etc.), injuries associated with previous abortions, degenerative and

inflammatory processes in past history, infantilism, and other abnormalities of the reproductive organs responsible for inadequacy of the myometrium.

According to modern views, the rupture of the uterus may result from both pathological changes in the uterine wall and mechanical factors. The uterus is more likely to rupture in cases with combination of these defects, i.e. in simultaneous action of several pathological factors (pathologies in the uterus concurrent with obstructed labour).

The uterus usually ruptures in multiparas and very seldom in young primiparas.

The rupture usually occurs during the expulsive stage of labour when obstacles to the progress of the foetus through the birth canal are encountered with. In the presence of pathological changes in the uterine wall (scar tissue, inflammatory and degenerative processes), the uterus may rupture during the dilation stage or even at the very beginning of labour. Cases of uterine rupture during pregnancy are also known. They occur due to pathological changes in the uterine wall.

The rupture of the uterus is usually preceded by clinical signs characteristic of threatened or inevitable rupture. The clinical picture of a threatened rupture is very specific in obstructed labour (contracted pelvis, malpresentation of the foetus, etc.) and less distinct in pathological changes in the uterine wall (scar tissue, etc.). The clinical picture of a threatened rupture associated with the presence of mechanical obstacles to the expulsion of the foetus is as follows:

1. Labour is violent; the contractions become convulsive in character.
2. The lower uterine segment is overdistended, thinned, and painful to palpation.
3. The contraction ring stands high (to reach the navel). Its position is oblique.
4. The round ligaments of the uterus are very strained and painful.
5. The margins of the cervical os become oedematous (due to compression). The oedema extends to the vagina and the perineum.
6. Urination becomes difficult due to compression of the bladder and the urethra between the bony pelvis and the foetal head.
7. Traces of blood appear in the vaginal discharge to indicate the beginning injury of tissues.
8. The parturient is excited, restless (she cries, tosses in the bed, grasps the abdomen) and complains of strong pain.

The clinical picture of an impending rupture due to changes in the uterine wall differs in that the precipitate labour is absent: the contractions are frequent and painful but not very forceful. Other symptoms, such as overdistension and tenderness of the lower uterine segment, oedematous cervix, vagina and external genitalia, disordered urination, etc., are also present but are less distinct than in a threatened rupture due to mechanical causes.

If appropriate medical aid is not given, the uterus will inevitably rupture.

The rupture is characterized by the following symptoms:

1. An extremely severe and acute pain in the abdomen is felt by the woman at the moment of rupture.
2. Uterine contractions discontinue immediately following the rupture.
3. The condition of the patient is sharply aggravated due to increasing anaemia and shock. The skin and the visible mucosa become pallid, the face becomes pointed, the pulse is accele-

rated and small, the arterial pressure drops. Nausea and vomiting often occur.

4. When the uterus disrupts, part or the whole foetus is extruded into the abdominal cavity. Separate members and parts of the foetus become now directly palpable through the abdominal wall; the presenting part, which was previously engaged, moves upward and becomes movable. The contracted uterine body can be palpated by side of the foetus. The foetal heart tones are not heard.

5. External bleeding is usually not pronounced and sometimes even insignificant. The blood fills the abdominal cavity (a haematoma of the pelvic connective tissue develops in incomplete rupture of the uterus).

In the presence of pathological changes in the uterine wall, the rupture may occur because of gradual separation of the tissues. Acute and sudden pain may therefore be absent and contractions do not stop abruptly but lessen gradually. All other signs of the uterus rupture are obvious.

Prophylaxis of the uterine rupture consists in adequate organization of obstetrical aid. Thorough observation of all pregnant women is very important in this respect. All women in whom the rupture of the uterus is likely to occur should be given special care. The factors predisposing to the uterine rupture are contracted pelvis, malpresentation of the foetus, post-term pregnancy (large foetus), flaccid abdominal wall and uterus in multiparas, unfavourable obstetrical anamnesis (pathological previous labour, complicated abortions, puerperal and post-abortion inflammatory diseases), previous caesarean section and other operations on the uterus.

All women in whom the predisposing factors have been revealed should be hospitalized two or three weeks prior to anticipated labour. The labour should be conducted in the presence of a physician.

The parturient should be observed thoroughly during labour so that the signs of a threatened rupture be not overlooked.

Treatment of impending rupture or disrupted uterus. When signs of threatened rupture develop the uterine contractions should be discontinued or lessened, or an abdominal hysterotomy should be performed on the patient.

Ether should be given to inhale in order to stop or lessen uterine contractions.

An independently working obstetrician should give morphine (1.5 ml of a 1 per cent solution) and warn the physician that signs of threatened uterine rupture develop. The woman should be delivered very carefully with deep anaesthesia. If the foetus is alive and there are no signs of infection, a recourse to a caesarean section should be made. A dead foetus should be dissected and removed by parts. Version of the foetus or application of obstetrical forceps is contraindicated; these operations, or even an attempt to perform them, will inevitably result in the rupture of the uterus.

If the uterus has already ruptured, a caesarean section should be performed immediately. The foetus, the placenta and the blood should be removed from the abdominal cavity. The uterus should then be extirpated. In some cases the uterus is repaired by suturing (in young women, if only little time has passed since the uterus was ruptured, and in the absence of infection). Measures to prevent blood loss and shock should be taken during the operation and immediately after. Blood

transfusion, subcutaneous administration of physiological saline solution, warming up the patient, cardiac preparations should be used to this end.

Fistulae

Urogenital and rectovaginal fistulae may be formed in pathological labour. Urogenital fistulae are abnormal communications between the bladder and the vagina (vesicovaginal fistulae) or between the urethra and the vagina. An abnormal communication between the bladder and the endocervical canal may be formed in rare cases. In these pathological conditions the urine (or only part of it) is emptied into the vagina and is discharged through the pudendal cleft. Faeces enter the vagina in rectovaginal fistulae. The fistulae are grave complications of labour and cause severe distress in women.

The fistulae are formed due to prolonged compression of the soft tissues of the birth canal and the adjacent organs between the pelvic walls and the presenting part (in contracted pelvis, malpresentations, asynclitism, giant foetus, etc.). The compression upsets normal circulation of blood in the tissues with their subsequent necrosis and rejection. When the necrotized tissues are rejected a communication between the vagina and the rectum or the bladder (urethra) is formed and faeces or the urine enter the vagina. This usually occurs on the 5th or 7th day after delivery.

Fistulae may be formed due to injuries of the soft tissues of the reproductive tract and the adjacent organs (the bladder or the rectum) inflicted to the woman by the surgical tools used in obstetric operations (destructive operations on the foetus, forceps delivery, etc.). In these cases fistulae are formed immediately after parturition.

Formation of fistulae may be prevented by appropriate conduct of labour. Retention of the foetal head in one of the pelvic planes for a long time should be prevented (after the loss of the amniotic fluid). If the head is retained in the inlet, midpelvic or outlet plane for over two hours, a vaginal examination should be made to establish the diagnosis and to decide which way of parturition is more favourable in a given case. The condition of the bladder should be constantly observed. If urine is retained, the bladder should be catheterized carefully. Even insignificant traces of blood in the urine indicate a threatened fistula and the labour should then be ended operatively.

The *fistulae should be treated* operatively. Only small fistulae may close spontaneously provided they are managed properly. The treatment then consists in keeping the external genitalia clean, and applying vaseline or other oil, streptocide or sulfidine emulsion to the external genitalia and the vaginal mucosa (to preclude irritation).

When a urogenital fistula is diagnosed, a permanent catheter should be inserted into the urethra (the catheter should systematically be removed and sterilized by boiling). Hexamethylenetetramine should be given per os for prophylactic purposes. If the fistula does not close spontaneously, an operation should be made in 3 or 4 months post partum.

Inversion of the Uterus

The inversion of the uterus is its turning inside out; the mucosa then

Fig. 292. Inversion of the uterus

becomes the outer layer, while the serous coat, the internal (the uterus is turned inside out like a finger of a glove) (Fig. 292). It occurs as follows: the uterine fundus is first impressed into the uterine cavity, the fundus reaches the cervical os, and finally the uterus turns inside out to assume a new position in the vagina (or even outside the pudendal cleft).

The uterus inverts under the following conditions: (a) the cervical os is open; (b) the uterine walls are relaxed (e.g. in hypotony or atony); (c) downward thrust on the uterus (e.g. during extrusion of the placenta) or traction, for example by the cord. The inversion of the uterus is favoured by: (1) a combination of relaxation of the uterine wall and extrusion of the placenta by the Credé-Lazarevich manoeuvre without preliminary massage of the uterine bottom; (2) ill devised traction by the umbilical cord with insufficient contraction of the uterus and wide open cervix.

Inversion of the uterus after delivery is usually attended with grave symptoms: acute pain in the abdomen and shock. The skin and the mucosa become pallid, the pulse accelerates, the arterial pressure drops; nausea, vomiting and syncope develop. A bright-red inverted uterus shows from the pudendal cleft. Sometimes the uterus is inverted together with the non-separated placenta. A funnel-shaped depression is formed in the lower abdomen. The inversion of the uterus may become the cause of woman's death.

Treatment. The uterus should be carefully corrected on a heavily anaesthetized patient. The placenta, if any, should be separated from the uterus before restoring its position. The vagina should then be packed with a strip of sterile gauze. Measures to prevent shock and infection should be taken.

Separation of the Symphysis Pubis

During pregnancy the pelvic junctions and the ligaments become hydrous from saturation with serous fluid. This especially holds true for the symphysis pubis. Pelvic junctions may soften considerably in some pregnants. A heavy thrust of the foetal head on the bony ring of the pelvis during labour may cause separation of the symphysis pubis. This is more likely to occur in women with contracted pelvis, giant foetus, and in operative parturition. Sometimes the separation of the symphysis pubis is attended with bleeding and injury of the urethra, the bladder or the clitoris.

The sacroiliac joint may also be

affected in complicated (especially operative) labour and delivery.

If the symphysis pubis separates, the woman complains of pain in the region of the symphysis, the pain being especially annoying on locomotion. The pain intensifies when the legs flexed on the abdomen are abducted. A depression can be palpated between the separated ends of the pubic bones. If necessary, the diagnosis may be confirmed by X-ray examination.

Treatment. Bed-rest and tight bandaging of the pelvis are recommended. Bed rest is prescribed for three or five weeks (sometimes for longer time). The walk in some women is affected (waddling gait), but this defect is usually corrected in a lapse of time.

Chapter Twenty-seven

DISEASES OF THE PUERPERIUM

Causes of Puerperal Infection

Puerperal sepsis develops due to penetration of pathogenic microbes into the reproductive tract of the woman during the process of childbirth or puerperium. Staphylococci and streptococci, and less frequently enterococci and *Clostridium bacteria* are the most common causative agents of puerperal sepsis. The infection would be usually caused by one species (monomicrobial infection) and sometimes by different species of microbial organisms (polymicrobial infection).

Microbes are permanently present in man (especially on the skin, exposed mucosa, etc.) but they do not cause diseases unless conditions for their multiplication are ensured. Pathology develops when microbes penetrate the human body through an open wound. The surface of the uterus after separation of the placenta, lacerations, fissures and erosions on the uterine cervix, the vagina and the perineum that occur even in normal labour and delivery become the portal of entry of pathogenic microbes in a puerpera. If labour and delivery are pathological (especially operative delivery), the injuries of the reproductive tract are more serious and the risk of septic infection therefore greatly increases.

The causative agents may infect the wound from outside (exogenic infection) or they may invade the woman prior to labour (endogenic infection). The sources of exogenic infection are non-sterile hands, tools, linen and other objects that come in contact with the reproductive tract; droplet infection is also very dangerous. In endogenic infection the microbes infect the injured tissues from the vagina, external genitalia, and less frequently through metastatic pathways from remote foci of infection (e.g. from the fauces).

As microbes get onto the wounded tissue they do not always cause sepsis. The fate of the infecting microbes depends on the immune response of the body, i.e. its protective forces.

If the resistance of the body is sufficiently high, the septic infection does not develop, and vice versa the microbes cause septic diseases if resistance of the body decreases. It has been established that the weaker the body resistance to infection, the more grave the septic infection.

Puerperal sepsis thus develops as a result of the interaction of microbes and the human body, the probability of an infectious disease and its gravity largely depending on the health of the puerpera.

Premature loss of the amniotic fluid, prolonged labour, blood loss in labour, operative delivery, lacerations and other injuries of the soft tissues of the reproductive tract, general asthenia and decreased immune response of the woman associated with diseases, intox-

ications, or malnutrition are the factors that predispose to the development of puerperal sepsis.

The diseases begin with the inflammatory reaction at the site of the microbial entrance. The primary foci of puerperal infection are the inner surface of the uterus, lacerations and other injuries of the cervix, vagina, and the perineum (puerperal metroendometritis, puerperal ulcers).

If the immune response and treatment are adequate, the infected surfaces soon heal and the disease is arrested. If the virulence of the microbes is high and the body resistance low, the infection extends beyond the confines of the primary focus. The microbes may also spread through the lymphatics (lymphogenic pathway), the blood vessels (haematogenic pathway) or through the uterine tubes (canalicular pathway). The microbes may spread through the lymph and blood vessels simultaneously.

The propagating microbes affect deep structures of the myometrium, the parametrial tissues, the pelvic peritoneum, the veins of the uterus, the pelvis and the femur. If the immune response is low (or the virulence of the microbes is high), the microbes spread over the entire body to cause general sepsis.

Classification of Puerperal Infections

The classification of puerperal sepsis developed by S. V. Sazonov and A. V. Bartels accounts for various forms of puerperal diseases which are regarded as separate stages of a single infectious process, sepsis.

The *first stage*: the septic infection does not extend beyond the limits of the wound (metroendometritis, lacerations and other injuries of the cervix, vagina and perineum).

The *second stage*: the infection spreads beyond the primary focus but is still localized (metritis, metrothrombophlebitis, parametritis, thrombophlebitis of the pelvic veins and a limited thrombophlebitis of the femoral vein, salpingo-oophoritis, pelveoperitonitis).

The *third stage*: diffuse peritonitis, progressing thrombophlebitis.

The *fourth stage*: generalized infection (general sepsis, septicaemia, septicopyaemia).

The clinical picture of the various diseases identified as the different stages of sepsis is different. The diseases differ by the degree of gravity and prognosis. But regardless of the substantial differences in the clinical picture of septic diseases, the following common features may be noted.

1. Pyrexia. If the disease is mild (metroendometritis) the elevation of the body temperature is only slight and transient. If the affection is grave (septicaemia) high temperature persists.

2. Accelerated pulse. The acceleration of the pulse agrees with the rise of the body temperature in localized diseases of moderate gravity. In general sepsis a discrepancy between the pulse rate (100 per min and over) and temperature develops. The accelerated pulse and its disagreement with temperature are quite characteristic of grave puerperal sepsis.

3. Fever. This is often preceded by a chill and is characteristic of septicaemia and septicopyaemia. Fever may sometimes be strong attended with excessive sweat, and recurring during the course of a day. Some diseases are marked by slight chills only, which subside with termination of the disease. A new fit of a chill indicates appearance of another focus of infection.

Elevated temperature, accelerated pulse and a chill are often mistaken for signs of malaria, influenza, typhus and other diseases; hence faulty treatment. The obstetrician should remember that these signs are typical of puerperal septic diseases. Development of septic infection should therefore be first of all anticipated in a puerpera with elevated temperature, accelerated pulse and a chill.

4. Changes in the nervous system are insignificant in puerperas with metroendometritis and puerperal ulcers; these are actually manifested by indisposition and a mild headache. Grave diseases are marked by worsening of subjective state, headache, insomnia or sleepiness; delirium may develop.

5. As the sepsis progresses, changes in the function of the heart, haemopoietic, digestion and respiration systems, kidneys, etc., develop; the metabolism is upset.

6. The puerpera with grave sepsis loses her weight, the skin becomes pallid and grey, sometimes with a yellowish tint; the skin becomes erupted.

7. Blood changes in septic diseases: the counts of erythrocytes and haemoglobin decrease, while that of leukocytes increases. Leukopenia may develop in a very grave condition. The erythrocyte sedimentation rate accelerates. The graver the disease, the more significant are the changes in the blood. The microbes may be found in the blood of the patient with generalized sepsis. If this is the case, a nutrient medium should be inoculated by a blood sample and the microbes given a detailed study. The blood sample should be taken from the cubital vein with strict observation of the asepsis rules. The sample (5-7 ml) should be placed in a test tube containing a sterile nutrient medium. The blood should be better sampled during a fit of a chill and then sent to the laboratory.

First Stage Sepsis

Puerperal Ulcers

These are purulent wounds formed at the site of lacerations and fissures on the perineum, the vaginal wall, or the uterine cervix. The wound surface is covered with a coat of pus; the adjacent tissues are hyperaemic and oedematous. The disease usually manifests itself on the 3rd or 4th postpartum day. The temperature elevates, the pulse accelerates, the parturient develops malaise; the headache is not very annoying. The patient usually complains of burning in the external genitalia. The temperature is normalized in 4 or 5 days, the state of the patient improves, the wound clears of purulent coats, and heals gradually by second intention. If conditions are unfavourable, the microbes from the ulcer penetrate the deeper layers of the surrounding tissues and the infection thus spreads.

Treatment. Bed rest, considerate care. Gauze impregnated in synthomycin emulsion should be placed on the perineum. Autohaemotherapy. An ice bag should be placed on the perineum during the first days of the infection. Sulpha drugs are given per os (0.5-1 g, 5 or 6 times a day at a 4-hour intervals); penicillin and streptomycin should be given together.

Metroendometritis

Puerperal metroendometritis is the inflammation of the internal surface of the uterus (the basal layer of the endometrium, remnants of the decidual membrane and the adjacent muscle

fibres). The clinical signs of the disease show on the 3rd or 4th day of the puerperium. The temperature elevates, the pulse accelerates accordingly, the appetite worsens and sleep deranges. The onset of the disease may be marked by a chill.

The uterus is sensitive to palpation, it fails to involute normally (subinvolution), the lochia is turbid, with traces of blood in the pus; the odour is often foul.

The lochia is sometimes retained in the uterus (lochiometra) because of the flexion of the uterus or the obstruction of the endocervical canal by a blood clot or remnants of the membranes.

Lochiometra is attended with pyrexia and worsening of the general condition of the patient. The woman complains of the lower abdominal discomfort resembling labour pains.

Metroendometritis may be mild with only slight elevation of temperature. If circumstances unfavour, metroendometritis becomes the source of spreading septic infection.

Treatment. Bed rest; an ice bag on the lower abdomen; autohaemotherapy; calcium chloride intravenously (10 ml of a 10 per cent solution, at 1 or 2-day intervals) or per os (one tablespoonful of a 10 per cent solution, 3-4 times a day), sulpha drugs (0.5-1 g 5-6 times a day at 4-hour intervals) and penicillin (50 000-100 000 units at 3-4-hour intervals).

Puerperal endometritis may also be of gonorrhoeal aetiology. Gonococci enter the uterus of the patient after delivery and cause metroendometritis. They can also move further into the fallopian tubes and cause inflammation of the tubes, ovaries, and pelvic peritoneum.

Gonorrhoeal metroendometritis develops on the 6-8th day of the puerperium and is marked by the following signs: pyrexia, retarded involution of the uterus and its tenderness, purulent or mucopurulent vaginal discharge. The diagnosis is established microscopically. Gonorrhoeal metroendometritis can successfully be treated with penicillin (50 000-100 000 units at 3-4-hour intervals) and sulpha drugs.

Care of gonorrhoeal patients should rule out possible infection of the infant and other puerperas. The gonorrhoeal patient should be the last to receive attendance; she must use her personal bedpan, and must obligatory wash her hands before nursing the child.

Second Stage Sepsis

Metritis

In contrast to metroendometritis, the deep layers of the myometrium are affected in metritis. The microbes enter through the blood and lymph vessels from the affected endometrium.

The disease is manifested on the 4th or 7th postpartum day and lasts for 3-4 weeks. The onset of the disease is marked by a chill which is followed by the rise of temperature to 39-40 °C (102-104 °F); this is followed by a low-grade fever. The general condition of the patient is impaired, the appetite and sleep deranged; the patient complains of headache. The involution of the uterus is retarded, it is painful to palpation, especially on the sides (by the course of the vessels). The lochia is serosanguineous or seropurulent.

Parametritis

Parametritis is the inflammation of the parametrial tissues. The infection

enters through lacerations in the cervix and the vagina. The process is usually unilateral and less frequently bilateral. In unfavourable conditions the inflammation extends to the entire connective tissue of the small pelvis. Serous exudate is first formed in the affected connective tissue, then fibrin is accumulated and the exudate is condensed. The exudate later resolves or suppurates.

Parametritis begins on the 10th or 12th day of the puerperium; the first signs are a chill and elevation of temperature to 39-40 °C; the pulse is accelerated and lower abdominal pain develops; when the inflammation extends onto the bladder and the rectum, dysfunction of these organs becomes manifest (urinary frequency, painful urination and defaecation; constipation). An infiltrate can be palpated by side of the uterus during vaginal examination. The infiltrate is first soft but later becomes firm. It reaches the lateral pelvic wall to displace the uterus towards the opposite side.

The clinical picture of parametritis is varied. The temperature would usually decrease gradually and the infiltrate resolve. Suppuration attended with a chill, high temperature of the remittent type, and worsening of the patient's condition are less frequent. If the abscess is not opened surgically it may open spontaneously (into the vagina, under or above the inguinal ligament, into the bladder, etc.).

Salpingo-oophoritis (Adnexitis)

Puerperal inflammation of the adnexa (appendages) of the uterus is associated with septic or gonorrhoeal infection. The disease begins on the 10th or 14th day of the puerperium. The symptoms are as follows: elevated temperature, worsening of the general condition and appetite, strong lower abdominal pains, urinary dysfunction, painful defaecation, and constipation. During the first days of the disease, the abdomen is tense, sharply painful to palpation. The Shchetkin-Blumberg symptom may be positive.

Bimanual examination reveals painful enlarged appendages whose mobility is limited due to commissures that are formed between the adnexa and the adjacent organs. The course of the disease varies: the patient may rapidly recover, or the process may become chronic, or else abscesses may be formed inside the tubes or ovaries.

Pelvioperitonitis

Pelvioperitonitis is the inflammation of pelvic peritoneum. Puerperal pelvioperitonitis arises due to septic or gonorrhoeal infection. A serofibrous exudate is formed due to inflammation of the pelvic peritoneum, which may then suppurate. The fibrous character of the exudate favours the formation of commissures between the organs of the small pelvis, the intestine and the omentum. This results in a conglomerate in which the uterus and the other organs are difficult to identify.

The disease begins on the 15th or 25th day post partum. The onset is marked by a chill, high temperature (39-40 °C), and sharp pain in the lower abdomen. The first days of the disease are marked by nausea, vomiting, tense abdominal muscles, and a positive Shchetkin-Blumberg symptom. The general condition and sleep are deranged, the pulse accelerated, the tongue is dry and coated.

If proper therapy is given these manifestations soon subside, the infiltrate in the small pelvis is localized and resolved gradually. Commissures be-

tween the organs of the small pelvis remain after the patient's recovery. The exudate often suppurates in pelvioperitonitis; if the abscess is not opened surgically it may open spontaneously (into the vagina, the bladder, etc.); the inflammatory process may extend beyond the primary focus to give diffuse peritonitis.

Treatment of metritis, parametritis, salpingo-oophoritis and pelvioperitonitis is based on the following therapeutic principles.

1. Bed rest. It favours localization of the inflammatory focus and its eradication. The upper part of the body of the pelvioperitonitis patient should be elevated (by raising the head-end of the bed). Vaginal examination is only allowed for special indications. Emotional rest is also needed.

2. Thorough care is very important (care of the skin, linen, airing of the room, etc.) along with adequate nutrition (tasty and readily assimilable food, vitamins). In general, the care and nutrition should comply with the special regulations for treating patients with septic diseases.

3. An ice bag should be placed on the lower abdomen of patients with an acute stage of the diseases; analgetic suppositories are prescribed.

4. Anti-inflammatory therapy is given: calcium chloride intravenously (10 ml of a 10 per cent solution at 1-2-day intervals) or per os (a tablespoonful of a 10 per cent solution three or four times a day), amidopyrine (a tablespoonful of a 2 per cent solution 3 or 4 times a day).

5. Penicillin with streptomycin and other antibiotics should be given. Penicillin should be injected with procaine hydrochloride (0.25-0.5 per cent solution). The dose depends on the clinical picture and sensitivity of the causative agent. As a rule, 600 000-800 000 units are given per day. Sulpha drugs are also effective and given during the first two days, 1 g at 4-hour intervals, and during the next 2 or 4 days, 0.5 g at 4 or 6-hour intervals.

6. Glucose is given intravenously. Autohaemotherapy or repeated blood transfusion are recommended in subacute form of the disease.

7. If the infiltrate suppurates in the parametrial tissues and the pelvic peritoneum, surgical treatment is required. The abscess is opened through the posterior fornix of the vagina (colpotomy) or through the abdominal wall (in parametritis).

Thrombophlebitis (Thromboembolic disease)

Puerperal thrombophlebitis is the inflammation of the vein wall with subsequent formation of a thrombus that closes the lumen of the vein to affect circulation. Thrombophlebitis of the uterine, pelvic and femoral veins occurs. Thrombophlebitis of the uterine veins (metrothrombophlebitis) develops from metroendometritis. The symptoms in general resemble those of metritis. Retarded involution of the uterus and lengthy sanguineous discharge are characteristic. In unfavourable cases the process is extended onto the pelvic veins which can be palpated during vaginal examination as sinuous and painful streaks. In further development of the process the iliac veins are occluded followed by thrombosis of the femoral veins. A grave puerperal disease, thrombophlebitis of the femoral veins, develops.

Thrombosis of the femoral veins manifests clinically on the second or third postpartum week. The onset of the disease is marked by a chill and high

temperature, the pulse is accelerated and the patient complains of pain in the leg. Headache, insomnia and other disorders are not infrequent.

The local manifestations of the femoral thrombophlebitis are as follows: levelling of the inguinal region, infiltration and painfulness along the course of the vein (the anteromedian surface of the thigh, below the inguinal ligament), and oedema of the leg. The oedema is sometimes very large. High temperature persists for two or three weeks, and oedema of the leg, one or two months. During the reconvalescence the patient feels 'creepy' over the leg.

Treatment of postpartum thrombophlebitis complies with the general rules adopted for treatment of septicaemia and septicopyaemia with observation of some special requirements. (Thrombophlebitis is now also treated surgically.)

1. Absolute bed rest. It prevents possible embolism (obstruction of the vessel in a vitally important organ by a blood clot). The leg affected by femoral thrombophlebitis should be kept in the elevated position by placing it over the cushion or a splint.
2. Injections and instillations into the affected leg are not allowed.
3. An ice bag should be placed on the lower abdomen.
4. Leeches should be applied to reduce inflammation and decrease blood coagulability. Leeches should be applied along the affected vein (the skin should preliminarily be washed, wiped dry and coated with a sugar solution). From 5 to 7 leeches should be placed. Each draws about 10-12 ml of blood and falls off spontaneously. Anticoagulants should however be preferred.
5. Vishnevsky's ointment should be applied to the entire affected leg when the process begins subsiding. The ointment should be renewed in 7 or 8 days.
6. Medicamentous treatment should be the same as in general septic diseases. Streptomycin or biomycin should be preferred among antibiotics.
7. The patient is allowed to move actively in three weeks after the temperature has normalized and the erythrocyte sedimentation rate drops to 30 mm per hour and below.

Third Stage Sepsis

Acute diffuse peritonitis and progressing thrombophlebitis are the third stage septic diseases.

Acute diffuse peritonitis

Acute diffuse peritonitis manifests on the 3-8th postpartum day. The disease is characterized by a grave clinical picture: nausea, vomiting, inflation of the abdomen (the Shchetkin-Blumberg symptom may be absent), increased temperature (if the condition is very grave, the temperature does not rise). the pulse is frequent and small, the arterial pressure is decreased, the tongue is dry, face features are pointed. and consciousness is lost in grave cases.

Progressing Thrombophlebitis

This form of thromboembolic disease is characterized by that the inflammation of the veins and the formation of the thrombus are not limited by the primary locus but ascend along the course of the vein. The thrombus undergoes purulent softening and the particles of the infected thrombus are carried by the blood circulation throughout the entire body to precipitate in

other organs and tissues and form new foci of septic infection.

In some cases the purulent foci become encased in cysts and the infection does not spread over the rest of the body.

Diffuse peritonitis and ascending thromboembolic disease should be treated in the same way as the generalized septic infection.

Fourth Stage (Generalized) Sepsis

Septicaemia and septicopyaemia are classified as the fourth (generalized) stage of sepsis.

Septicaemia

This is a grave systemic sepsis characterized by propagation of the microbes through the entire body by the circulating blood; the microbial toxins poison the body. Marked dystrophic signs develop in the heart, vessels, the liver, kidneys and other organs.

The disease develops on the 2nd or the 3rd postpartum day. The onset is marked by a chill, elevation of temperature to 40-41 °C, and a sudden worsening of the general condition of the patient. The woman becomes apathic and sleepy; she complains of headache; abnormal excitement and delirium often develop. The pulse is small and accelerated to 120-130 beats per min; the tongue is dry and coated, the skin is also dry, with a greyish or yellowish tint, frequently affected by eruption. Diarrhoea is frequent. The extremities are often cyanotic due to cardiac dysfunction. Inoculation of nutrient medium with a blood sample may be used to reveal the agent responsible for the development of septicaemia. The disease is often fatal even with modern treatment.

Septicopyaemia

From the foci of septic infection the microbes are carried to various organs and tissues of the body to form new foci of infection there, which usually become purulent.

The main focus of spreading infection is often purulent thrombophlebitis. Particles of putrid thrombi are carried through the body by the circulating blood to form septic deposits in the lungs, the heart, subcutaneous connective tissue (abscesses, phlegmons) and in other organs and tissues.

The clinical picture of septicopyaemia and septicaemia has much in common (grave condition, high temperature, chill, accelerated pulse, etc.). But there are special features that are due to metastasizing into various organs in septicopyaemia. Thus, the signs characteristic of generalized sepsis are supplemented with the affections of various organs, e.g. the heart, the lungs, etc. The back development of a metastatic focus of infection is attended with an improvement of the general condition of the patient, normalization of temperature, etc.

If a new metastatic focus develops, the symptoms reappear: the temperature rises, the general state worsens, additional symptoms (depending on the affection of a new organ) develop.

Treatment of septicaemia and septicopyaemia. The treatment is mainly aimed at improvement of the general resistance of the patient and at eradication of the cause of the disease (attenuation of the virulence of the causative agent and discontinuation of its growth). The treatment consists in the following:

1. Thorough care of the patient (which is very important in many respects, since it increases the resistance of the body to the infection and is thus responsible for reconvalescence).

The room should regularly be aired and kept clean; the number of patients accommodated in the room should by no means exceed the admissible norm. Underwear and linen should be renewed as frequently as possible, especially so if the patient perspires intensely. Napkins overlying the bed-sheets should be dry and well pressed (without pleats). The mouth cavity and the skin of the patient require special care; the patient should gargle her mouth and clean it in the morning, during the day-time after taking food, and before night rest.

The mouth should be wiped on the outside with cotton wool soaked in a weak solution of boric acid or a mixture of borax and glycerol (15 g each). The skin should be wiped every day with a weak solution of alcohol, eau de Cologne or aromatic vinegar.

In order to prevent bedsores that are easily formed in septic infection, the skin over the sacrum, spine and shoulder blades should be treated every day with camphor alcohol (in addition to the routine treatment of the entire skin). An inflated rubber ring should be placed under the pelvic region.

The external genitalia should be washed at least two times a day.

2. Adequate nutrition is another requisite condition to increase the body resistance to the infection. The food should be calorific, tasty, varied, and easily assimilable. Sugar, fats (as cream, butter), proteins (as steam-treated meat cakes, boiled fish, chicken, eggs, curds) should be given. If the kidneys are not affected. caviar, herrings and other appetizers should be given in small quantities. Fruits and juices are useful as well. Liquid (tea, coffee, alkaline mineral water, etc.) should be given in sufficient quantity. Wine can be given in small doses as well.

3. Vitamins (A, C, B, D, and others) improve resistance of the body. Glucose should be administered intravenously (20-40 ml of a 40 per cent solution) or subcutaneously (to 1-2 litres of a 5 per cent solution). In the presence of thrombophlebitis intravenous instillations are not indicated. Small doses of blood may be carefully transfused. Cardiac preparations (mainly camphor), drugs stimulating haemopoiesis and improving digestion should be given regularly.

4. Antibiotics (tetracyclin, biomycin, erythromycin, etc.) should be given.

The following combinations of antibiotics are most effective: (a) penicillin and streptomycin, (b) erythromycin and tetracyclin, (c) oleandomycin and tetracyclin, (d) tetracyclin and sulpha preparations.

The daily dosage is usually as follows: penicillin 800 000 units, tetracyclin 800 000 units, erythromycin 800 000 units, oleandomycin 800 000 units, and streptomycin 1 000 000 units. When given together with tetracyclin, the doses of erythromycin and oleandomycin should be 400 000 units per day. Semisynthetic and other new antibiotics are also recommended.

Sulpha drugs are effective in septic infections, generalized sepsis included. They should be given in large doses (1 g at 4-hour intervals) during the first days of treatment with subsequent reduction of the dose.

Prophylaxis of puerperal sepsis. Prophylaxis is the best means to control puerperal septic infections. This is the main landmark in organization of the entire work of obstetric and gynaecological institutions, and especially ly-

ing-in hospitals. All measures aimed at improvement of health of the pregnant (adequate nutrition, normal way of life, proper hygiene, timely revealing and controlling of all foci of infection, safeguarding the pregnant from infected patients) are effective means to preclude puerperal infection. Aseptic conditions of labour, proper puerperal care, personal hygiene of the medical personnel, isolation of puerperas with fever, etc. are especially important measures. Immunization of the pregnant with the staphylococcal toxoid is also an important prophylactic step.

Prevention of haemorrhage and other complications that decrease the resistance of the woman is important too. Another important preventive step is health education of the pregnant and puerpera.

Puerperal Breast Infections

Mastitis, the inflammation of the breast, sometimes occurs in the puerperium. The agents that cause the inflammatory process are pyogenic microbes, mainly staphylococci (less frequently streptococci) and other organisms. Pyogenic microbes are brought on the breast nipples by contact with infected linen, by air-borne or droplet infection and contaminated hands.

Fissures and minor cracks on the nipples are the portal of entry for infection. The microbes can penetrate the mammary gland through the minutest lesions on the nipple epithelium or the infection may be brought from the other foci with the circulating blood and lymph.

Puerperal mastitis usually begins with a sudden rise of temperature (to 39° and over) which is often attended with a chill. The woman complains of pain in the breast, general indisposition, headache, deranged sleep, worsened appetite. The breast enlarges and a firm tender formation (without distinct boundaries) can be revealed inside the breast by palpation. The skin sometimes reddens over the affected portion of the breast. Axillary lymph nodes often increase in size and become tender.

The inflammation worsens patency of the lactiferous ducts with subsequent congestion of milk. The process may be arrested at this stage and the patient will recover. But in unfavourable cases (decreased resistance of the body, high virulence of the pathogenic microbes, ill devised treatment), the process progresses and the infiltrate suppurates (suppurative mastitis).

The general condition of the patient worsens, she develops a chill, pyrexia becomes remittent. Pain in the breast becomes more intense, the skin over the infiltrate becomes hyperaemic and cyanotic. Suppurative mastitis is often a grave and prolonged disease.

Prophylaxis of puerperal mastitis consists in keeping the breasts clean and in prevention of cracks on the nipples. Proper care of the breasts during pregnancy and nursing is an important preventive measure. Daily washing with cool water, sponge baths and wiping with a rough towel are good prophylactic measures. If crusts (dry colostrum) are formed on the nipples, they should be washed with a 1 per cent solution of boric acid.

During nursing it is necessary to see that the infant takes the nipple together with the areola. It is very important also that the breasts of a lactating and nursing mother be kept clean.

When cracks are detected on the nipple, the infant should be nursed through an adapter. After nursing the

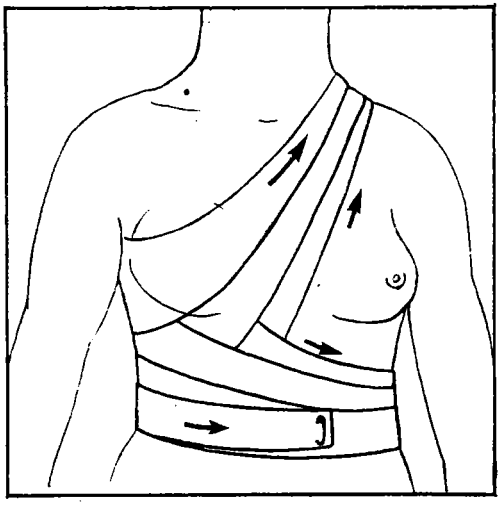

Fig. 293. Bandaging the affected breast in the lifted position

nipple should be treated with a penicillin solution (10 000 units per ml of a physiological saline solution) and the cracks powdered with white streptocide. An alcoholic solution of methylene blue can also be used.

Treatment. An ice bag can be placed on the mammary gland during the early stage of the disease. The affected breast should first be lifted by bandaging as shown in Fig. 293. The treatment may be begun with a warming compress using Vishnevsky ointment or camphor oil. Antibiotics should be given intramuscularly (500 000-800 000 units every day). Sulpha drugs are also effective. As a rule, this therapy is effective. If back development of the infiltrate is delayed, autohaemotherapy should be used. An important measure is emptying the breast. In the absence of suppuration, the nursing should therefore be continued (or a breast pump be used to draw the milk).

Surgical treatment is indicated in suppurative mastitis. If the abscess is not large, it may be drained by a needle puncture with subsequent filling the formed void with penicillin. Otherwise an incision of the breast is required.

Noninfectious Puerperal Complications and Diseases

Urinary and defaecation disorders are frequent complication of the puerperium. These can easily be managed by proper conduct of the puerperium.

Puerperal shock, air embolism, and also puerperal eclampsia and psychosis occur infrequently.

Puerperal shock. This may occur in difficult labour, attended with severe pains and precipitate delivery, or after obstetric operations carried out without anaesthesia, such as extrusion of the placenta by the Credé manoeuvre. Shock develops after delivery of the foetus or the placenta. It may develop without loss of blood, but haemorrhage that weakens the woman is a predisposing factor.

The woman in shock develops paleness of the skin and visible mucosa. vertigo, nausea, vomiting, cold sweat; the pulse becomes thready and the arterial pressure drops. A syncope often develops.

Treatment. Pantopon subcutaneously; the patient should be warmed; her blood transfused; glucose should be given intravenously; cardiac preparations (camphor, caffeine) should also be given.

Air embolism. If air enters an open vein of the uterus after delivery, it can be transported through the vena cava inferior to the heart and the pulmonary artery. The woman's condition becomes very grave (pallid skin, dilated pupils, cardiac and lung dysfunction) with a rapid fatal outcome.

Air embolism is a rare complication of labour. It may develop during obstetrical operations such as version of the foetus, manual separation of the placenta, etc. It may also occur in placenta praevia and uterine atony.

Puerperal psychoses. Previous schizophrenia, manic-depressive disease and other psychic disorders may exacerbate during the puerperium. Sometimes the disease first develops during the puerperium. Puerperal psychoses are however very rare now.

If any signs of developing psychosis appear, the physician should be summoned and the patient given constant observation. She may not be left alone because accidents are possible. The patient should preferably be moved to the psychiatric department.

Chapter Twenty-eight

OBSTETRIC OPERATIONS

Indications and Requisite Conditions for Obstetric Operations

Whether or not a particular pregnant should be delivered by an obstetric operation is decided upon a detailed examination of the pregnant (parturient). All diseases and complications of pregnancy and labour that may necessitate an operative delivery are classified as *indications* for an obstetric operation. Complications that endanger the life of the mother (diseases of the heart, eclampsia, placenta praevia, etc.) or the foetus (asphyxia), as well as abnormalities of the birth canal (contracted pelvis, vaginal stenosis, etc.) and dystocia, etc., are indications for operative delivery.

In addition to the presence of indications for an obstetrical operation, there are other no less important factors which should be considered in deciding whether a given obstetric operation may be performed. These are the circumstances required to permit a given obstetric operation. For example, transverse presentation of the foetus is in itself an indication for an obstetric operation, but the choice of a particular operation (external version, podalic version, caesarean section, embryotomy, etc.) depends on the *conditions* under which the operation may be performed. These conditions are the degree of the cervix dilation, the status of the membranes, the pelvic architecture, the cephalopelvic relationship, etc.

As a rule, all obstetric operations should be performed by a physician. In compliance with the regulations of the Ministry of Health of the USSR (July 29, 1954), an obstetrician is allowed in urgent cases (if the physician is not available or the patient cannot be transported to the lying-in hospital) to perform the following operations without giving general anaesthesia and with observation of all asepsis and antisepsis rules: podalic version (with the intact foetal membranes or if the amniotic fluid has only just escaped and the foetus is movable) in transverse and oblique presentations, traction by the podalic end, manual separation and extraction of the placenta or its parts, repair of perineal lacerations of the first and second degrees.

Preparation for Obstetric Operations

Many obstetric operations bear no delay. Sterile materials (gauze, cotton wool, silk, catgut), drapes, sterile tools (for suturing or application of forceps), blood and physiological saline solution and an apparatus for their transfusion, the substances and apparatus that may be required to give anaesthesia (local or general), cardiac preparations, dis-

infecting and other substances should therefore be kept ready for use in lying-in hospitals. For routine (not urgent) operations the tools should be sterilized immediately before surgery.

Sterilization of materials. Gowns, masks, head caps or kerchieves, drapes, towels, etc. should be counted and placed in a special drum. (A separate drum should be available for sterilization of gauze, tampons, etc.) The drums containing the materials to be sterilized are placed in autoclaves, and *compressed steam* is admitted into the drums for 45-50 minutes. Sterilization of dressing materials by boiling may be admitted in exceptional cases.

Rubber gloves should be sterilized in an autoclave (after powdering with talcum), or boiled for 10-15 minutes. The gloves are then dried with a sterile towel, powdered with sterile talcum, and wrapped in sterile napkins.

Sterilization of suturing materials. Silk, catgut and capron are used for suturing.

Catgut is treated by various techniques. By one of them, catgut is wound round glass plates or boblins (one layer) and kept for two weeks in a glass jar (fitted with a ground-in stopper) containing 10 ml of potassium iodide and 10 ml of iodine solution in 96 per cent ethyl alcohol (1000 ml). In two weeks the catgut is transferred to 96 per cent alcohol where it is kept until required.

Another method of preparing catgut is as follows: catgut threads are wiped with gauze wetted in petrol, rinsed thoroughly in distilled water, dried with sterile material, and placed for 10 days in a bottle containing Lugol's solution consisting of 10 ml of iodine, 20 ml of potassium iodide and 96 per cent ethyl alcohol (1000 ml). The catgut thus treated is then transferred to 96 per cent alcohol and kept ready for use.

Silk should be coiled into small bundles, washed many times in warm water and soap, rinsed thoroughly in distilled water, kept in ether for 12 hours, and then in pure alcohol (also for 12 hours). Then the silk should be boiled in a 1 per cent corrosive sublimate solution for five minutes. The hands are next treated as for an operation. The boiled silk is wound onto sterile glass plates or bobbins and placed in a glass bottle (fitted with a ground-in stopper) containing pure alcohol. Silk and catgut should be tested for sterility in a laboratory (with inoculation of a broth).

Sterilization of tools. Tools should be sterilized by boiling in a 1 per cent sodium hydrocarbonate solution for 15 minutes in a special sterilizer. If the latter is not available, tools can be boiled in a clean pan. Cutting tools (scalpels, scissors) should not be boiled but placed in alcohol for 1-2 hours before an operation. After operation the tools should be washed with a brush in warm water and soap, boiled again in sodium hydrocarbonate solution (except the cutting tools) and wiped thoroughly.

When an abdominal hysterotomy is to be performed the obstetrician should count the tools and this quantity should be checked before closing the abdominal wall after the operation. All linen objects, as well as sterile napkins, should also be counted before and after operation.

Disinfection of hands. Spasokukotsky-Kochergin, Fürbringer, or Ahlfeld methods are used to treat the surgeon hands (see Ch. 7). As soon as the hands have been appropriately treated, the surgeon should put on the sterile mask, overalls, and sterile rubber gloves. Vaginal operations should be performed

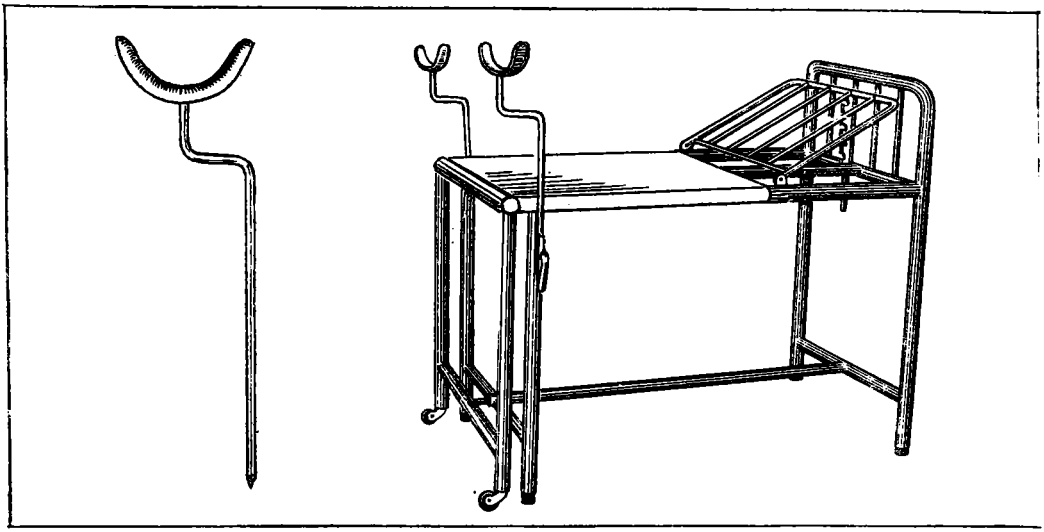

Fig. 294. Collapsed Rakhmanov's bed with leg-holders

without gloves since they worsen the tactile control.

Preparing the patient (pregnant, parturient, puerpera). The bladder should be evacuated by catheterization and the rectum cleansed by an enema (if the operation is not urgent). The pubic and perineal hair is removed by shaving. The external genitalia, the inner surfaces of the thighs, the perineum, the anal region, and the lower abdomen (to the navel) are washed thoroughly with soap and warm water. The washed parts should be dried with sterile materials, and wiped with alcohol and a 5 per cent alcohol iodine solution. The anterior abdominal wall should be washed with alcohol and wiped with

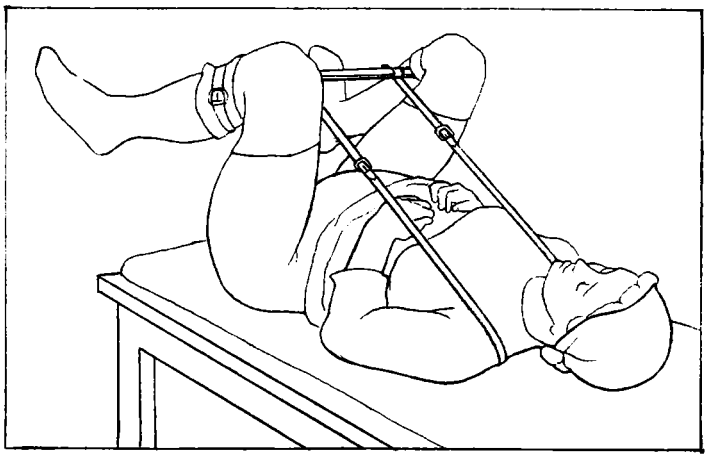

Fig. 295. Otto's leg-holder



Fig. 296. Making a leg-holder from a bed-sheet (first movement)



Fig. 297. The bed-sheet rolled into a leg-holder

a 5 per cent iodine solution two times before an abdominal hysterotomy. The abdominal wall is then covered with a sterile drape provided with a cut.

For a vaginal operation the legs of the patient should be dressed in sterile stockings, and the external genitalia draped with a sterile cloth provided with a cut. A sterile gown suits the purpose as well (the sleeves being used as stockings).

Obstetric operations are carried out

Fig. 298. Using the bed-sheet to hold the legs

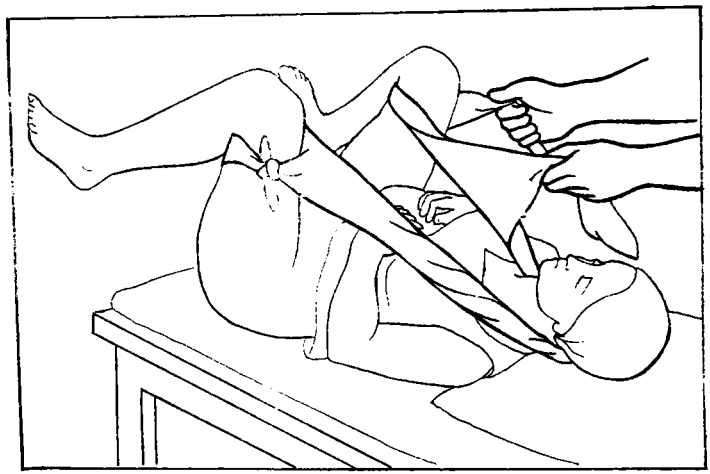

on a table specially designed for abdominal hysterotomy and vaginal operations. A Rakhmanov bed can be used for vaginal operations as well. The tail-end of the bed is then collapsed and leg-holders are adjusted (Fig. 294). The woman's pelvis is placed at the edge of the bed and the abducted legs supported by the leg-holders. An oilcloth should be placed under the pelvis and covered with a sterile drape. A common table can be used in urgent cases. The legs should then be held by the Otto leg-holder (see Fig. 295). A bed-sheet twisted into a band (Figs. 296, 297, and 298) can be used as well, or the parturient's legs may be held by the assistants.

Measures to prevent foetal asphyxia should be taken before some operations. Moreover, all articles that may be required to resuscitate the infant born in asphyxia should be prepared beforehand.

Pain Relief in Obstetric Operations

All obstetric operations should be performed with general (inhaled) or local anaesthesia. Spinal anaesthesia is not recommended in obstetric operations.

General (inhaled) anaesthesia is used in major obstetric operations such as the classical podalic version and extraction of the foetus, caesarean section, destructive operations on the foetus, in manual separation of the placenta or its retained parts. At the present time a caesarean section is performed with an intratracheal anaesthesia with mixture of nitrous oxide, oxygen and ether (or other narcotics). All contraindications should be thoroughly considered before giving general anaesthesia. Ether (or better ether with oxygen) is usually used for the purpose. The patients fall asleep from a small dose of ether. A mixture of nitrous oxide and oxygen is successfully used as well.

Before giving anaesthesia, it is necessary to remove artificial teeth or jaws (if removable). The face of the patient is coated with vaseline, the eyes are covered with a towel, one arm is bandaged by side of the patient, and the other arm is held by the anaesthesiologist who controls the pulse. A mouth dilator, tongue holder, a sterile syringe with injection needles, a camphor and caffeine ampoule, and an oxygen bag should be at hand.

The anaesthesiologist should constantly control the pulse, respiration and the pupil reaction of the patient. When a deep sleep is induced, the pupils are narrow and do not respond to light stimuli, the pulse is full, rhythmic and retarded, the breath is regular, the muscles are relaxed, the reflexes are absent.

A caesarean section, an operation for ectopic pregnancy (without anaemia) may also be performed with local (procaine hydrochloride) anaesthesia.

Pudendal block anaesthesia is used for pain relief at pelvic delivery and for some obstetrical operations. This is induced by a 0.25 per cent procaine hydrochloride solution.

Paracervical block anaesthesia. This is used for curettage of the uterus and vaginal caesarean section (0.25 per cent procaine hydrochloride solution is injected through the lateral vaginal fornices, bordering with the anterior fornix, into the pericervical tissues investing nerve plexus). From 30 to 40 ml of the solution should be injected on each side.

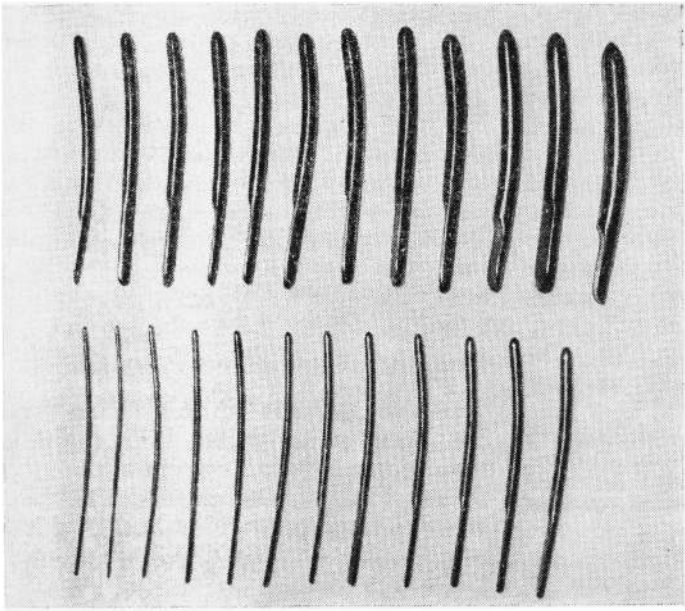

Fig. 299. Hegar's dilators



Fig. 300. Bullet forceps

Operations on the Uterus

Curettage

The curettage of the uterus is used in artificial (therapeutic) abortion, incomplete abortion, abortion in progress, and in the puerperium, mostly in late postpartum haemorrhage associated with retention of the placental remnants.

The tools necessary for curettage are vaginal specula, an elevator, a set of dilators (for therapeutic abortions) (see Fig. 299), bullet forceps (Fig. 300) or Museux's forceps (Fig. 301), a uterine probe (Fig. 302), curettes (Fig. 303), abortion (fenestrated) forceps, a syringe and needles for giving anaesthesia, various forceps, and pincers.

Artificial abortion. An artificial abortion by curettage may be performed till the twelfth week of pregnancy. Curettage at later terms is dangerous because of possible perforation of the uterus.

Technique. The vagina is opened by the specula, the cervix and the vaginal walls are treated with alcohol and iodine; the cervix is grasped by the bullet forceps and the uterus is probed (Fig. 304) to determine its size and position. The cervical os is then dilated by metallic dilators as follows: the smallest dilator (No. 4) is first inserted, then follow thicker dilators (Fig. 305). The dilation of the endocervical canal to admit the dilator No. 12 is usually sufficient for curettage.

After the canal has been dilated sufficiently a curette is passed inside the uterus to separate the conceptus from the uterine wall and remove it (Fig. 306). Parts of the conceptus that show from the endocervical canal are taken by the abortion forceps. A small

curette is then used to check the uterus for complete removal of the conceptus. The bullet forceps is then released and the traces on the cervix treated with iodine. The specula are finally removed from the vagina.

Dilation of the endocervical canal is unnecessary in incomplete abortion and abortion in progress. Curettage is performed immediately after probing.*

If the gestational age exceeds 12 weeks, an *artificial abortion is only performed for special indications.* The indications for termination of pregnancy at late terms are diseases of the pregnant that are aggravated and exacerbated by pregnancy (diseases of the heart, lungs, kidneys, liver, etc.), grave forms of toxaemia, hypertension, and psychoses. Pregnancy is terminated at late terms by (a) vaginal caesarean section (an abdominal hysterotomy is used less frequently), (b) by injecting fluids into the amnion cavity, and (c) by metreurysis.

* A vacuum extractor has come into use in recent times to perform artificial abortion. The conceptus is destroyed and extracted from the uterine cavity by vacuum (without curettage of the endometrium).

Removal of Conceptus Remnants

If the products of conception have not been expelled in their entirety, the remnants may be removed by a finger. This surgical interference may be performed with effacement of the

Fig. 301. Museux's forceps

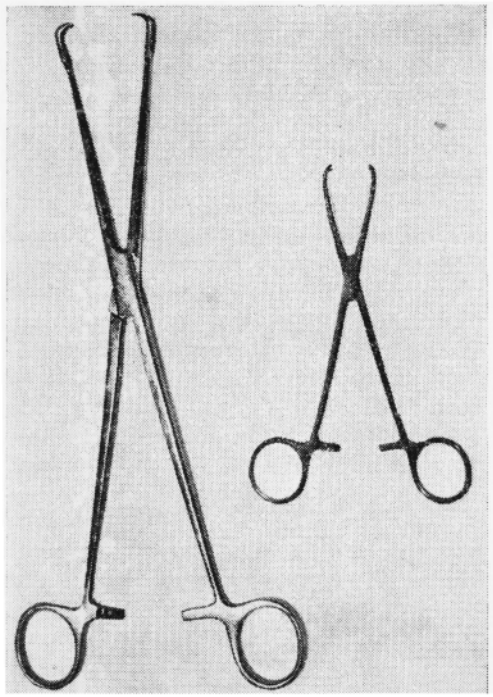

Fig. 302. Uterine probe



Fig. 303. Curettes

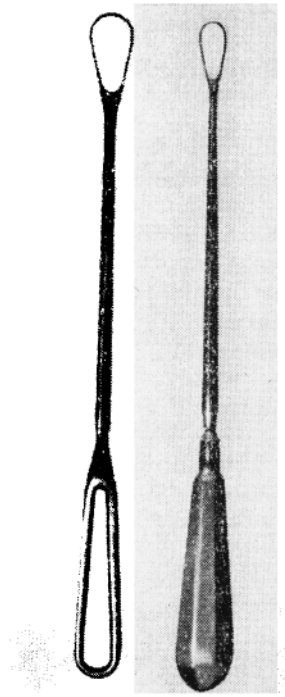

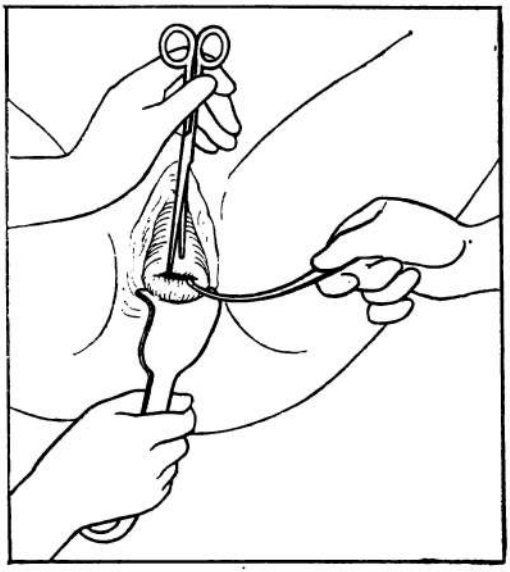

Fig. 304. Probing the uterus

Fig. 305. Dilating the endocervical canal

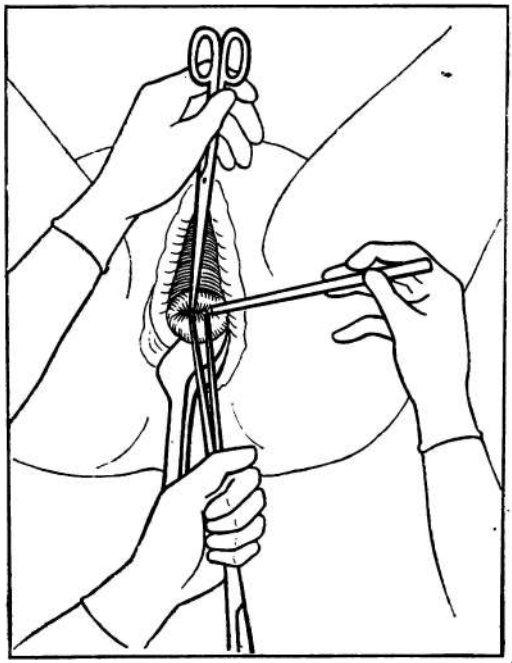

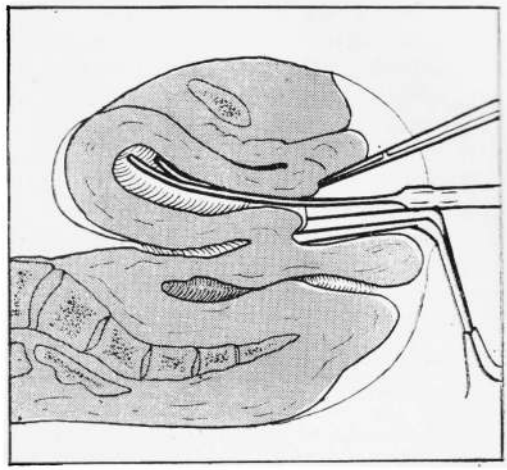

Fig. 306. Curettage of the uterus

cervix (or its considerable shortening) and its dilation sufficient to admit one or two fingers.

Four fingers are introduced into the vagina and one (or two) of them, into

Fig. 307. Removing remnants of the conceptus by a finger

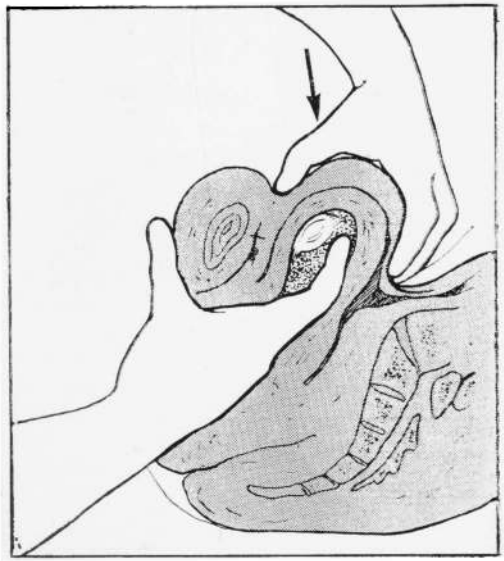

the uterine cavity. The outer hand grasps the uterine bottom through the abdominal wall. The operating finger separates and removes the remnants of the conceptus (Fig. 307) and then inspects thoroughly the uterine cavity. This method is more complicated than the instrumental one and is fraught with a greater risk of infection. Curettage is therefore preferred in most cases.

Operations Preparing the Birth Canal

The endocervical canal is dilated (a) instrumentally (using dilators), (b) by a metreurynter, (c) by constant traction of the foetal head using forceps, (d) by fingers, and (e) by incising the cervix.

Fig. 308. A metreurynter in the uterus

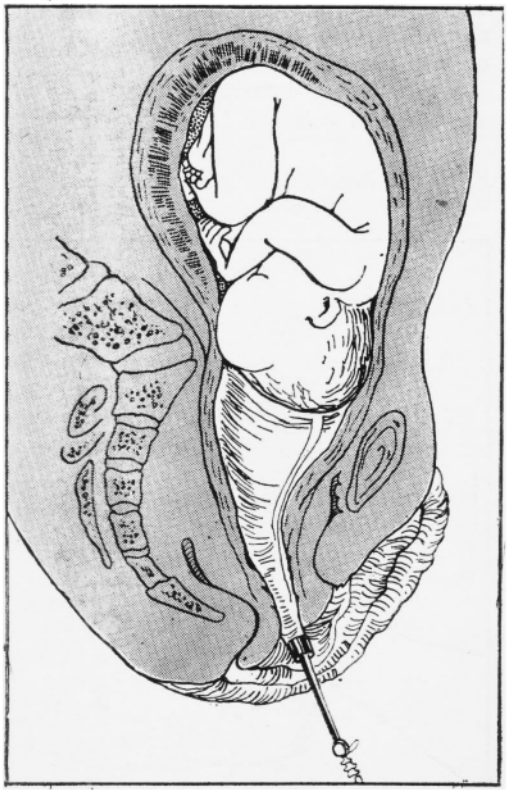

Using Dilators

Metal dilators are used to widen the endocervical canal in artificial abortion. During labour dilators are used before inserting a metreurynter. Dilators Nos. 18 or 19 are used for the purpose.

Metreurysis

Metreurysis is an operation consisting in inserting a rubber bag (Voorhees' bag), known as metreurynter, into the uterine cavity to ensure gradual dilation of the endocervical canal.

The *indications for metreurysis* are: late artificial abortion for medical indications, primary uterine inertia, marginal and lateral placenta praevia, premature discharge of the amniotic fluid in transverse presentation, prolapse of the umbilical cord through a partly dilated cervix (to keep the corrected cord from repeated prolapse).

Requirements to permit metreurysis: the cervix is open to admit two fingers (if the cervix is closed, dilators Nos. 18 and 19 should be used), and the absence of signs of infection.

Tools required: vaginal specula and elevators, bullet forceps (2 or 3), curved forceps (2 or 3), a syringe, 200 ml (1), clamps (2 or 3). Dilators are used if the cervix is closed.

Technique: a metreurynter is filled with water and tested for leakage. The bag is then emptied, rolled up like a cigar, and held by a curved forceps. Specula are inserted into the vagina and the cervix grasped by a bullet forceps. If the cervix is dilated enough to pass a rolled up metreurynter, the

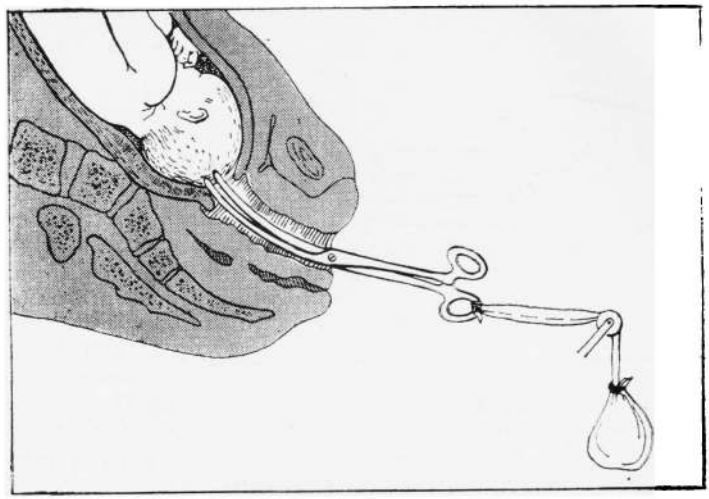

Fig. 309. Traction by the head

latter is introduced into the uterine cavity by the forceps. If the cervix is closed, it is first dilated. In placenta praevia the membranes are first ruptured and the metreurynter is then introduced.

When the metreurynter has passed beyond the internal os, the forceps is removed and the metreurynter is slowly filled with physiological saline solution using a large syringe (Fig. 308). After the metreurynter has been filled, the stem is clamped and a weight (200-400 g) is suspended (through a pulley).

The metreurynter stimulates uterine contractions and acts as a dilator of the cervix. The metreurynter is either delivered spontaneously or removed in 6-8 hours (at any rate it should not remain in the uterus for more than ten hours).

Application of Craniodermal Forceps

The skin on the foetal head is gripped by the forceps of special design and traction in the form of a small weight (200-400 g) is attached to the handle over a pulley (Fig. 309). The constant traction dilates the cervix.

Indications: prolonged labour with a nonviable foetus, haemorrhage in partial placenta praevia and immature foetus. The forceps should be applied if the cervix is dilated to admit at least two fingers.

The craniodermal forceps and metreurynter are now used in rare cases.

Dilation of the Cervix by the Fingers

This is used when circumstances indicate acceleration of labour and also in rigidity of the cervix. This intervention may be performed in complete effacement and partial dilation of the cervix (to admit two fingers).

Technique: the hand is introduced into the vagina, and the index and middle fingers, into the cervix (Fig. 310). The two fingers distend carefully the cervix and when it becomes possible, the third (and the fourth) fingers are introduced. (To attain the

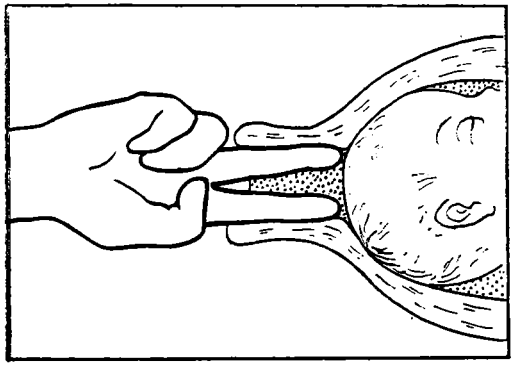

Fig. 310. Dilating the endocervical canal by the fingers

maximum possible dilation, the fifth finger should also pass the cervix.)

Despite the apparent simplicity, this technique is not always successful. If the cervix is rigid, the os is difficult to distend, the fingers soon become tired, and the distended cervix often contracts to the initial state when the fingers are removed.

Incision of the Cervix (Hysterostomatomy)

Incision of the cervix is indicated in case of its rigidity or failure to be dilated completely by the fingers, or else in failure of medicamentous therapy (promedol, procaine hydrochloride injection into the cervix). Less frequently this operation is used as a preparatory step before other operations. The complete effacement is a prerequisite condition for incision of the cervix. The os is exposed by wide vaginal specula and elevators and its margins are fixed by bullet forceps. Blunt curved scissors are used to make two lateral incisions (or four incisions: two anterolateral and two posterolateral incisions) to the depth not exceeding 1 cm (Fig. 311).

Artificial Rupture of the Foetal Membranes

Indications: delayed spontaneous rupture of the membranes, flat membranes, incomplete placenta praevia, polyhydramnios, eclampsia, delayed delivery of the second twin (intact membranes of the second foetus) in multiple pregnancy.

The *technique* is simple: an index finger (or the index and the third finger) is introduced into the vagina and the tense membranes are ruptured during the uterine contraction (Fig. 312). If this fails, a bullet forceps or dressing forceps should be used for the purpose (Fig. 313). The instrumental rupture of the membranes should be controlled visually (with specula) or by tactile perception. In the latter case the tool should be introduced into the vagina along the fingers and the membranes ruptured under their control.

The membranes are usually ruptured at the centre. In case of polyhydramnios the membranes are incised on their side above the cervical os margin so

Fig. 311. Incising the cervix

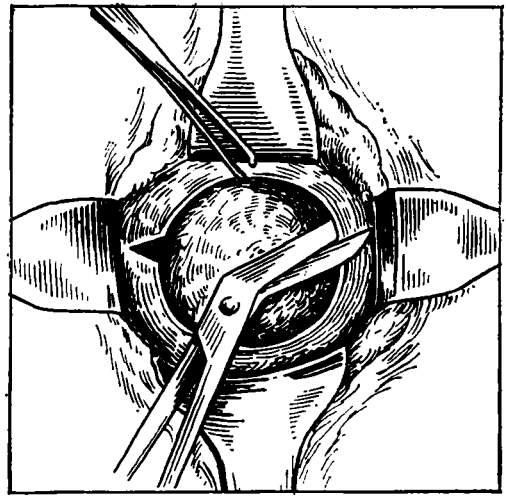

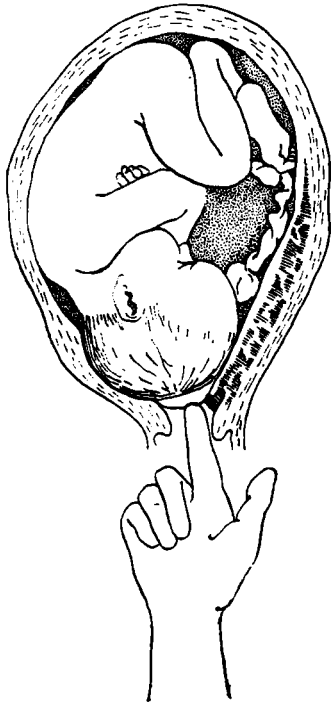

Fig. 312. Rupturing the membranes by the finger

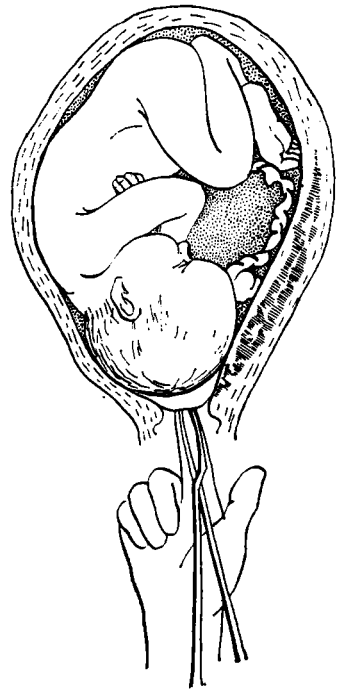

Fig. 313. Rupturing the membranes by a bullet forceps

that the amniotic fluid escapes slowly (to prevent prolapse of the cord or smaller foetal parts). The gush of the fluid may also be controlled by the operator's hand which in this case should stay in the vagina.

Perineotomy

The perineum is incised in cases of its threatened rupture (excessive distension, thinning and whitening of the perineum) and in foetal asphyxia (during delivery of the head).

The perineum is incised by blunt scissors after treating the perineal region with iodine tincture. One blade of the scissors is guided by a finger into the space between the head and the posterior fourchette and the perineum is incised by the median line to the length of 2 or 3 cm (Fig. 314).

Episiotomy. This is a lateral incision of the vulvar ring to dilate the pudendal cleft. Episiotomy is now used less frequently than perineotomy. The tissues are incised at a distance of 2-3 cm from the posterior fourchette in the direction to the ischial tuberosity. The length of a cut, 2 cm (Fig. 315). The incision is repaired after delivery as in lacerations of the perineum.

Obstetric Version

An obstetric version is an operation by which the foetus is turned into a more convenient (longitudinal) position for delivery (N. N. Fenomenov).

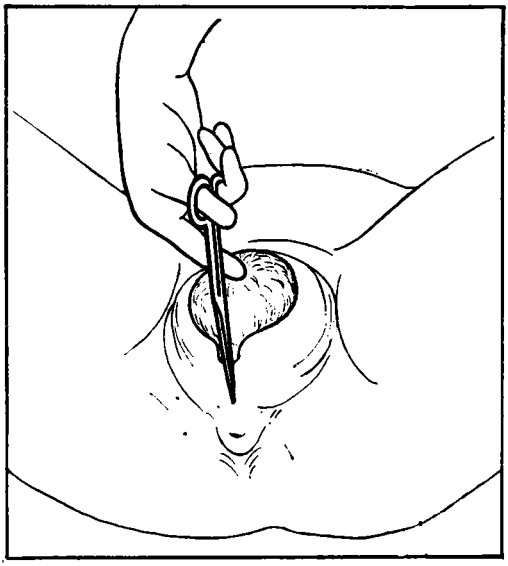

Fig. 314. Perineotomy

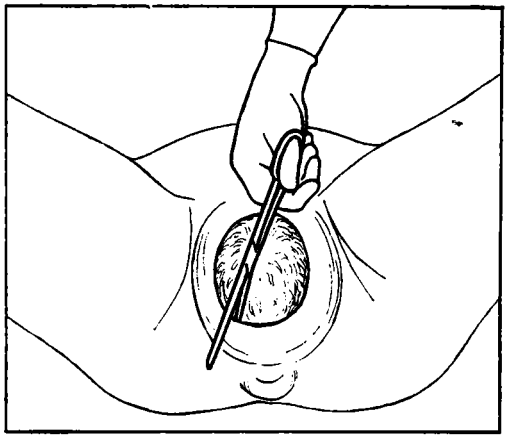

Fig. 315. Episiotomy

The following obstetric versions are differentiated: external version, classical internal version with fully dilated cervix, and internal version with incomplete dilation of the cervix (Braxton Hicks' version).

External Version

External version is used in transverse or oblique presentation of the foetus. Some obstetricians (B. A. Arkhangelsky, M. B. Trubkovich. M. A. Kolosov, and others) consider breech presentation as another indication for external version.

1. *External version in transverse and oblique presentation.* The version should be done in a lying-in hospital after the 35th week of gestation.

The *conditions* required to permit external version are good mobility of the foetus (the amniotic fluid has not escaped), manageable abdominal wall, normal size and architecture of the maternal pelvis, and good health of the mother and the foetus.

The foetal head is usually brought down by external version. Oblique presentation can be corrected without external manipulations: patient is offered to lie on her side (in compliance with the position of the large presenting part of the foetus). If it fails, the foetus is turned externally. If the head is located near the pelvic inlet, the foetal head is brought down, and vice versa. if buttocks are closer to the pelvic inlet, the foetus is turned with its podalic end toward the pelvic inlet.

Technique: the pregnant (parturient) is given 1 ml of a 1 per cent morphine solution, her bladder is evacuated, and she is placed on a firm bed. The woman flexes her legs and the physician sits on her right side. One hand of the physician rests on the foetal head and the other on the foetal buttocks. By careful manipulations the head is moved toward the pelvic inlet and the buttocks toward the uterine bottom (Fig. 316). When the foetus is turned with its buttocks toward the maternal

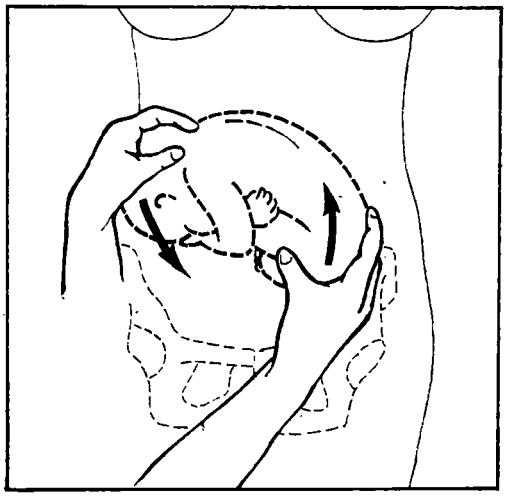

Fig. 316. External version in transverse presentation

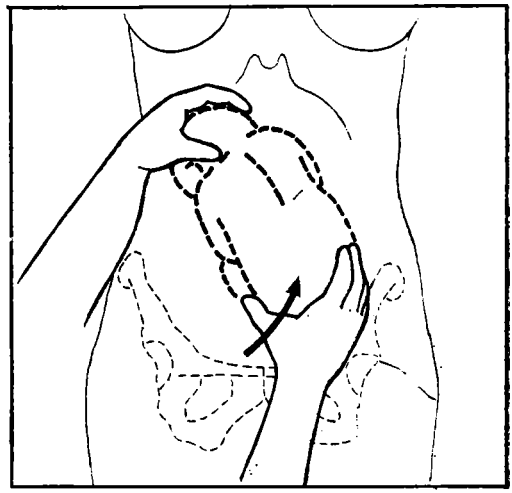

Fig. 317. External version in breech presentation

pelvis, the head is brought up to the uterine bottom.

When the foetus is turned into the longitudinal position measures are taken to prevent its return to malpresentation. To that end, two pads (rolled up bed-sheets) are placed by sides of the foetus (its back and the smaller parts flexed on the chest and abdomen) and bandaged in this position without pressing tightly on the maternal abdomen.

2. *Prophylactic external version of the foetus with its head down into the maternal pelvis from breech presentation.* The version contributes, in the opinion of B. A. Arkhangelsky, to the reduction of stillbirth rate. It is therefore recommended to be performed during pregnancy.

In the opinion of many obstetricians, labour in breech presentation should be allowed to continue spontaneously and breech presentation in itself is not an indication for version.

The *conditions* required to permit version of the foetus from breech presentation into the cephalic presentation are the same as for the version from transverse presentation.

Before proceeding to external version, all possible contraindications should be considered. These are previous premature labour and stillbirths, postoperative scar tissues on the abdominal wall and the uterus, toxaemia and haemorrhage of present pregnancy, abnormalities in development of the uterus and its tumours, etc.

External version from breech presentation should be done on the 35-36th week of pregnancy in a lying-in hospital. The *technique* is about the same as in version from transverse presentation, the difference being in that the foetus is turned through 90° from transverse and 180° from breech presentation.

The buttocks of the foetus are displaced toward the uterine bottom (in the direction of the foetal back) and the head into the maternal pelvis (in

the direction of the foetal abdominal wall) (Fig. 317).

Classical Podalic Version with Fully Dilated Cervix

Indications for podalic version are as follows: (1) transverse presentation (if external version fails); (2) unfavourable presentation and asynclitism (brow presentation, posterior face presentation, posterior asynclitism); (3) prolapse of the umbilical cord and smaller parts in cephalic presentation; (4) complications and diseases endangering the mother and foetus (premature separation of the placenta, etc.).

The *requisite conditions* are the following: (1) full dilation of the cervix; (2) intact membranes or the amniotic fluid may have just escaped; (3) the foetus is fully mobile in the uterus; (4) absence of cephalopelvic disproportion (the absence of pronounced contracture of the pelvis).

Fig. 318. Obstetrician's hand

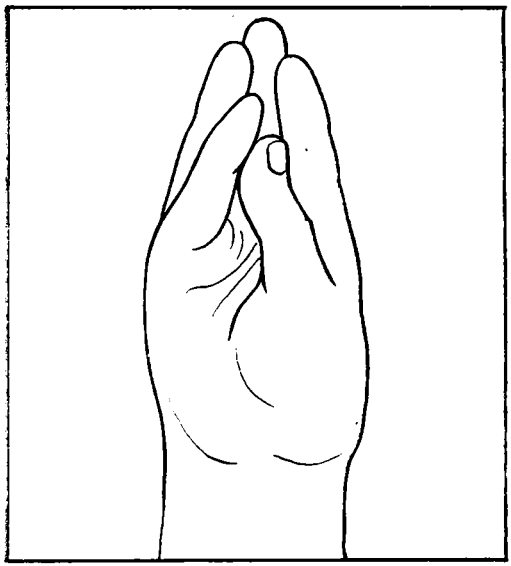

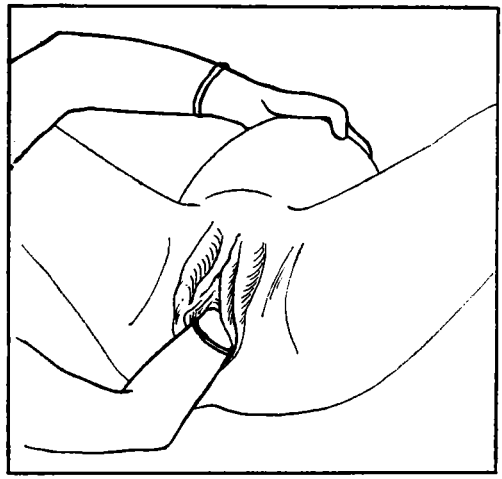

Fig. 319. Introduction of the hand into the uterus

Technique. The operation comprises the following manoeuvres: introduction of the operator's hand into the vagina, identification of the leg, grasping the leg, and version proper.

A repeated external and vaginal examination is required before the operation in order to determine exactly the position and presentation of the foetus, the degree of cervix dilation, and other important factors.

Introduction of the operator's hand. The uterus is usually invaded by the right hand, which is more apt. Some surgeons however prefer the left hand to be internal. M. S. Malinovsky thus formulated the rule to be followed by the surgeon in his choice of the internal hand: when a foetus is to be turned from transverse presentation into longitudinal one, the internal hand should correspond to the pelvic end of the foetus (left hand for the left, and right for the right position of the foetus); if the foetus is in the longitudinal presentation, the internal hand should correspond to the position of the smal-

ler parts of the foetus (left hand in the left, and right hand in the right position).

The external hand is used to open the pudendal cleft and the internal hand, coated with sterile vaseline oil and shaped into a cone (Fig. 318), is introduced into the vagina and moved toward the uterine cervix (the back of the hand should face the sacrum). When the fingers reach the cervical os, the external hand should be placed on the uterine bottom (Fig. 319). The foetal membranes are then ruptured and the hand is moved farther into the uterus. If the head is presenting, it is pushed toward the foetal back.

Identification of the leg. A leg lying near the abdominal wall of the mother should be found for version from the longitudinal presentation. The choice of the leg in transverse presentation depends on the position of the foetus: the inferior leg should be grasped in anterior presentation and the superior in the posterior presentation. To identify the leg, the hand feels the side of the foetus and slides from the armpit to the pelvic end, and further by the thigh to grasp the leg. The external hand should assist by moving the pelvic end down toward the internal hand of the operator.

Grasping the leg. This can be done by two methods: (1) the leg is grasped by the entire hand, i.e. four fingers are placed on the anterior part of the leg while the thumb is placed on the calf to reach the popliteal fossa (Fig. 320, *a*); (2) the index and the middle fingers grasp the malleolus (Fig. 320, *b*) while the thumb supports

Fig. 320. Extraction by the leg:
a — grasping the leg by the hand;
b — grasping the foot by two fingers

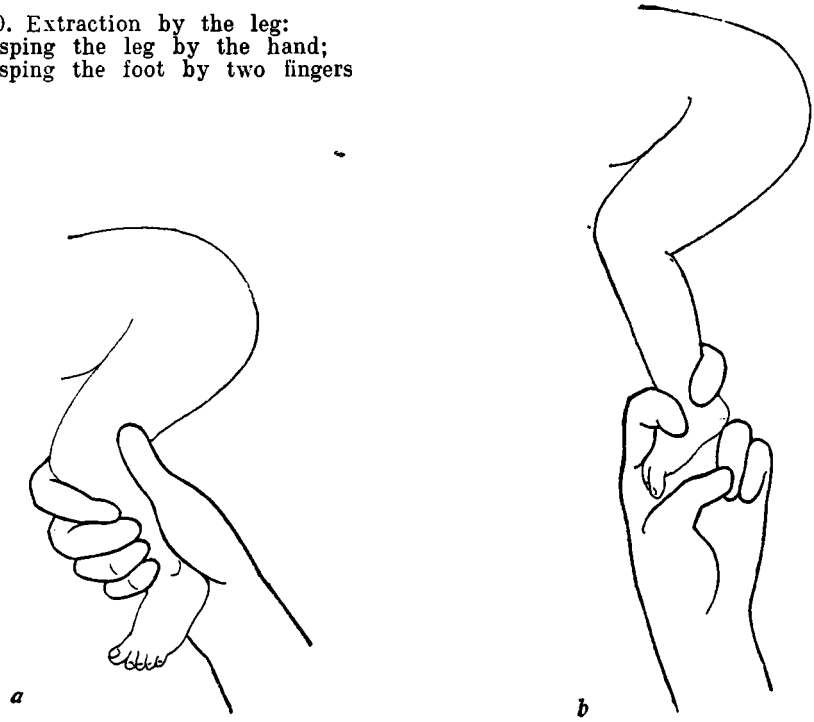

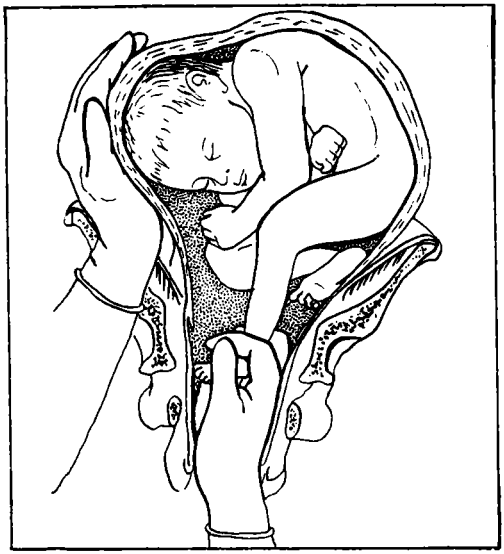

Fig. 321. Podalic version

Fig. 322. Version is complete. The leg is extracted to the knee

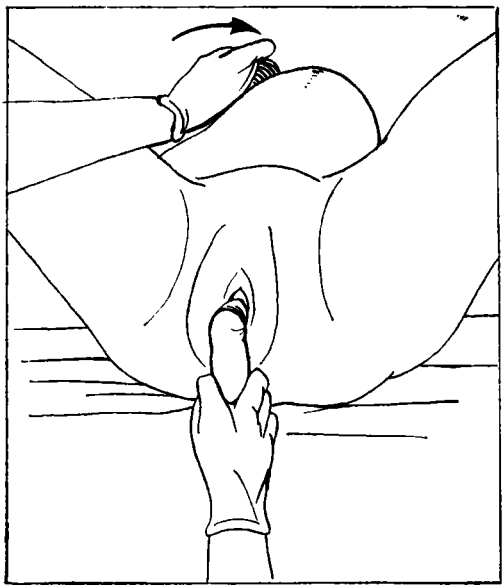

the sole. The former method is however more reliable.

Version proper. After a firm grip is placed on the foetal leg, the external hand moves the foetal head upwards, i.e. to the uterine bottom. During the course of this manipulation, the internal hand pulls the leg outside the vagina (Fig. 321). The version is considered complete when the leg is extracted from the pudendal cleft to the knee (Fig. 322). This indicates that the foetus assumes the longitudinal position.

The arm often prolapses with the discharge of the amniotic fluid in transverse presentation. The prolapsed arm should not be corrected but only pulled by a sterile gauze strip toward the symphysis. As the foetus is then turned, the arm retracts spontaneously. Version of the foetus is often attended with asphyxia and the foetus should therefore be extracted by the leg after its version.

In very rare cases when a physician cannot be summoned or the patient cannot be transported to the hospital, the obstetrician is allowed to perform version without anaesthesia. The patient should be given 1 ml of a 0.1 per cent atropine sulphate solution and 1 ml of a 1 per cent papaverine solution before the operation. All manoeuvres should be performed in the intervals between uterine contractions.

Podalic Version with Incomplete Dilation of the Cervix (Braxton Hicks' version)

The following *indications* for internal version sometimes arise in pathological labour:

1. Placenta praevia. The lowering pelvic end of the foetus compresses the placenta against the pelvic wall to stop haemorrhage. This operation is

however complicated and the foetus dies in most cases; the risk of injury to the uterine cervix is also high. Other operations should therefore be preferred in placenta praevia (see Ch. 20). Version of the foetus with incomplete dilation of the cervix is allowed if an immature foetus is dead.

2. Transverse (oblique) presentation with early escape of the amniotic fluid and dead immature foetus.

Requisite conditions: (1) the cervix is dilated to admit at least two fingers; (2) the foetus is mobile (the amniotic fluids have not escaped or escaped only a short time ago); (3) pronounced contracture of the pelvis is absent; (4) indications for urgent parturition are absent.

Technique. A conically shaped obstetrician's hand coated with vaseline oil is introduced into the vagina, and the index and third fingers into the cervix. The membranes are first ruptured and the head pushed away (in cephalic presentation). The external hand should be placed on the uterine bottom. The rest of the operation is bimanual. The external hand is used to move the pelvic end of the foetus toward the fingers of the internal hand. The two fingers grasp the leg (by the malleolus, as shown in Fig. 323). The external hand is now moved onto the foetal head to push it upwards, towards the uterine bottom. The internal hand pulls the leg downwards to extract it from the cervix and the vagina. The version is complete when the knee shows from the pudendal cleft. The further conduct of labour is conservative. A traction is applied to the leg (200-400 g).

Any attempt to accelerate labour (traction by the leg) or to extract the foetus is prohibited because it will involve grave injuries (rupture of the cervix and the lower uterine segment which will cause fatal bleeding

Extraction of the Foetus by the Pelvic End

Whenever complications endangering the mother and the foetus arise, labour in breech presentation should be ended by extraction of the foetus. This method is also used after the classical podalic version with a fully dilated cervix.

Extraction differs from manual assistance. Manual assistance in breech presentation is given after spontaneous delivery of the foetus to the lower angle of the shoulder blades, its objective being to deliver the arms and the head. Extraction of the foetus by the pelvic end is an operation in which the entire foetus, beginning with the legs, is extracted. The operation is performed by the hands only.

Fig. 323. Braxton Hicks' version

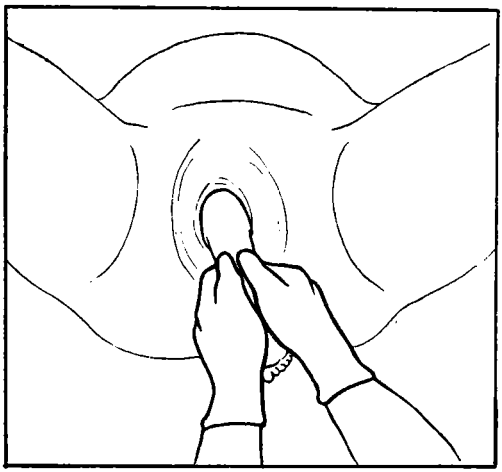

Fig. 324. Grasping the leg for extraction

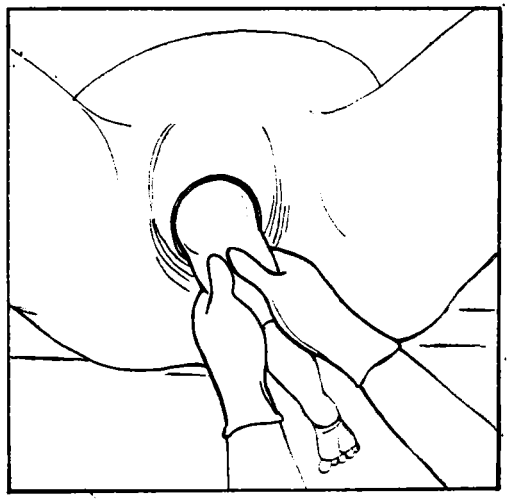

Fig. 325. As the leg is being extracted, the operator's hands move from the leg onto the hip

Indications: (1) grave diseases requiring urgent termination of labour (eclampsia, heart diseases, etc.); (2) beginning asphyxia of the foetus; (3) after the classical podalic version.

Requisite conditions: (1) full dilation of the cervix; (2) rupture of the foetal membranes; (3) absence of cephalopelvic disproportion.

The foetus is extracted by one leg (in single footling) or by two legs (in double footling presentation). The foetus is extracted by the groins in frank breech presentation. In complete breech presentation the anterior leg is extended to convert complete breech into single footling presentation with subsequent extraction of the foetus by the leg.

Extraction by the Leg (or legs)

If the presenting leg is in the vagina, it is extracted by two fingers. The leg is grasped as follows: the thumb is placed on the calf, and the other four fingers on the anterior surface of the leg. The leg may be grasped by both hands; both thumbs are then placed on the calves (Fig. 324). This grip on the leg prevents its fracture. It is desirable that the knee should also be grasped to prevent its strain during extraction. The downward traction should then be applied to the leg. As the leg appears from the birth canal, the operator's hand should move farther along the infant leg toward the pudendal cleft (Fig. 325). The downward traction should be continued until the forthcoming buttock and the iliac bone are brought beneath the symphysis. The forthcoming thigh is then grasped by both hands and lifted slightly (Fig. 326). The foetal body is thus flexed and the aftercoming buttock is delivered over the perineum.

No attemps should be taken to free the aftercoming leg for it may be fractured; the leg will be delivered spontaneously during further traction.

After the second buttock has been delivered, one hand should grasp the anterior thigh (the thumb being positioned on the sacrum), while the index finger of the other hand should engage the posterior groin of the foetus with the thumb resting on the sacrum. The other fingers should be pressed against the palm (Fig. 327). With the hands thus gripped on the buttocks, the operator continues the downward traction (but along a more horizontal axis). After the aftercoming leg is delivered it is taken by the hand in the same manner and the foetus is extracted to the navel. The cord is checked for the absence of tension, and the foetus is extracted to the lower margin of the shoulder blades. Now the arms and the head are freed by manoeuvres as specified for manual assistance.

In double footling presentation the foetus is extracted by both legs. If the legs are in the vagina, each is taken by the hand with the thumbs on the calves and the fingers on the leg. As the legs appear from the birth canal the hands should move toward the pudendal cleft. The other manoeuvres are the same as in extraction of a single footling.

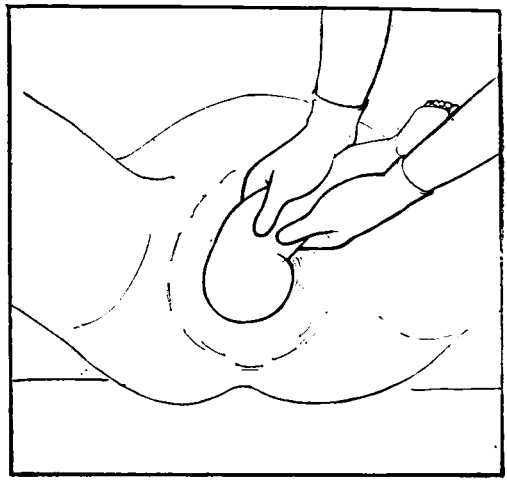

Fig. 326. As soon as the iliac bone is brought beneath the symphysis (fulcrum), the hip should be lifted

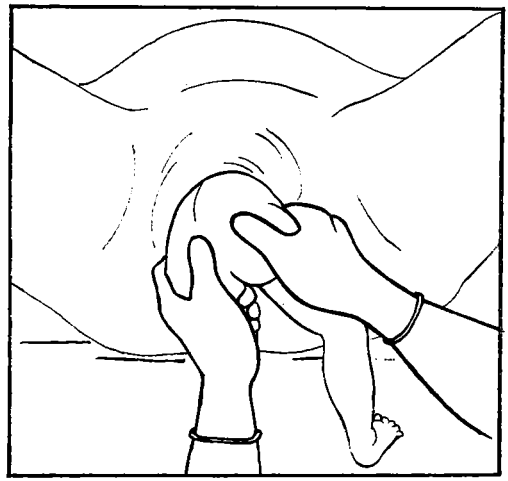

Fig. 327. Operator's hands during extraction of the foetal torso

Extraction by the Groin

Extraction in frank breech presentation begins with insertion of one index finger into the anterior foetal groin (Fig. 328). The traction is continued until the anterior buttock is freed and the iliac bone is brought beneath the pubic arch. Traction is only applied when the uterus contracts; in order to add to the traction effort, the other hand should assist by grasping the wrist of the operating hand.

When the anterior iliac bone is brought beneath the symphysis, the direction of traction should be changed to the upward one. The foetal torso is flexed and the posterior buttock is disengaged. The index finger of the other hand should now be inserted into the other groin. Traction is continued

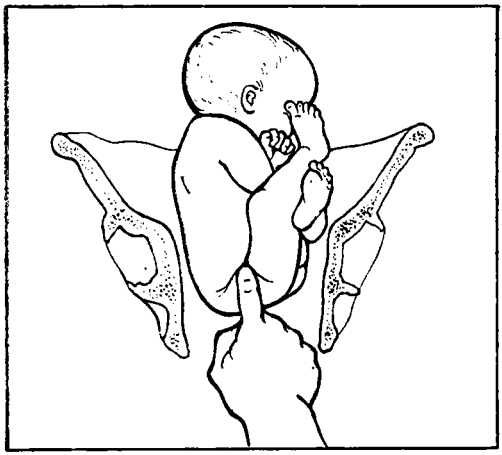

Fig. 328. Extraction by the groins

until the foetus is delivered to the lower margin of the shoulder blade. The legs are freed spontaneously.

The arms and the head are freed as in manual assistance.

Extraction by the groins is one of the most difficult obstetric operations. The operating hand quickly fatigues, the buttocks move slowly. It is especially difficult to extract the foetus with the high position of its buttocks. Some obstetricians suggested that the foetus might in this case be extracted by engaging the foetal groins with blunt metal hooks or a loop of a gauze strip. But this method is fraught with danger of dislocation or even fracture of the foetal bones. It is therefore used only with nonviable foetuses.

Possible complications. The following complications may occur in extraction (manual assistance): spasm of the uterine cervix, extension of the arms, posterior presentation, etc.

In order to remove the spasm of the cervix os, the operation is performed with anaesthesia. Spasms may be prevented by giving (before operation) 1 ml of a 1 per cent papaverine solution and 1 ml of a 0.1 per cent atropine solution. Extension of the arm (on the face, ears or the occiput) is a very dangerous complication. In order to correct the arm, four fingers should be inserted into the vagina and the arm pulled down along the face and chest (the foetus 'washes' its face).

Extraction of the foetus is also difficult with persistent posterior position (the chin turns toward the symphysis and the occiput toward the sacrum). To disengage the head in posterior position the following manipulations are required. The tip of the index finger is placed into the foetal mouth to flex the head, while the other hand of the operator should extract the foetus until the nose bridge (fulcrum) is brought beneath the symphysis (Fig. 329). The torso of the foetus is then bent anteriorly (toward the mother's abdomen) and the head is delivered over the perineum. If the head is extended and the finger fails to reach the mouth, the torso of the foetus should be flexed on the mother's abdomen, while the other hand of the operator should grip the shoulder girdle with the fingers (like a fork) to assist extraction of the foetus. The head passes the pelvis by its vertical diameter, the fulcrum being the region of the hyoid bone (Fig. 330).

Obstetric Forceps

Obstetric forcepses are *tools commonly used to apply traction to the head of a viable foetus* when it is necessary to terminate labour quickly. Early in the 17th century obstetric forceps was used by a Scotch physician Chamberlen. To the discredit of their family, the Chamberlens kept forceps as a family secret for almost a century. But early

in the 18th century another forceps was invented by Palfyn who reported it to the Academy of Sciences in Paris.

The design of the forceps was later improved by many authors (Levret, Simpson, Naegele, Lazarevich, Boryakovsky, Fedorov, and others).

Professor of the Moscow University Dr. Erasmus was the first to apply forceps in Russia (1765). Wide practical use of obstetric forceps was further promoted by N. M. Maksimovich-Ambodik. Outstanding Russian obstetricians G. I. Korablev, A. Ya. Krasovsky, N. N. Fenomenov and others made an important contribution to the development of obstetric forceps. The Fenomenov modification of the Simpson forceps is now commonly used (Fig. 331). The forceps consists of two branches crossing in their middle points. Each branch comprises the following three parts: (1) fenestrated blade, or spoon, by which the head is grasped; (2) a lock by which the forceps branches are immobilized; and (3) the handles by which the head fixed between the spoons is extracted. The handles are provided with prominences (the so-called Busch's hooks) which facilitate the grasp of the surgeon hands on the forceps during extraction. The forceps has two curves, namely the cephalic and the pelvic curve. The cephalic curve is in the apposition to the curvature of the foetal head, while the pelvic curve coincides with the curvature of the pelvic axis. Each blade of the forceps is introduced separately into the left and right sides of the vagina (pelvis). The left blade (to be introduced into the left part of the vagina) is always inserted first. The locking part of this branch is situated beneath the locking part of the other (right) branch. The other (right) blade is inserted into the right side of the pelvis. This should always be inserted second which is necessary for locking the forceps.

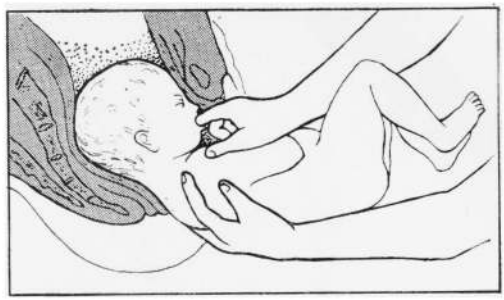

Fig. 329. Delivery of the head in posterior position (the vertex is first flexed)

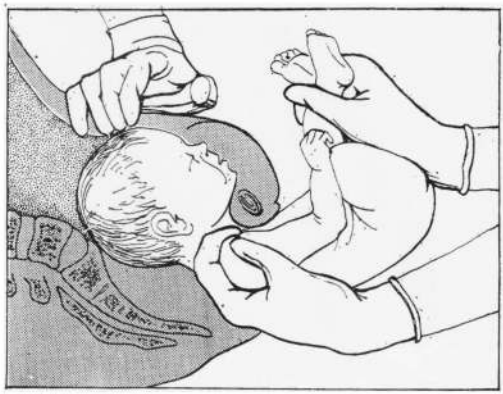

Fig. 330. Extraction of the deflexed head in posterior position

Lazarevich's forceps is also very popular (Fig. 332). This tool has no pelvic curve and the branches do not cross on each other (straight parallel forceps).

Indications for application of obstetric forceps are diseases and complications which necessitate rapid delivery for the sake of maternal and foetal safety. These are: (1) secondary uterine inertia and the absence of head progress during 2 or 3 hours; (2) endometritis of labour; (3) grave diseases

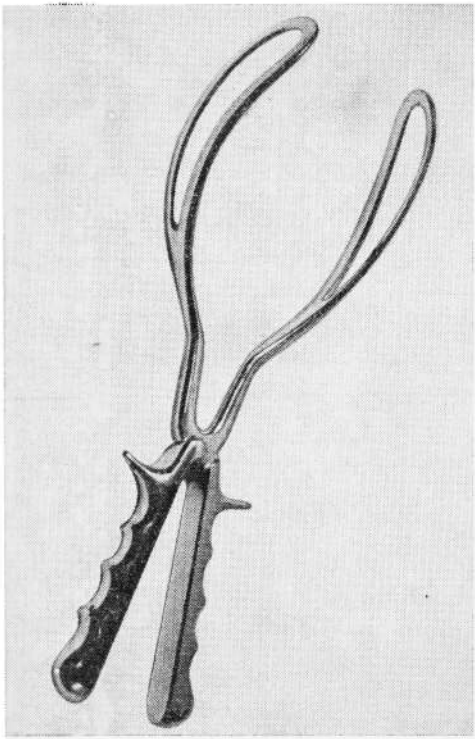

Fig. 331. Simpson's forceps

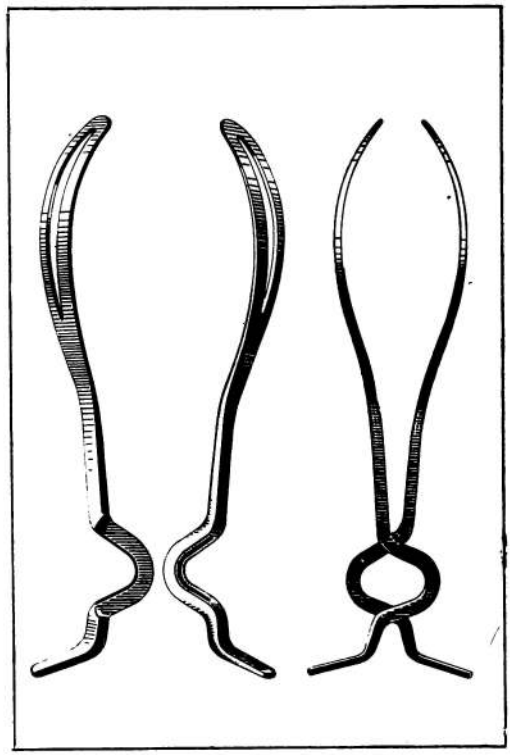

Fig. 332. Lazarevich's forceps

of the cardiovascular system and the lungs, etc.; (4) eclampsia (provided its fits do not subside with the appropriate treatment); (5) foetal distress.

Requisite conditions: (1) viable foetus; (2) full dilation of the cervix; (3) ruptured foetal membranes; (4) the foetal head is of normal size (neither small as in a premature foetus, nor large as in a giant foetus or in a hydrocephalus); (5) normal pelvic architecture (the contracture may be only insignificant); (6) the head is in the pelvic cavity or at its outlet.

The best conditions for application of forceps are with the head descended to the pelvic outlet. The forceps used in this case are called low forceps. If, the head stands inside the pelvic cavity, mid forceps should be used. The technique of application of mid forceps is more difficult.

Application of Low Forceps

Forceps, wide specula, bullet forceps (for inspection of the cervix after operation), scissors for perineotomy and tools required for suturing the perineum should be prepared before the operation. Perineotomy is sometimes needed before application of forceps. Forceps delivery is often attended with perineal lacerations, which should be repaired.

Before operation the woman is given a vaginal examination in order to estab-

lish the position of the head in the pelvis, the direction of the sagittal suture, and the position of the fontanelles. In anterior occiput presentation the head appears at the pelvic outlet with the sagittal suture in the anteroposterior diameter, the posterior fontanelle being at the symphysis and the anterior fontanelle directed toward the sacrum.

The operation comprises the following movements: (1) insertion of the forceps blades; (2) locking the forceps; (3) trial traction; (4) traction proper (extraction of the head); and (5) removal of the forceps.

The *forceps blades are inserted* as follows: the left blade is inserted by the left hand into the left part of the pelvis (vagina) and the right blade is inserted by the right hand into the right half of the pelvis. The left blade is inserted first, and the right the second. If the head is in the pelvic outlet plane, the blades are inserted in the transverse diameter of the pelvis. The forceps are applied onto the parietal tuberosities and ears of the foetal head, with the posterior fontanelle (the leading point) being in the plane of the forceps: the pelvic curve of the forceps, the cephalic axis (from the posterior fontanelle to the chin) and the pelvic axis coincide (Fig. 333).

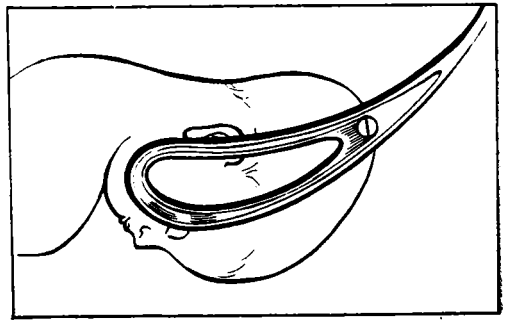

Fig. 333. Correct application of forceps

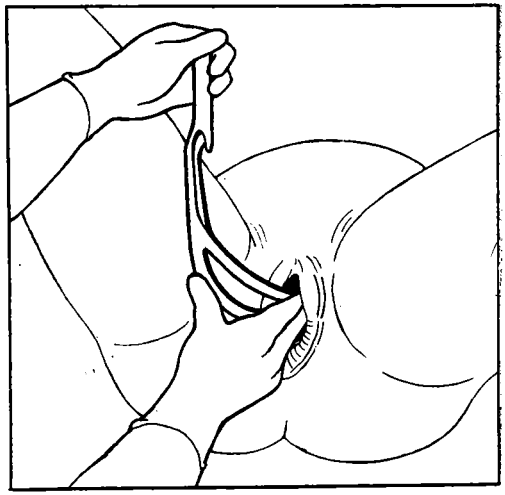

Fig. 334. Insertion of the left forceps blade

The blades are inserted as follows: four fingers of the right hand are introduced into the vagina and rested on

Fig. 335. Trial traction

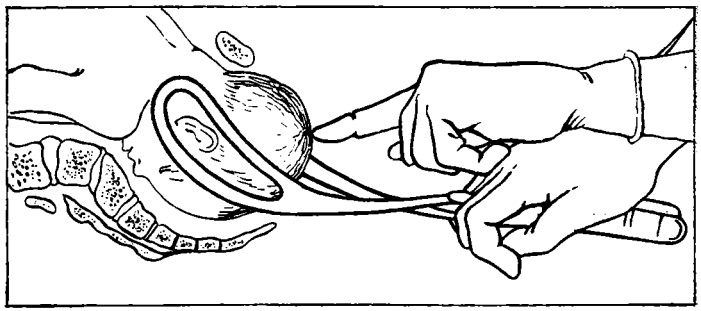

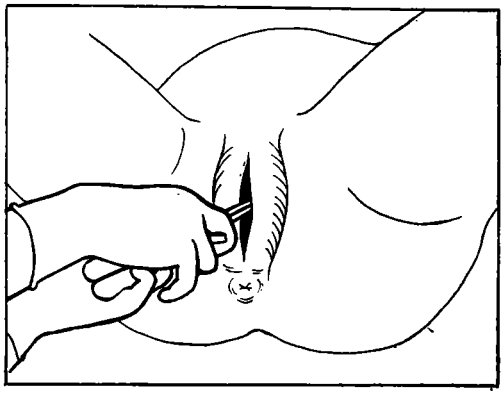

Fig. 336. Forceps delivery of the head

the lateral surface of the head (the finger tips are directed toward the foetal chin). The left part of the forceps is taken by the left hand like a fiddle or a pen, and brought to the right groin of the parturient (parallel to the flexure). The left blade is inserted into the vagina between the right hand and the head, the inferior margin of the blade sliding in the groove formed by the index and the third finger. No excessive pressure should be applied to the forceps blade (Fig. 334). As the left blade passes into the depth, the handle is lowered toward the perineum. The internal hand guides the blade toward the parietal tuberosity of the foetal head. The right hand is then removed from the vagina, and the handle is now held by the assistant.

The right blade is inserted in the same manner, the guidance and control being effected by the left hand. The handle of the right branch always overlies the left one.

Locking the forceps. Each handle is grasped by the synonymous hand. The branches are brought together and locked. Correctly applied forceps locks easily.

Trial traction. When the forceps is locked, a trial traction should be attempted to see that the blades do not slip. To that end, the handles are grasped by the right hand and the left hand is placed over the right one with the index finger touching the foetal head. Traction is now applied (Fig. 335). If the forceps is applied correctly, the head will move together with the forceps and the index finger remains in contact with the head. If the forceps slips (incorrectly applied forceps) a gap forms between the finger and the head (the forceps is extracted from the vagina, while the head remains in its initial position).

Traction proper. A trial traction is followed by traction proper. This is the extraction of the foetal head. The right hand grasps the lock of the forceps (two fingers resting over the Busch's hooks) and the left hand takes hold of the handle (Fig. 336). These movements of the mechanism of labour that have not been completed spontaneously should be performed artificially during traction. Traction should be gradual and smooth to simulate the natural progress of the foetus through the birth canal (each traction continuing for 60-90 seconds). One or two-minute intervals should be made between each traction, during which the pressure of the forceps on the foetal head should be slightly released to improve cerebral circulation of the foetus.

The direction of traction should correspond to the axis along which a spontaneously expelled head moves (i.e. along the pelvic axis).

If the head is at the pelvic outlet, traction should be horizontal until the occipital tuberosity has been freed and the posterior cranial fossa is brought to the pubic arch. The obstetrician should assume her position at the left

side of the parturient, grasp the handles with the right hand and pull the head upwards, the left hand being used to protect the perineum from possible lacerations. The vertex is extended by the upward traction and the head is thus delivered.

Removal of forceps. The forceps may be removed from the head after the occipital and parietal tuberosities have been freed. Further delivery of the head may be assisted manually (as in spontaneous delivery). The head may also be delivered in forceps.

The forceps is removed in the reverse order: the right blade is removed first, and the left second. The handles of the forceps should be directed toward the opposite thigh of the woman.

After delivery of the placenta, the cervix should be inspected with specula. Lacerations, if any, should be repaired. If the vagina and the perineum are injured they should be sutured by routine technique.

Caesarean Section

Caesarean section is an operation by which the foetus and the placenta are extracted through a surgically opened uterus.

A caesarean section after a sudden death of the mother (to save the infant) was known in ancient times. The first caesarean section on a living mother was performed early in the 17th century, but it became widely used only after formulation of the asepsis and antisepsis rules (late 19th century).

The first caesarean section in Russia was reported by D. Samoilovich in 1780. N. I. Pobedinsky made an important contribution to the development of abdominal hysterotomy in Russia.

A caesarean section may be performed through the abdominal wall (abdominal hysterotomy) or through the vagina (vaginal hysterotomy).

Vaginal hysterotomy is performed less frequently, usually in pre-term pregnancy.

Abdominal Hysterotomy

Indications: (1) a marked anatomical contracture of the pelvis (third or fourth degree of contracture); (2) cephalopelvic disproportion (clinically contracted pelvis); (3) threatened rupture of the uterus; (4) central placenta praevia (also lateral placenta praevia attended with excessive bleeding); (5) premature separation of normally implanted placenta (internal bleeding and shock); (6) grave disease of the heart, hypertension, grave toxaemia of pregnancy, etc.; (7) scar tissues after previous operations on the uterus. post-term pregnancy concurrent with contracted pelvis, neglected transverse presentation of a viable foetus, and other complications which interfere with spontaneous pelvic delivery and endanger the lives of the mother and the foetus.

Requisite conditions: the absence of infection, alive and viable foetus; the operation should preferably be performed during early labour.

The following tools are required for a caesarean operation: scalpel (2), long forceps (2), anatomical forceps (3-4), surgical forceps (3-4), haemostats (10 long and 5-6 short clamps), Pean's forceps (15-16), dressing forceps (5-6), bullet forceps (2), ovarian forceps (2), curettes (2-3), needle holders (2), set of 10-12 needles, scissors (2 curved and 2 straight), abdominal specula, a catheter, a syringe with injection needles, and drape clips (4).

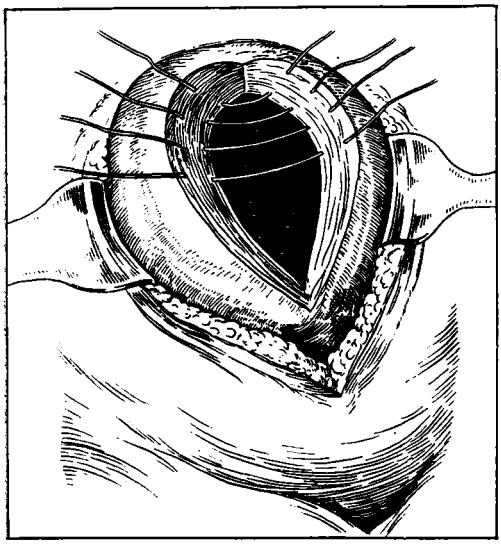

Fig. 337. Abdominal hysterotomy (caesarean section). Repair of the uterine wall

All materials and preparations that might be needed for blood transfusion and resuscitation of the foetus (that may be delivered in asphyxia) should be prepared before the operation.

Technique: the anterior abdominal wall is opened layer by layer, along the white line. The incision begins above the os pubis, extends to the navel and slightly above it. The anterior surface of the uterus is separated from the abdominal cavity by sterile drapes so that the amniotic fluid does not get into it. An about 12 cm long incision is made on the anterior wall of the uterus and the foetus is removed from the opened uterus by the leg. The umbilical cord is cut between two clamps and the infant is handed over to the obstetrician. Next the placenta is removed, the uterine cavity is examined by hand or curette, and the uterine wall is repaired layer by layer (Fig. 337); all tools and other objects are removed and the abdominal wall is sutured also layer by layer.

During recent years the preferable practice is to incise the lower uterine segment. To this end, the uterovesical fold of the peritoneum should first be opened, and the bladder displaced downward. After removal of the foetus and the placenta, and after suturing the lower uterine segment, the position of the bladder is restored and the uterovesical fold is repaired.

Vacuum Extraction

Use of a vacuum extractor is a modern method of delivery. The apparatus consists of a vacuum pump and a set of cups which are applied to the scalp of the foetal head.

The operating principle consists in creating a negative pressure in the space between the foetal head and the steel cup by which the head is firmly held. Traction is applied to the cup to accomplish delivery.

A vacuum extractor is used in cases where parturition should be accelerated, while a caesarean section is contraindicated and forceps delivery is impossible.

The *main indications* for applying a vacuum extractor are as follows: persistent uterine inertia, beginning intrauterine asphyxia, repeated prolapse of the umbilical cord.

Requisite conditions: fully dilated cervix, ruptured foetal membranes, absence of cephalopelvic disproportion, occiput presentation. The use of a vacuum extractor is contraindicated in deflexed vertex, premature labour, cephalopelvic disproportion, and also diseases which require relaxation or removal of abdominal contractions (heart diseases, grave toxaemia of pregnancy, etc.). The cup of the vacuum extractor

is applied to the region of the posterior fontanelle and a negative pressure of 0.4-0.5 kg/sq.cm is created. During traction the vacuum is increased to 0.7-0.8 kg/sq.cm. Traction is applied during abdominal contractions (Fig. 338).

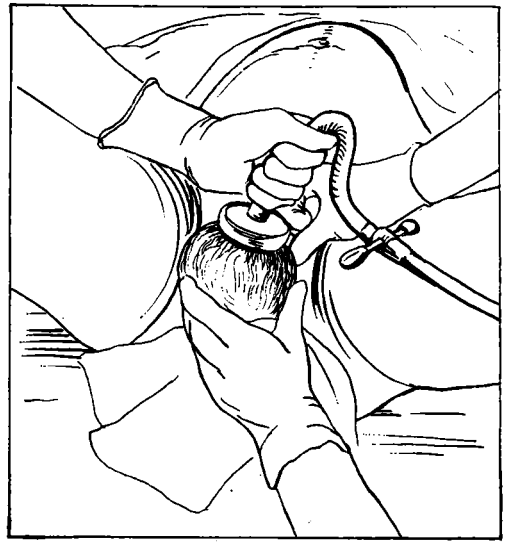

Fig. 338. Using a vacuum extractor

Destructive Operations on the Foetus

Destructive operations are performed on a dead foetus. These unpleasant operations are performed on a living foetus in extremely rare cases where the life of the mother is endangered and there are no other ways to accomplish delivery. The operations include craniotomy (to reduce the volume of the head, as in a hydrocephalic foetus), decapitation (separation of the head from the trunk), evisceration (removal of the internal organs), cleidotomy (dissection of the clavicles), and spondylotomy (destruction of the spinal column).

The operations on the foetal torso and neck (decapitation, evisceration, cleidotomy and spondylotomy) are called embryotomy.

Craniotomy

This operation is used for the following *indications*: dead foetus, marked cephalopelvic disproportion, signs of inevitable rupture of the uterus, other fatal complications, if parturition by any other way is impossible.

The necessary tools are a Fenomenov perforator or a Blot perforator (Fig 339), wide vaginal specula (2), elevator (2), Museux's forceps (2), bullet forceps (2), spoon for destroying the brain (1), cranioclast (1), and scissors for cutting clavicles (1). Before operation all tools and materials should be made ready in case necessity arises to repair lacerated cervix and perineum.

Craniotomy comprises the following movements: (1) perforation of the head; (2) excerebration (destruction and removal of the brain); and (3) cranioclasis (removal of the foetal head).

The *technique* is as follows. The vagina is opened by the specula, a Museux forceps is applied to the head, the head is pulled downward and perforated. The Fenomenov perforator should preferably be used. It is actually an auger in a sheath that protects the soft tissues of the genital tract from occasional injury. The auger makes an opening in the presenting bone of the skull. A spear-shaped Blot perforator can also be used to make a cross-like cut in the skull in the region of the suture or the fontanelle (Fig. 340). The cutting surfaces of the Blot perforator are exposed and measures should therefore be taken to protect the soft tissues of the birth canal from injuries.

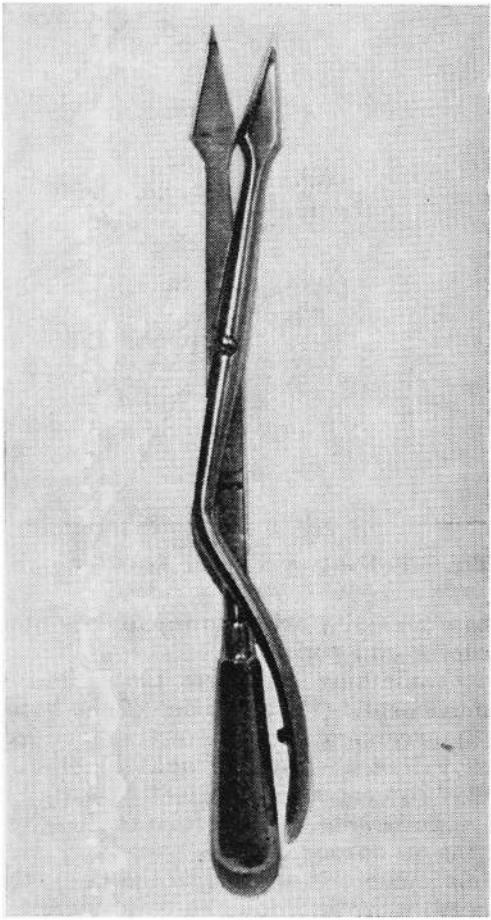

Fig. 339. Blot's perforator

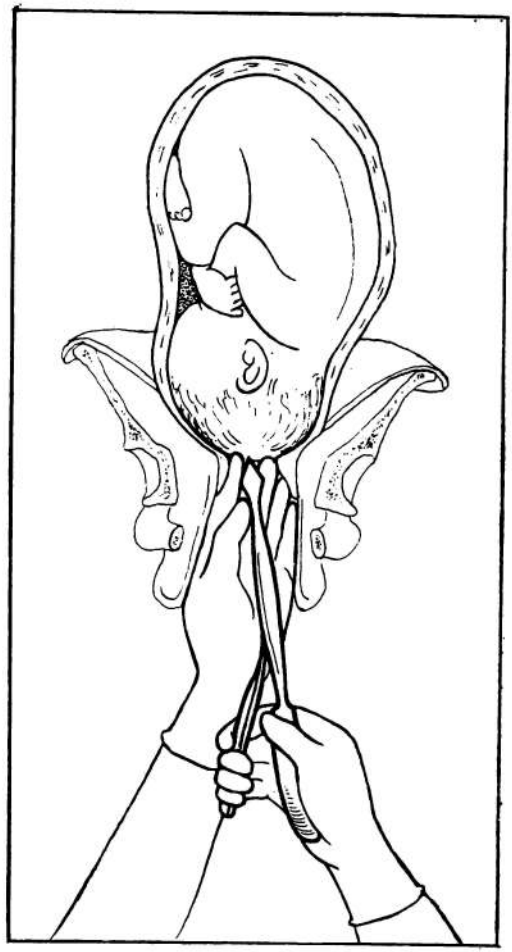

Fig. 340. Perforating the foetal head

To this end the handle of the perforator is lowered and the anterior wall of the vagina and the bladder are protected by the speculum or the left hand. A sterile spoon or a curette is used to destroy the brain which is readily drained from the perforated skull. Some obstetricians rinse the emptied skull with sterile physiological solution.

When the brain is removed, the skull reduces in size. The next step is cranioclasis, i.e. extraction of the head using a cranioclast (Fig. 341). A cranioclast consists of two branches, each comprising a blade, a locking part, a handle and a screw. A solid blade is inserted inside the cranium while a fenestrated blade is placed over the face bones. (Each blade is introduced inside the uterus by the procedure described for using obstetric forceps.) The branches are then closed and fixed by the

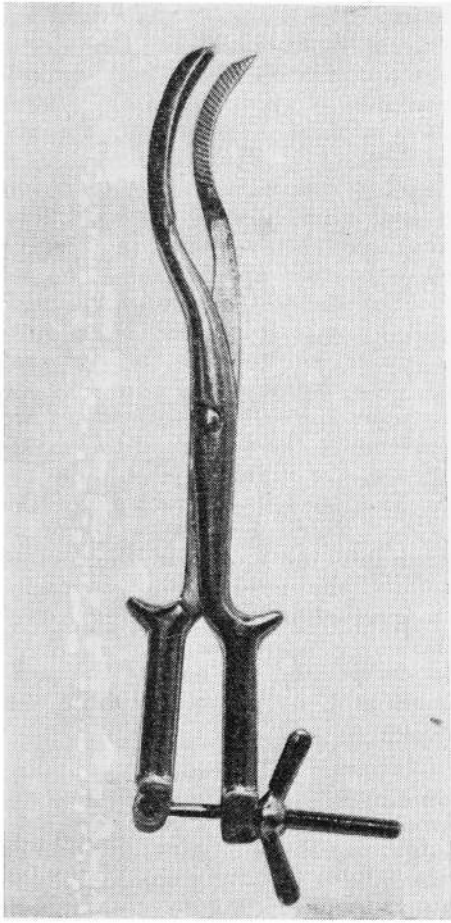

Fig. 341. Cranioclast

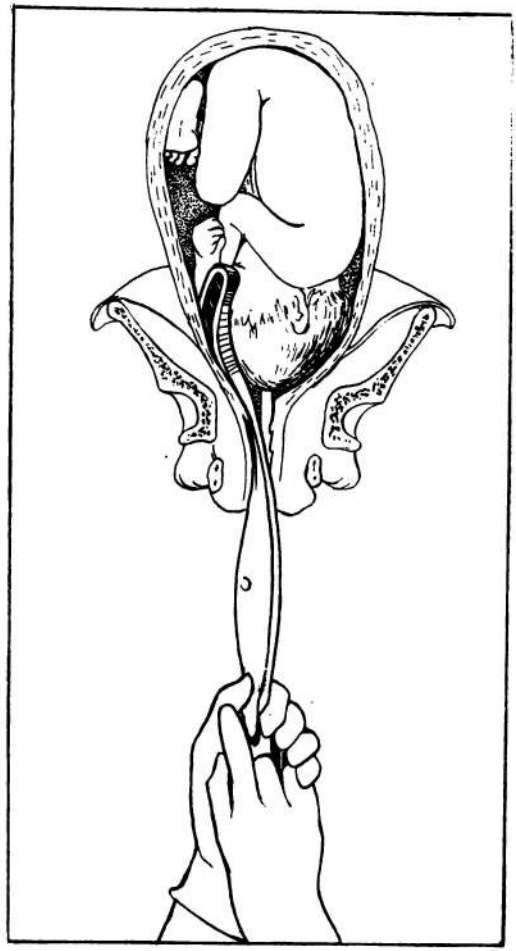

Fig. 342. Extraction of the head using a cranioclast

screw. The head is now extracted through a fully dilated cervix (Fig. 342). If dilation is incomplete and there are indications for rapid completion of labour, the cervix is incised and the foetus then extracted.

Decapitation

Decapitation is performed in neglected transverse presentation. The required tools: decapitation hook (Fig. 343), blunt long-handled scissors, specula, bullet forceps for inspection of the cervix, and tools for repair of the cervical or perineal lacerations, if any.

Technique: if an arm has prolapsed, a loop is attached to it and the assistant pulls it down and toward the pelvic end of the foetus. The operator's hand is introduced into the birth canal and



Fig. 343. Braun's hook

Fig. 344. Decapitation

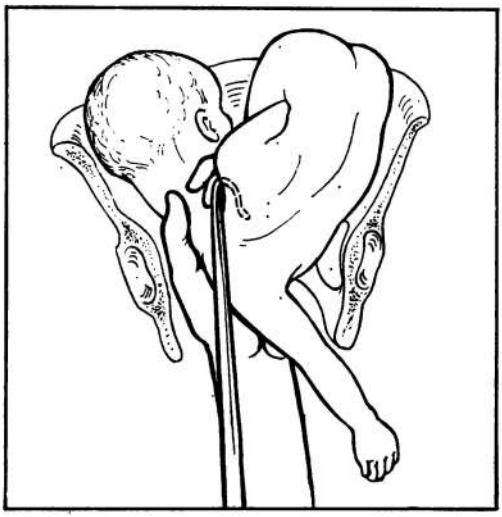

the foetal neck is identified and grasped circularly. The thumb is positioned anteriorly, while the index and the middle fingers posteriorly. The blunt decapitation hook is guided into the uterus by the internal hand to engage the foetal neck (Fig. 344). The handle of the hook is now pulled strongly downward and turned toward the head. The cervical vertebrae break (a specific sound is heard). The hook is then removed and the soft tissues of the neck are cut by a long-handled blunt scissors (under control of the internal hand). The foetal torso can now be removed by the arm. If difficulties are encountered in the passage of the shoulder girdle, the clavicles should be incised. The head is extracted by the hand, for which purpose a finger is inserted into the mouth of the foetus. If it fails, the head should be perforated, emptied and extracted by a cranioclast.

The cervix, the vagina and the perineum should be inspected after the operation.

Cleidotomy

Cleidotomy is the surgical division of the clavicle to facilitate passage of the shoulders through the birth canal. Both clavicles are incised if necessary. The necessity of cleidotomy may arise after decapitation or in difficult labour with a giant foetus.

The operation is performed under control of the hand inserted into the birth canal. The midpoint of the clavicle is located by the index and the middle fingers of the guiding hand along which a long-handled blunt scissors is directed to the clavicle which is incised. After the anterior clavicle has been thus divided, the shoulder girdle decreases by 2.5-3 cm; if both

clavicles are cut, the girdle decreases by 5 or 6 cm.

Evisceration

Evisceration (eventration) is the incision of the abdominal wall or the chest of the foetus and removal of its internal organs. The operation is indicated in neglected transverse presentation when the neck of the foetus is inaccessible for decapitation. (The operation is also performed on monsters.) Full dilation of the cervix is requisite. The abdominal wall of the foetus is incised by a scissors and the foetus is thus disemboweled. The chest may be more accessible. The ribs should then be divided and the internal organs removed; then the foetus is extracted in the folded position. If difficulties are encountered, the vertebral column should be destroyed (spondylotomy).

Spondylotomy

This operation is aimed at destruction of the spinal column. After removal of the internal organs, the spine is divided by a scissors or fractured by a decapitation hook. The soft tissues are then dissected and the upper part of the foetus (with the head) is extracted followed by extraction of the podalic end. The cervix, vagina and the perineum should be inspected thoroughly after the operation.

Postoperative Care

Obstetric operations involve invasion of the uterus with the operator's hand or tools that may carry infection from the vagina. The danger of infection after such operations is much greater than in normal labour. Injured soft tissues of the reproductive tract are another gate through which infection enters the operated woman. Loss of blood, which is often associated with pathological (operative) labour also favours the development of infection. When giving postoperative care to the puerpera, the personnel should remember that the patient may be depressed after the disastrous event (loss of the desired infant through a destructive operation, etc.).

An operated puerpera requires complete rest, and should sleep for at least 8 or 10 hours a day. Trioxazine or bromides are given to non-feeding women. The women whose infants were born dead, should be kept in separate room (separated from nursing mothers).

Asepsis rules should be very strictly followed when the operated woman is washed, catheterized, injected, or dressed. The diet and other postoperative conditions should comply with the character of the operation and the individual features of the patient.

The temperature, pulse, intestinal and urinary functions should be thoroughly observed in operated patients. Their lactating function should also be controlled (correct nursing, removal of excess milk by pumping, adequate care of the breasts). General tonics and antibiotics are often necessary.

When discharged from the hospital, the patient should be given her labour and delivery records (containing information on the complications and operations) which are necessary to obtain a 70-day postpartum leave.

An obstetrician should regularly visit the patient (and her baby) at home.

Subject index

abdomen
  acuminate (pointed) 319
  pendulous 319
abdominal bandage 111
abdominal hysterotomy 389
abnormalities of pelvic soft tissues 292
abnormal labour 301
abortion
  artificial 265, 270, 369
  complete 268
  habitual 265
    prevention of 271
  imminent 267
  incomplete 268
  inevitable 267
  septic 269
  spontaneous 265
  threatened 266
  tubal 277
adnexitis 356
afibrinogenaemia 337
air metabolism 362
amniocentesis 102
amnion 58
amnionic hydrorrhoea 248
amnioscopy 102
amniotic fluid 61
  early escape of 128
anaemia, acute 337
  control of 337
anencephalia 240
anomalies of umbilicus 243
Apgar scoring system 198, 199
appendicitis 258
artificial rupture of foetal membranes 374, 375
Aschheim-Zondek test 91, 246
asphyxia 196
  intrauterine 196
  neonatal 198
  resuscitation of neonate born in 199
asynclitism 93, 309
Bandl's ring 127
Bartholin's glands 10, 11
Biryukov's method 336
blastocyst 58
bleeding in early puerperium 329, 333
  treatment of 334
breast-feeding 191
breast infections, puerperal 361
  prophylaxis of 361
breast milk 175
breast pump 193
breech birth 209
breech presentation 206 (see *presentation*)
  classification of 206
  diagnosis of 206
  manual assistance in 213
  mechanism of labour in 208
Caesarean section 389
cancer of genitalia 263
catheterization of bladder 147, 148
cephalohaematoma 138
cephalopelvic disproportion 327
cervical pregnancy 279
cervix
  rigidity of 293
  rupture of 343
chloasma 80
chorioepithelioma 247
chorion 58, 60
cleft palate 240
cleidotomy 394
clitoris 10
coagulation defects 334
coccyx 39
colostrum 83, 175
conjugate
  diagonal 50
  external 50
  obstetric 41
  true 41
constriction (contraction) ring 127
contraceptives 271
contracted pelvis, see *pelvis*
corpus luteum 32
couveuse 194, 195
craniodermal forceps 373
craniotomy 391
crowning 129
curettage 369
cyclic changes in ovaries and endometrium 35
cystoma of ovaries 263
decapitation 393
decidual cells 58
decidual membranes 59
defects of foetal growth 239
  membranes 245
delivery, predicting time of 103
dermatoses of pregnancy 237
destructive operations on foetus 391
desultory labour 291
diameters
  of foetal skull 73
  pelvic 40, 41
Döderlein's bacilli 15
Douglas' cul-de-sac (pouch) 13, 18, 263
dropsy 230
drug anaesthesia 170
duplex uterus and vagina 260
dystocia 288
eclampsia 233
  prophylaxis of 234
ectopic pregnancy 275
embryo 58
embryoblast 58

encephalocele 240
endometrium
  cyclic changes in 35
engagement of foetal head, straight 310
entanglement of umbilical cord 243
episiotomy 375
eventration 395
evisceration 395
examination of parturient 102
  of pregnant 86
  vaginal, at late pregnancy and in labour 100
exercises in early puerperium 181
exocoelom 58
expulsive stage of labour 129
Exton's test 143
extraction of foetus
  by groin 383
  by leg(s) 382
  by pelvic end 381
fallopian tubes 18, 23, 32
false pelvis 40
female genitalia, anatomy of 9
  innervation of 24
  malformations of 259
female pelvis 37 (see also *pelvis*)
fertilization 54
fistulae 349
foetal growth defects 239
foetal intrauterine death 242
  prevention of 243
foetal membranes 59
  defects of 237
foetus
  assessing condition of 107
  diseases of 237, 245
  excretory function of 69
  extraction of 381, 383
  giant 241
  mummification of 243
  spontaneous version of 296
fontanelle
  frontal 73
  occipital 73
footling presentation 212 (see *presentation*)
  conduct of labour in 212
forceps delivery 284
forewaters 128
frog test 91
general (inhaled) anaesthesia in obstetric operations 368
genitalia, female
  anatomy of 9
Genter's method 335
gestational age, determination of 103
giant foetus 241
haemolytic diseases of foetus 242
haemorrhage
  late postpartum 337
hare lip 240
hydatidiform mole 245
hydrocephalus 239
hygiene of menses 35
hymen 11
hypersalivation in pregnancy 229
hypoxia 68
hysterostomatomy 374
hysterotomy
  abdominal 389
  vaginal 389
ilium 37
imperforate anus 241
implantation 56
injuries in labour and delivery 339
  of neonate 202
innervation of internal female genitalia 24
innominate bone 37
internal female genitalia 12
involution of genitalia 173
ischium 38
jaundice of pregnancy 237
joints
  sacrococcygeal 39
  sacroiliac 39
Kocher's forceps 156
Küstner-Chukalov sign 160
labia majora 10
  minora 10
labour
  abnormal 301
  causes of 122
  conduct of 141
  desultory 291
  duration of 140
  expulsive stage of 129, 148
  forces of 124
  in flat rachitic pelvis 324
  in folded position 296
  injuries in 339
  pain relief in 167
  placental stage of 138
  precursors of 123
  premature 265, 273
  stages of 124
Langhans' cells 64
late postpartum haemorrhage 337
ligaments 21
lochia 174, 355
low forceps 386
low transverse position of head 311
lymphatic system of reproductive organs 25
maceration of dead foetus 243
malformations of genitalia 259
mammary glands 26
manual assistance in breech presentation 213, 217
manual separation and removal of placenta 331

mask of pregnancy 80
Mauriceau-Levret manoeuvre 214, 216
measuring intrauterine foetus 106
mechanism of labour in occiput anterior presentation 132
  in persistent occiput posterior presentation 135
meconium 68, 70
membranes
  delayed rupture of 249
  premature and early rupture of 249
menses, hygiene of 35
menstrual cycle 28
method
  Abuladze 160, 161
  Credé-Lazarevich 161
  Genter 161, 162, 335
  Piskacek 335
  Schultze 189
metreurynter 283, 372
metreurysis 283, 372
metritis 355
metroendometritis 354
Michaelis' rhomboid 48, 146, 169, 171, 319
mons pubis 9
Montgomery's glands 26, 83
multiple birth, conduct of 224
mummification of foetus 243
Museux' forceps 369, 370
Naegele's obliquity 309
Naegele's pelvis 317
neonate
  breast-feeding of 191
  care of 186, 188
  infectious diseases of 203
  injuries in labour and delivery 202
  measuring length of 158
  organs of senses of 189
  skin of 188
  swaddling of 189
  weighing of 158
nephropathy of pregnancy 231
new growths of genitalia 263
obliquity
  Litzmann's 309
  Naegele's 309
obstetric forceps 384
obstetrician hand 378
obstetric operations 364
oligohydramnios 63, 248
operations on uterus 369
Otto's leg holder 366, 368
ovarian cycle 29
ovaries 19
  cyclic changes in 35
  cystoma of 264
ovulation 31
pain relief in labour 167
  by psychoprophylaxis 168
  in obstetric operations 368
paracervical block anaesthesia 368
parametritis 355
parametrium 22
pelvic axis 42
pelvic contracture, degrees of 314
pelvic diameters 42
pelvic floor 46
pelvic joints 39
pelvic muscles 45
pelvic planes 40, 42
pelvic soft tissues, abnormalities of 292
pelvis
  beaked (rostrate) 317
  contracted 314
    aetiology of 314
    classification of 316, 318
    diagnosis of 318
    mechanism of labour in 323, 325, 326
  false 40
  female 37
  flat rachitic 315
  generally contracted flat 316
  justo minor 315, 325
  male and female, differences in 45
  mensuration of 48
  Naegele's 317
pelvis
  osteomalacic 317
  Otto's 317
  platypellic 325
  spondylolisthetic 317
  true 40
perineotomy 373
perineum 10
  defects of 293
  lacerations of 339
    classification of 339
    repair of 340
periods of female life 27
peritonitis 358
Piskacek test 335
placenta 63
  accreta 330
  adherent 330
  anomalies of 251
  delivery of by Abuladze method 160, 161
    Credé-Lazarevich method 161
    Genter method 161
  manual separation of 331
  premature separation of 285
placenta praevia 279
  aetiology of 280
  complete (central) 280
  diagnosis of 282
  lateral 279
  marginal 279
  partial 279
  treatment of 282

placental infarcts 251
polydactylia 241
polyhydramnios 247
precipitate labour 291
pre-eclampsia 232
pregnancy
  abdominal 275
  breasts in 110
  care of skin in 110
  changes during, in
    blood 78
    body weight 78
    breasts 83
    cardiovascular system 78
    endocrine system 76
    external genitalia 83
    gastrointestinal tract 79
    metabolism 77
    nervous system 75
    respiratory system 79
    skin 79
    urinary system 79
  clothing in 111
  dermatoses of 237
  diagnosis of 84
  differential diagnosis of 87
  early toxaemia of 227
pregnancy
  ectopic 275
  examination of internal organs in 87
  extrauterine 275
  hypersalivation in 229
  jaundice of 237
  monozygotic 219
  multiple 219
    course of 220
    diagnosis of 223
    labour in 223
  nutrition and hygiene in 109, 112
  toxaemia, rare forms of 237
pregnancy and labour in patients with
  appendicitis 258
  cardiovascular diseases 256
  diabetes mellitus 259
  diseases of blood 257
  endocrine diseases 259
  gonorrhoea 255
  hypertension 257
  infectious diseases 253
  influenza 253
  malaria 254
  malformations of genitalia 259
  medical diseases 253
  nervous disorders 258
  syphilis 254
  toxoplasmosis 255
  tuberculosis 253
  urinary diseases 257
premature labour 273
  causes of 273
  prophylaxis and treatment of 273
premature neonate, care of 194
presentation 92, 95
  breech 93, 206
    classification of 206
    diagnosis of 206
    complete 207
    external version in 377
    footling, double 207
      single 208
    frank 207
    incomplete 95
    mechanism of labour in 208
    pregnancy in 208
  brow 304
    diagnosis of 304
    mechanism of labour in 304
    skull molding in 303, 305
  cephalic 94
  classification of 95
  deflexed 95
  face (mentum) 306
    mechanism of labour in 307
  longitudinal 92, 94
presentation
  oblique 294
    labour in 295
      conduct of 297
  transverse 92, 95, 294
    diagnosis of 294
    labour in 295
      conduct of 297
    persistent 296
  vertex 95
prolapse of foetal extremities and umbilical cord 294, 298, 299
prophylaxis of
  gonoblennorrhoea 156
  ophthalmoblennorrhoea 156
psychoprophylaxis of labour pain 167
pubis 38
pudendal block anaesthesia 368
puerperal psychosis 363
puerperal shock 362
puerperium 173
  conduct of 176
  diseases of 352, 362
    classification of 353
    prophylaxis of 116
  nutrition in 179
pyoderma of neonates 203
rare forms of pregnancy toxaemia 237
reproductive organs, innervation of 24
resuscitation in asphyxia 199
  by Silvester method 202
  by Sokolov method 201
retention of placental parts 330
rhesus factor 242
incompatibility 242
Rogovin's staples 157

rupture of tube, 276, 277
  Shchetkin-Blumberg sign of 277
sacrococcygeal joint 39
sacroiliac joint 39
sacrum 38
salpingo-oophoritis 356
Schultze's method of placenta separation 189
separation of placenta by Duncan's method 140
separation of symphysis 350
sepsis
  during labour, prevention of 116
generalized 359
  of newborn 204
  prophylaxis of 360
  puerperal 354
septicopyaemia 359
signs of past delivery 107
signs of placental separation 159
  Ahlfeld's 160
  Schroeder's 159
signs of pregnancy
  Genter's 90
  Gorvits-Hegar 90
  Gubarev-Gaus 90
  Piskacek 90
  Snegirev 90
Simonart's threads 248
Skene's ducts 11
skull bones 73
skull diameters 73
skull molding during labour 72, 137
skull sutures 72, 73
spermatogenesis 54
spina bifida 240
spondylotomy 395
spontaneous version of foetus 296
straight engagement of foetal head 310
striae of pregnancy 80, 107
symphysis pubis 39
  separation of 350
synclitism 93
  definition of 94
test
  Aschheim-Zondek 246
  Exton 143
  frog 91
  Wassermann 255
thrombophlebitis 357
thrombosis of femoral veins 357
transverse presentation
  external version in 377
trophoblast 58
true pelvis 40
twins
  conjoined 241
  dizygotic 219
  interlocked 224
  monozygotic 219
umbilical cord, cutting of 157
  entanglement of 243
  hernia of 240
umbilicus 64
  anomalies of 243
  knots of 244, 245
  long 244
urethra 11
urogenital diaphragm 47
uterine cervix 16
uterine cycle 33
  phases of 34
uterine inertia 288
  secondary 290
    treatment of 290
uterine isthmus 15
uterine mucosa 17
uterus 115
  abnormal position of 262
  arcuatus 260
  bicornis 260
  duplex 260
  inversion of 349
  levels in pregnancy 105
  unicornis 261
  rupture of 345
vacuum extraction 390
vagina 12
  defects of 293
  duplex 260
  haematoma of 343
  lacerations of 343
vaginal examination
  at late pregnancy and during labour 100
  bimanual 89
  of parturient 147
  of pregnant 88
vaginal hysterotomy 389
Vasten's sign 327
Verbov's bandage 291
version
  external 376
  Hicks' 284
  in transverse presentations 377
  obstetric 375
  podalic 284
vertex presentation 301 (see *presentation*)
  conduct of labour in 304
  mechanism of labour in 304
vestibule 11
vomiting of pregnancy 228
  incoercible 228
Voorhees' bag 283
vulva, haematoma of 343
Walcher position 43
Wassermann's test 255
weighing neonate 158
Wharton's jelly 65
yolk sac 58